

## C-shaped canal configuration in lower molar - Case report

Canal radicular com configuração em C em molar inferior – Relato de caso

Lauren Grandí dos SANTOS<sup>1</sup>, Amanda Nunes GALLAS<sup>1</sup>, Josué MARTOS<sup>1</sup>, Luiz Fernando Machado SILVEIRA<sup>1</sup>

1 – Department of Semiology and Clinics – School of Dentistry – Federal University of Pelotas (UFPel) – RS – Brazil.

### ABSTRACT

C-shape configuration in molars is an anatomical variation that difficults diagnosis and treatment. The aim of this study was to report a case of C-shape endodontic configuration in a mandibular second molar. The radiographic examination of one patient revealed the extent of caries in the mesial aspect of mandibular second molar, without the presence of periapical lesion and was clinically noted the C-shape configuration of the root canal, extending from the mesiobuccal to the distal canal. Endodontic therapy was performed and after the root canal filling, the tooth was restored. We conclude that after 12 months of clinical and radiographic follow-up, satisfactory outcome of the treatment was observed.

### KEYWORDS

Dental Pulp Cavity, anatomy; Molar; Endodontics; Root canal therapy.

### RESUMO

A configuração de canais em formato de C em molares é uma variação anatômica que dificulta o diagnóstico e tratamento. O objetivo deste estudo foi relatar um caso de configuração de canal em C no segundo molar inferior. O exame radiográfico do paciente revelou uma cárie extensa na porção mesial do segundo molar inferior, sem a presença de lesão periapical e foi clinicamente observada a configuração em C do canal radicular, que se estendeu desde o canal mesiovestibular até o canal distal. A terapia endodôntica foi realizada e após a obturação dos canais, o dente foi restaurado. Concluiu-se que após 12 meses de acompanhamento clínico e radiográfico, verificou-se que a terapia teve um resultado satisfatório.

### PALAVRAS-CHAVE

Cavidade da polpa dental, anatomia; Molar; Endodontia; Tratamento do canal radicular.

### INTRODUCTION

The success of endodontic treatment is associated to the knowledge of dental anatomy, both internal and external. In endodontic practice, we find teeth showing atypical anatomical formations, additional roots and/or extra root canals. These anatomical variations, when not detected early, can make treatment difficult or even cause failures [1,2].

The C-shape canal is named for the cross-sectional morphology of its root and root canal, resembling the letter C [3-5]. Typically the pulp chamber of the C-shaped canal, instead of having

discrete orifices, has single ribbon-shaped orifice with an arc angle of approximately one hundred and eighty degrees and the pulp chamber floor presents deeper and atypical aspect [6,7]. This anatomic configuration is not as frequent and many reports describe the variation among different populations with prevalence between 2.7% and 31.5% [4,8]. These studies indicate that the occurrence of the C-shape is more common in Asian populations than others [5,8,9].

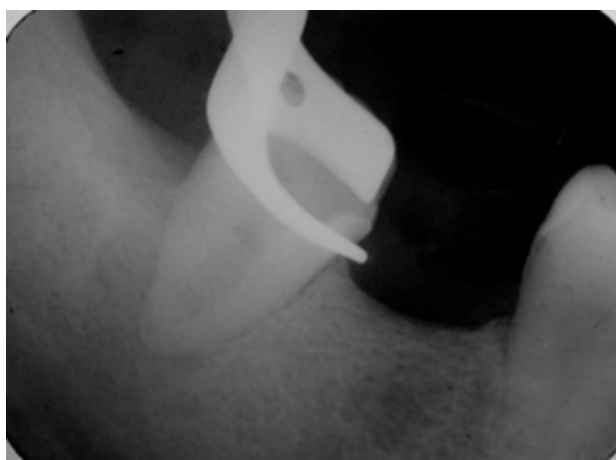Regarding the endodontic diagnosis, there is a consensus that a C-shape canal presents like main characteristics fused roots

and a longitudinal stripe in the lingual and buccal aspects [4,7,9]. The use of periapical radiographs to diagnose and to determine the C-shape root canal morphology may not show the expected results. In some cases, it may be difficult to distinguish between a C-shape root canal with one or three single root canals that fused in the apical region; condition confirmed, when necessary, by accessing the pulp chamber [10-12].

The aim of this manuscript was to report a clinical case related to an endodontic treatment of a molar tooth presenting C-shape root canal.

## CASE REPORT

A 40-year-old man was referred at the clinics of the School of Dentistry with sensibility on mastication in the mandibular second molar (47). The intraoral examination showed that tooth had carious cavity and the cold thermal pulp testing detected endodontic alteration, represented by the absence of pulp vitality. Radiographic examination revealed the extent of carious lesions by the mesial aspect of the second molar, where one can also observe the root of this condition without the presence of periapical lesion, but with slight increase of the apical periodontal space (Figure 1).



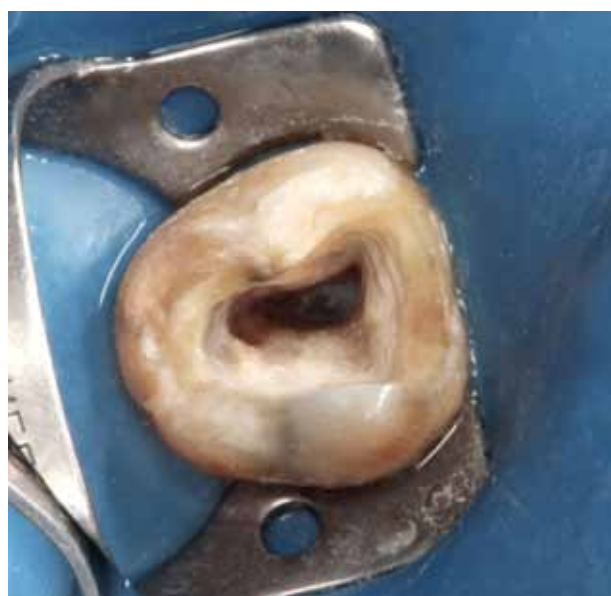**Figure 1** - Initial radiographic appearance of the mandibular second molar.

Initiated the endodontic therapy, while accessing the endodontic cavity it was observed a fusion of the entries of the channels in a single orifice, with shaped of letter C, extending from mesiobuccal to the distal canal, with closing of C in a buccal direction (Figure 2).

The endodontic treatment was performed in three sessions. First being made the opening and disinfection of the root canal, chemomechanical preparation and insertion of intracanal medication with calcium hydroxide base. Second session after 15 days, root canal filling and temporary sealing of the cavity with glass ionomer cement were performed, and the third session the final restoration was carried out with lightcured composite resin.

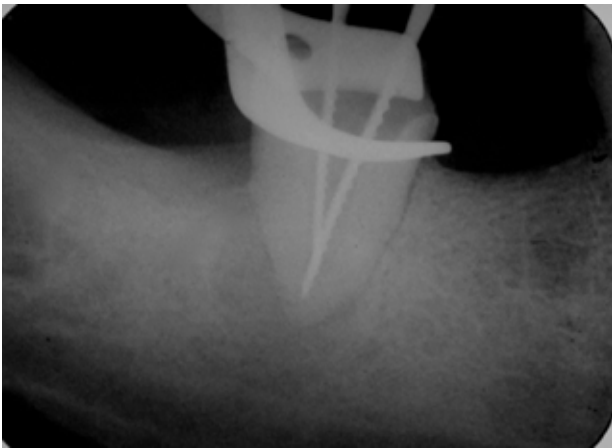
The canal started to be prepared by the crown-down technique, beginning with larger diameters files until the anatomical size at the apex. Then, using the Ingle radiographic method the odontometry was performed.

Root canal length was measured with the placement of a two K-file (#80 and #60) compatible with the apical diameter of the

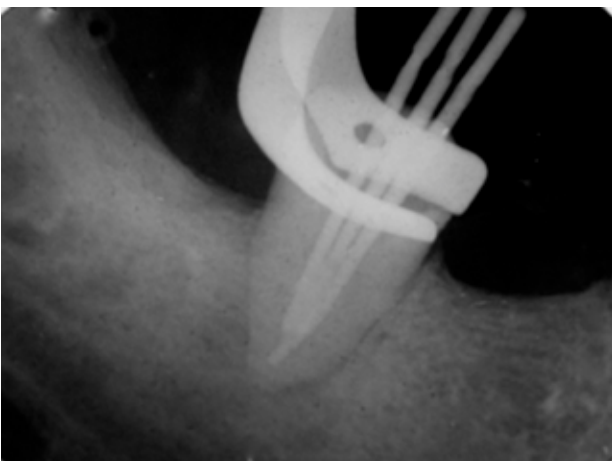


**Figure 2** - Initial aspect of the C-shape canal.

canal (Figure 3), and after that, the canal was instrumented with the K-file #80 (Dentsply-Maillefer, Ballaigues, Switzerland), by making movements of filling around the walls of the root canal, with intermittent irrigation by use of approximately 15 ml of sodium hypochlorite 2.5%. After use of the file #80, gates-glidden drills (#4 and #5) were used, providing taper



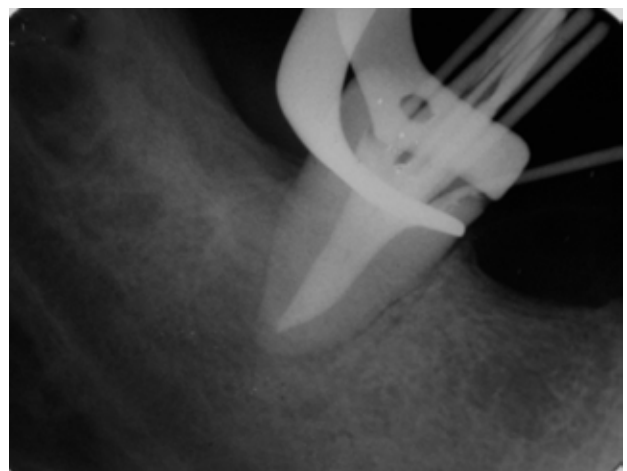
**Figure 3** - Establishment of limits for the treatment.



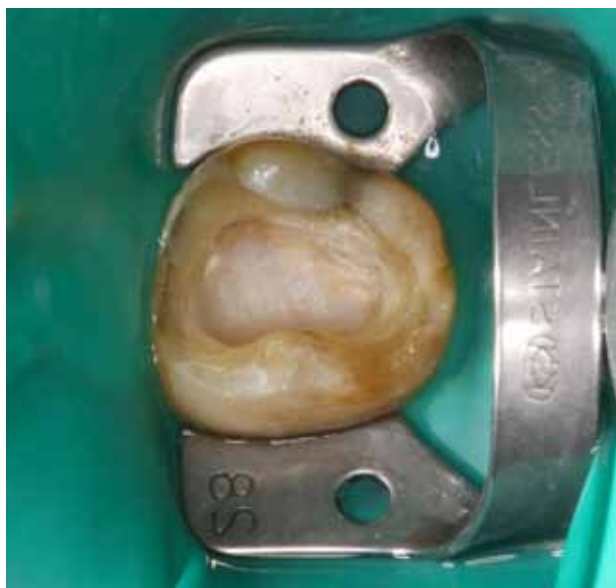**Figure 4** - Root canal filling.

on the middle and cervical thirds and calcium hydroxide paste was inserted in the root canal and left for 15 days.

In the second session, after thorough preparation, it was removed the calcium hydroxide and applied a demineralizing solution (17% EDTA, Biodinâmica, Ibitinga, PR, Brazil), which was left inside the root canal for 2 min and subsequently removed with the use of sodium hypochlorite irrigation. Drying of the root canal was made with absorbent paper points. Then, the three master cones were adapted (Dentsply Rio de Janeiro, RJ, Brazil) and the root canal obturation was carried out by lateral condensation and gutta-percha thermoplastification technique using the McSpadden compactor with root canal sealer Endofill (Dentsply, Rio de Janeiro, RJ, Brazil) (Figures 4 and 5). After root canal obturation, the tooth was sealed with resin-modified glass ionomer cement (Vitremer, 3M Dental Products Division, St. Paul, MN, USA) (Figure 6).



**Figure 5** - Radiographic aspect of the root canal filling.



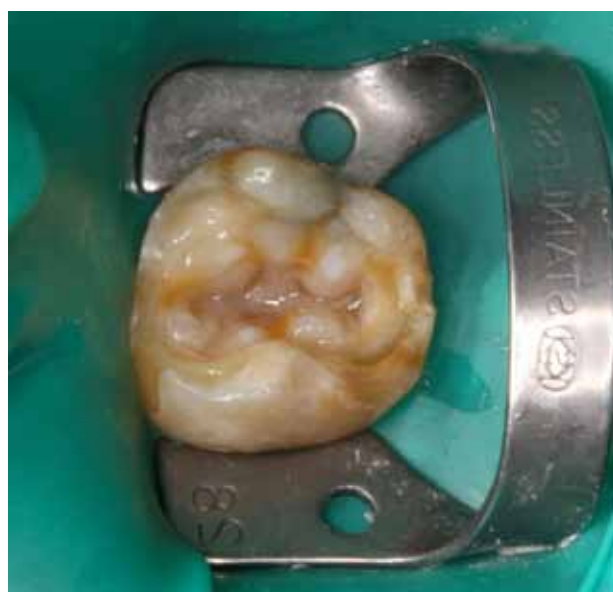**Figure 6** - Modified glass-ionomer cement.

The final restoration of the lower molar was initiated by refinement of cavity preparation by hand and rotary instruments. Cuspal protection was not the option at this time due to sufficient amount of remaining tooth structure, and no intraradicular retention device was employed, due to among other reasons the own conformation of the pulp chamber. The use of a resin-modified glass ionomer cement associated with a photopolymerized composite resin was opted (Figure 7).

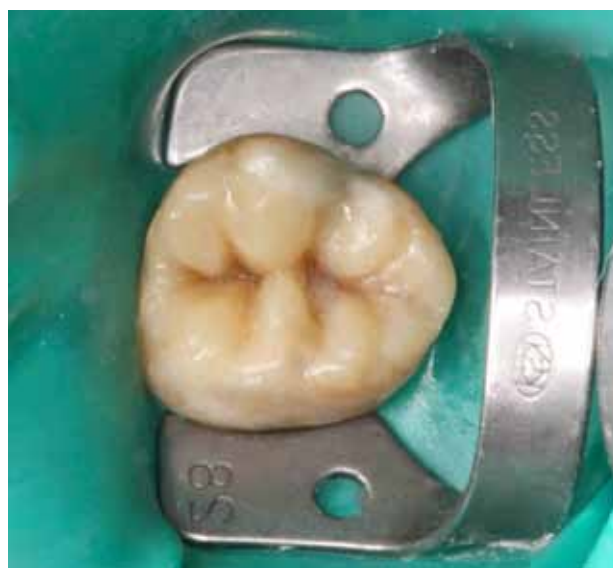The operative field was isolated with rubber dam (Figure 7). Briefly, the tooth cavity were acid etched for 30 s with 35% phosphoric acid gel, rinsed for 30 s and dried with air spray. Then, a conventional two-bottle adhesive system (Scotchbond Multi-Purpose Plus, 3M ESPE, St. Paul, MN, USA) was applied on the enamel and after light-cured for 40 s buccally and 40 s lingually using halogen light-curing equipment, at an intensity of 1400 mW/cm<sup>2</sup> (Radii LED Curing Light, SDI, Australia).

A thin layer of composite resin (A3 Amelogen Plus, Ultradent Products, South Jordan, UT, USA) was used for reproducing the dentin and after curing was done for 40 s, less saturated and high translucency composite (A2 Amelogen Plus, Ultradent Products,

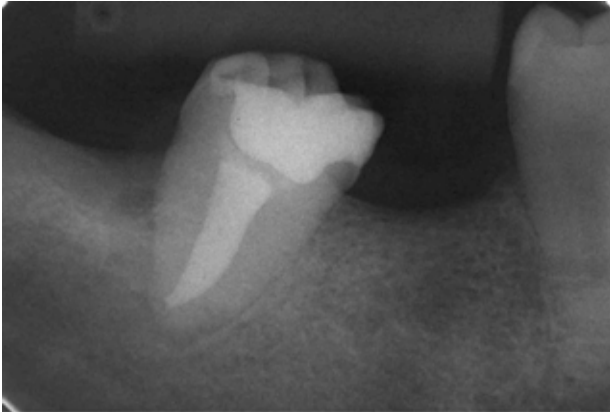
South Jordan, UT, USA) was inserted and condensed defining the anatomical shape of the second molar (Figure 8). Excess composite resin was removed, checking the occlusion and final polishing was performed using a high-luster polishing paste (Opal L, Renfert GmbH, Hilzingen, Germany), goat-hair brushes and cotton buffs (Renfert GmbH, Hilzingen, Germany) on the restored surface (Figure 9).



**Figure 7** - Composite resin restoration with use of dental pigments.



**Figure 8** - Clinical appearance of the composite resin restoration.



**Figure 9** - Final radiographic aspect.

Twelve months after the conclusion of the treatment, the clinical and radiographic (Figure 6) follow-up revealed that endodontic treatment and direct restoration have a suitable clinical characteristic.

## DISCUSSION

The recognition of a C-shaped root canal configuration before endodontic treatment can certainly facilitate the endodontic biomechanics. The complexity of the C-shape canal requires proper cleaning procedures, and an accurate instrumentation technique [3,13].

Tooth with C-shaped canal that requires root canal treatment represents a challenge for the clinician. The procedures are difficult for their preparation, which may lead to failure, because the presence of high incidence of transverse anastomoses, lateral canals and apical deltas, hampering adequate cleaning of the root canal system [5,7].

Anatomical variations of the C-shape canal can be observed within the same root at different levels. If one canal is present, it is described as the true C-shape canal [4]. However, numerous morphologies are clinically important when one considers the debridement, the endodontic filling and the final restoration. The classification of the tooth treated in this manuscript, according some authors is a continuous C-shape canal, without any separation or division [10,14].

Access to the pulp chamber is still considered the key to endodontic success once one gets direct access to canals for an efficient manual exploration. Debridement is one of the most important phases of endodontic therapy, because complete sanification of the root canal should occur [1]. With this thought, new alternative techniques for cleaning the canal, such as the use of sonic and ultrasonic instrumentation, which could increase the removal of debris from inaccessible areas, and thermoplastic root canal filling techniques have made treatment more predictable [13].

The irrigating solution used in these cases of complicated anatomy has an extremely important role. Sodium hypochlorite due to its antibacterial properties and dissolving organic matter is the agent of choice [15]. The root filling employed was the lateral condensation technique, although being challenging due to the amplitude of the apical foramen. Two major cones have been adapted at the distal zone and the other at the mesial zone of the root canal, surrounding the apex forming an apical stop for endodontic filling. Radiographic examination of the C-shape canal presents some common characteristics, such as fusion or root proximity and a blurred image at the middle third, which can be seen in the reported case. Other radiographic characteristics are the presence of instruments converging to the apex [16]. The auxiliary methods for endodontic diagnosis used more effectively in descending order are computed tomography, indirect digital radiography and conventional x-ray [10,11]. Diagnostic information can directly influence clinical decisions and at this point of view the cone beam computed tomography provides the most accurate information on the C-shape anatomy [17].

Professionals, experts or not, should be alert to the fact that lower second molars more often present root canal in "C" form and the difficulties inherent in treating these cases, and also to anticipate this possible occurrence

and to take precautions in case of the condition is confirmed.

The possibility of C-shaped canal has to be considered during the clinical and radiographic examination and, the earlier the recognition of this anatomic configuration, the better the procedures for cleaning, shaping and obturation of the canal system.

## CONCLUSION

This clinical case allows the conclusion that C-shape root canal, even though it presents difficulties in its endodontic treatment, it does not preclude the full rehabilitation since we established early diagnosis of this anatomic configuration. We conclude that after 12 months of clinical and radiographic follow-up, it was found that treatment had a satisfactory outcome.

## REFERENCES

1. Silveira LFM, Luiz JS, Klein I, Martos J. Segundo molar inferior com configuração do canal em C - Caso clínico. *Rev Clin Pesq Odontol.* 2010;6(2):169-74.
2. Benenati FW. Mandibular second molar with C-shaped canal morphology and five canals: report of a case. *Gen Dent.* 2004;52(4):253-4.
3. Cooke HG, Cox FL. C-shape canal configurations in mandibular molars. *J Am Dent Assoc.* 1979;99(5):836-9.
4. Yang ZP, Yang SF, Lin YC. C-shaped root canals in mandibular second molars in a Chinese population. *Endod Dent Traumatol.* 1988;4(4):160-3.
5. Cleghom BM, Cristie WH, Don CC. Root and root canal morphology of the human permanent maxillary first molar: a literature review. *J Endod.* 2006;32(9):813-21.
6. Min Y, Fan B, Cheung GS, Gutmann JL, Fan M. C-shaped canal system in mandibular second molars Part III: The morphology of the pulp chamber floor. *J Endod.* 2006;32(12):1155-9.
7. Cheung GSP, Yang J, Fan B. Morphometric study of the apical anatomy C-shape root canal systems. *Int Endod J.* 2007;40(4):239-46.
8. Haddad GY, Nehme WB, Ounsi HF. Diagnosis, classification, and frequency of C- Shaped canals in mandibular second molars of the Lebanese population. *J Endod.* 1999;25(4):268-71.
9. Manning SA. Root Canal anatomy of mandibular second molars. Part II. C-shape canals. *Int Endod J.* 1990;23(1):40-5.
10. Fan B, Cheung GS, Fan M, Gutmann JL, Bian Z. C-shape canal system in mandibular second molars: Part I – Anatomical features. *J Endod.* 2004;30(12):899-903.
11. Fan B, Cheung GS, Fan M, Gutmann JL, Fan W. C-shape canal system in mandibular second molars: Part II- Radiographic features. *J Endod.* 2004;30(12):904-8.
12. Paksefat S, Rahimi S. Root canal treatment of a two-rooted C-shaped maxillary first molar: a case report. *Iran Endod J.* 2014;9(4):301-3.
13. Vertucci FJ. Root canal morphology and its relationship to endodontic procedures. *Endod Topics.* 2005;10(1):3-29.
14. Melton DC, Krell KV, Fuller MW. Anatomical and histological features of C-shape canals in mandibular second molars. *J Endod.* 1991;17(8):384-8.
15. Basrani B, Haapasalo M. Update on endodontic irrigating solutions. *Endod Topics.* 2012;27(1):74-102.
16. Al Fouzan KS. C-Shaped root canals in mandibular second molars in a Saudi Arabian population. *Int Endod J.* 2002;35(6):499-504.
17. Shokri A, Poorolajal J, Faramarzi F. Comparison of the accuracy of cone-beam computed tomography, photostimulable phosphor imaging plate, charge coupled device, and conventional intraoral radiography in the diagnosis of internal root resorption: an in vitro study. *Braz Dent Sci.* 2014;17(1):72-80.

### Prof. Dr. Josué Martos (Corresponding address)

Department of Semiology and Clinics  
School of Dentistry, Federal University of Pelotas (Brazil)  
Gonçalves Chaves street, 457 - Pelotas-RS, Brazil.  
96015-560.  
Email: josue.sul@terra.com.br

Date submitted: 2014 Jun 29

Accept submission: 2015 Feb 20