



Orthodontic extrusion and implant site development: two case reports

Extrusão ortodôntica pré-implante: relato de dois casos clínicos

Maria Ângela Lacerda Rangel ESPER¹, Ana Carolina Rodrigues Danzi SALVIA¹, Maria Tereza Pedrosa de ALBUQUERQUE¹, Nelson Luiz de MACEDO²

1 – Department of Restorative Dentistry – School of Dentistry – Institute of Science and Technology – UNESP – Univ Estadual Paulista – São José dos Campos – SP – Brazil.

2 – Department of Diagnosis and Surgery – School of Dentistry – Institute of Science and Technology – UNESP – Univ Estadual Paulista – São José dos Campos – SP – Brazil.

ABSTRACT

The aim of this study was to report two cases of orthodontic extrusion performed prior to dental implant placement. The first one reports the case of a 57 year-old-female who presented internal root resorption in the left central incisor, and orthodontic extrusion of this element was indicated. The treatment lasted 24 weeks. At the end of this period, the dental implant was placed. The second clinical event refers to a patient of 66 years of age who had vertical fracture in the left central incisor. In this case, the orthodontic extrusion was conducted in 12 weeks. At the end of this period, the dental implant was placed and also the temporary crown, but without occlusal contact. Both cases reported consisted of the involvement of the left central incisor in the aesthetic area and low bone density. The cases reported demonstrated that orthodontic extrusion is a viable alternative to the aesthetic and functional reconstruction with prosthesis over dental implants.

KEYWORDS

Dental Implantation; Forced eruption; Orthodontic Extrusion; Tooth resorption; Tooth fractures.

RESUMO

A extrusão ortodôntica é um procedimento clínico utilizado no decorrer dos anos com a finalidade, dentre outras, de preservação e ganho de tecido ósseo para permitir a restauração estética e funcional. Assim, este trabalho teve por objetivo relatar dois casos de extrusão ortodôntica realizada previamente à colocação do implante dentário. O primeiro deles relata o caso de uma paciente de 57 anos de idade que apresentou reabsorção interna no incisivo central esquerdo sendo indicada a sua extrusão ortodôntica. O tratamento durou 24 semanas. Ao final deste período foi colocado o implante no local. O segundo caso clínico refere-se a um paciente de 66 anos de idade que apresentou fratura vertical no incisivo central esquerdo. Optou-se por realizar extrusão ortodôntica, por um período de 12 semanas. Finalizado este período, foi realizada a colocação de implante e provisório sem contato oclusal. Observou-se nestes relatos que ambos os casos apresentados consistiram no comprometimento do incisivo central esquerdo, em área estética e de pouca densidade óssea. Esses dois casos demonstraram a extrusão ortodôntica como uma alternativa viável para a reconstrução estética e funcional com prótese sobre implante.

PALAVRAS-CHAVE

Implante dentário; Erupção forçada; Extrusão ortodôntica; Fraturas dos dentes; Reabsorção de dente.

BRIEF LITERATURE REVIEW

Orthodontic extrusion, also referred to as forced eruption is indicated in cases in which there is no possibility to maintain the tooth in a functional way in the oral cavity [1]. It consists of a non-invasive and non-surgical technique, whereby the volume of residual bone is increased by providing an ideal environment for the future placement of a dental implant [2]. Such procedure has been especially employed for the treatment of dental caries, diagonal or horizontal fractures, perforations and internal or external root resorption, which are located in sub-gingival or infra-bone areas [3-7]. In cases of vertical tooth fracture, ankylosis, hypercementosis or proximity between the roots (molar), tooth extrusion is contraindicated, thus tooth extraction is indicated [3].

The forced eruption of a tooth provides not only the increase in the dimensions of the alveolar bone, but also the movement of the free gingiva and interdental papilla towards the dental crown, keeping constant the position of the mucogingival line [1,5]. It can improve aesthetics, especially in the anterior maxilla. One of the most challenging procedures in Implantology is the replacement of a maxillary central incisor [7,8], since the amount of bone available, the type of soft tissue, the correct positioning of the implant and provisional restoration, the design and material of the implant, and the final restoration can affect its clinical success [4,9].

Patients who have teeth that require replacement due to periodontal disease, usually have bone defect and, if the problem is not treated, it may result in catastrophic aesthetic problems. Therefore, in order to obtain satisfactory results, it is essential the presence of adequate alveolar bone at the implant site, because the gingival contour follows the alignment of the alveolar bone crest [5,10-12]. There are also many studies that recommend orthodontic extrusion as a viable treatment

solution which results in significant increase of alveolar bone and soft tissue prior to dental implant placement [2-4,12-14]. Therefore, the aim of the present study is to report two cases in which the orthodontic extrusion was performed in anterior teeth in order to rehabilitate patients by the placement of dental implants.

DESCRIPTION OF CASES

To perform this study, all patients provided their consent for their voluntary participation. The copyright releases are archived with the authors.

Clinical report 1

A female patient, 57 years old, came to a private dental office to initiate orthodontic retreatment. After a detailed interview and extra and intraoral clinical examination, it was confirmed the presence of Angle Class III surgical (Figure 1A), in addition to the absence of teeth 26, 27, and 46. Evaluating the radiograph, it was observed that the tooth 21 had had endodontic treatment, internal root resorption of the middle-cervical third, and a root shortening of approximately one third compared to the tooth 11 (Figure 1B). After a detailed analysis performed by an implantodontist and a periodontist, orthodontic extrusion of tooth 21 was indicated in order to promote its extraction as well as to promote the leveling of the gingiva and formation of healthy bone tissue, both in height and in width at the dental implant region. In order to solve the absence of teeth 26, 27 and 46, after the extrusion of the tooth 21 and placement of dental implant, the patient was referred to another dentist for further treatment.

Soon after the initial orthodontic treatment, the patient had been instructed not to remove the lower fixed retainer because of generalised diastema prior to the orthodontic correction. However, the retainer was removed by another dentist, which led to opening of the spaces between the lower teeth as well as top-to-top relationship of the anterior teeth. Therefore, the treatment plan for solving the case consisted

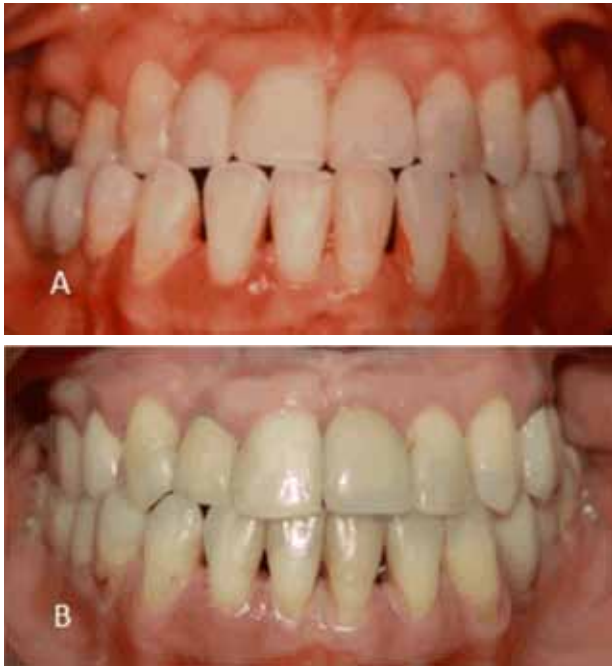

Figure 1 - Case 1: A) Initial photo of the patient. B) Final photo of the patient with implant and prosthesis on tooth 21.

of orthodontic therapy involving Class III dental compensation as the patient refused to undergo orthognathic surgery for dental and osseous correction. Orthodontic extrusion of tooth 21 was also performed prior to its extraction, and followed by placement of implant at the same region and other sites.

Firstly, a full fixed orthodontic appliance (upper and lower) was installed for orthodontic correction with dental compensation. For extrusion of tooth 21, activations were made every 3 weeks during 24 weeks, totalising 13 activations. During this period, incisal and lingual adjustments of tooth 21 were performed to avoid premature contact. At the end of the extrusion procedure, tooth 21 was extracted and a temporary tooth was attached to the orthodontic arch in order to preserve both space and aesthetics (Figure 2A). Six months after extraction of the tooth, a surgical guide was prepared to plan the implant placement. The implant had been initially planned with immediate-load prosthesis, but the practitioner opted to perform only the placement of the implant and wait 6 months before insertion of

the prosthetic portion, and during this 6-month period a temporary prosthesis was placed (Figure 2B and 2C).

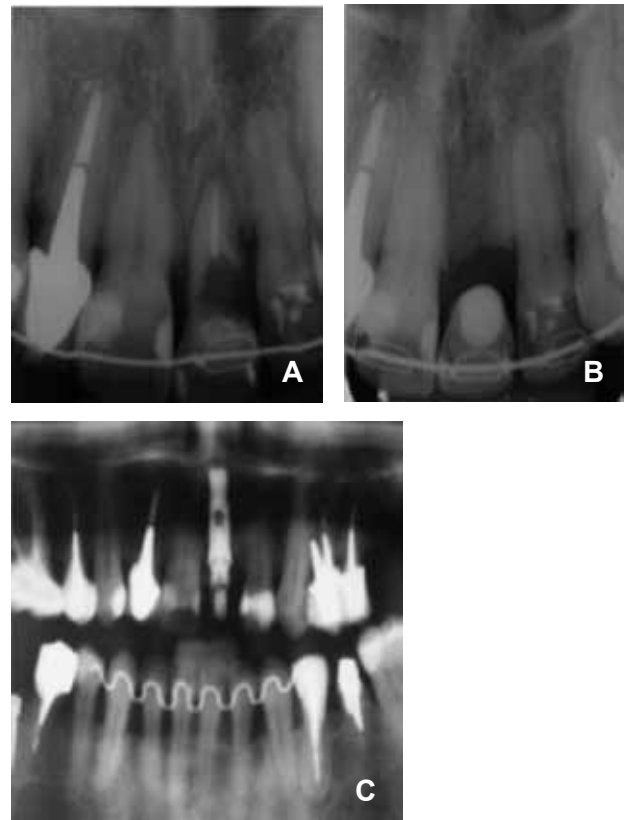

Figure 2 - Case 1: A) Initial periapical radiograph showing presence of internal resorption. B) Retention with temporary fixed appliance. C) Panoramic radiograph with implant on tooth 21.

Clinical report 2

A female patient aged 66 years old was referred to a private dental office for orthodontic extrusion of tooth 21 before rehabilitation with osseous-integrated implant because of a root fracture located 3 mm below the free marginal gingiva and due to the short root length, thus impeding a fixed prosthesis to be made on the root (Figure 3A). The tooth had been endodontically treated, with metallic intraradicular retainer and full ceramic crown. For extrusion of the tooth 21, an upper partially-fixed orthodontic appliance was installed and then activated every 3 weeks during 12 weeks, totalising 7 activations (Figure 3B). After 16

weeks, tooth 21 was extracted and a dental implant was placed and also the temporary crown, but without occlusal contact and retained with fixed appliance for 12 weeks (Figure 3C). Finally, the prosthetic portion was manufactured after removal of the fixed appliance (Figure 4).

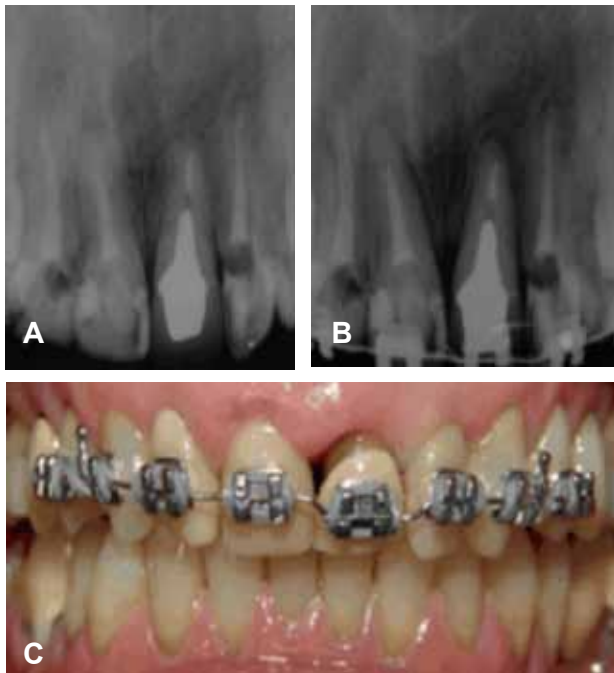


Figure 3 - Case 2: A) Initial radiograph. B) Tooth 21 being extruded. C) Tooth 21 extruded.

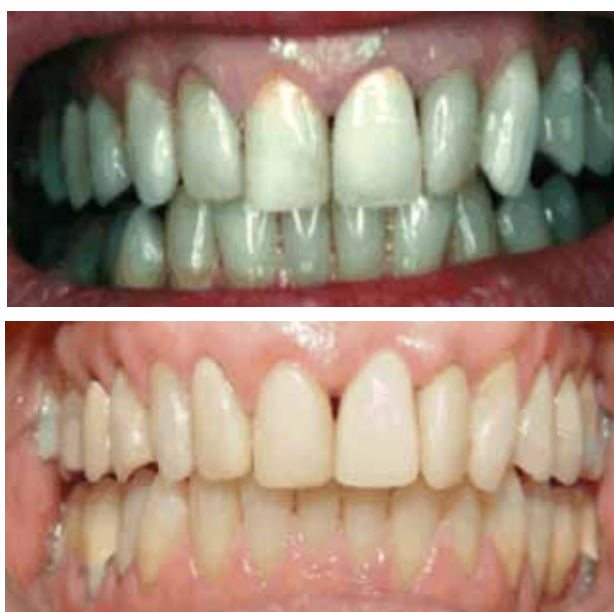

Figure 4 - Case 2: A) Initial photo of the patient. B) Final photo of the patient with implant and temporary retainer on tooth 21.

DISCUSSION

Bone and insertion site loss is the result of periodontal disease, which can compromise both the aesthetic and functional outcomes of the periodontal treatment.¹ After dental extraction, there is an increased loss of alveolar bone within the first 6-24 months and of approximately 25% of the buccal-lingual width within the first year [15]. The growing use of dental implants has stimulated the interest for surgical techniques of bone augmentation in patients with deficient alveolar crest, which impedes attachment of implants [12]. The standard implant treatment protocol has been challenged by experiments aimed at shortening the treatment period and decreasing the surgical procedures involved [1,15].

Orthodontic extrusion is a method by which bone defects can be eliminated or altered, yielding encouraging outcomes [12,14,16]. Introduced by Heithersay [17] in 1973, it was also later used by Ingber [18] and Pontoriero et al. [19]. The technique is based on traction forces applied to the periodontal ligament, thus promoting prolongation of fibers, production of new bone by osteoblasts, and vertical movement of target tissues [1,3,20]. If the technique is performed slowly, one can obtain an adequate amount of hard and soft tissues prior to the implant placement. It is, therefore, a very interesting alternative to the conventional surgical procedures because of its greater simplicity and good results despite requiring a treatment [15]. Once the gingival tissue is attached to the root through the conjunctive tissue, the gingiva follows the vertical movement of the root and alveolus during the process of extrusion [3,13].

It is reported that the force needed to extrude a tooth slowly depends on the amount of bone desired [13]. Forces of 15 g applied to thin roots and of 60 g applied to molars are enough for a slow extrusion [3]. However, this force will depend on the patient's physiological response. It is important to maintain the force constant between the phases of extrusion and hyalinisation so that the desired movement can

happen [3,5]. According to Brindis & Block [13], forces ranging from 25 to 30 g are necessary for moving the tooth slowly, but depending on the root length and possible ankylosis, forces ranging from 50 to 75 g may be needed.

Another relevant factor is the extrusion rate. This is supposed to promote simultaneous movement of tooth and healthy gingiva, avoiding tooth instability as well as excessive discomfort for the patient. The dentist must avoid traumatic occlusion while tooth is erupting as well as the movement of adjacent teeth used for anchorage. Summarizing, this rate may be rapid or slow to promote 1 mm extrusion a week or a month, respectively [13]. In both cases reported in the present paper, extrusion was performed every 3 weeks due to the difficulties faced by the patient to return for evaluation every week. Despite this, good results were obtained, differing from the time period reported by Brindis & Block [13] Maiorana et al. [15] reported that in general 5 weeks are needed to achieve an extrusion of 2 to 3 mm, followed by stabilisation of 8 to 10 weeks. According to Kim et al. [5], rapid movement with intense force is recommended only for extrusion of compromised teeth, except the adjacent periodontum, since this brings rapid clinical results. Also, after extrusion of the tooth before its extraction for implant placement, the tooth should be stabilised for 6 to 12 weeks to allow bone consolidation, which can be analysed by means of radiographic examination [12,13].

However, the regenerated bone is not reliable for primary support of the implant, only serving for obtaining a cover. In this way, grafting procedures in association with tissue regeneration guided by mini-implants, followed by development of the implant-receiving site, have the advantage of optimising the increase of crest and soft tissue [12].

The present study reports two clinical cases of orthodontic extrusion of upper anterior teeth involving two Brazilian adult female patients for later rehabilitation with osseous-integrated implant. In both cases, the teeth were orthodontically extruded more slowly than

that reported in the literature, since the average time for extrusion phase is 4 to 6 weeks and for passive stabilisation is 6 to 8 weeks when bone and tissue remodelling is required prior to the implant placement [3,13]. No dental retention was performed in the cases described above as teeth 21 were extracted for placement of the implants. Several studies reported previous cases of rehabilitation using techniques of orthodontic extrusion, all presenting good results [1,4,7,12,15]. However, the literature also reveals failures in the solution of some cases, all being more complex [5]. It is also important to emphasise that there are certain limitations for orthodontic extrusion followed by implant placement, such as poor aesthetics in the case of severe marginal recession associated with bone loss near the root apex and inadequate vertical bone formation for ideal positioning of the implant in the case of severe circumferential bone loss [1,13]. In addition, any horizontal bone loss will not allow its normal width to be restored by orthodontic extrusion, requiring bone graft as well [13].

Based on case reports presented, orthodontic extrusion is still an excellent technique for those teeth that cannot be restored, thus representing a viable alternative to the conventional surgical augmentation procedures.

REFERENCES

1. Rokn AR, Saffarpour A, Sadrimanesh R, Iranparvar K, Saffarpour A, Mahmoudzadeh M, Soolari A. Implant site development by orthodontic forced eruption of nontreatable teeth: a case report. *Open Dent J.* 2012;6:99-104.
2. Korayem M, Flores-Mir C, Nassar U, Olfert K. Implant site development by orthodontic extrusion. A systematic review. *Angle Orthod.* 2008 Jul;78(4):752-60.
3. Bach N, Baylard JF, Voyer R. Orthodontic extrusion: periodontal considerations and applications. *J Can Dent Assoc.* 2004 Dec;70(11):775-80.
4. Chambrone L, Chambrone LA. Forced orthodontic eruption of fractured teeth before implant placement: case report. *J Can Dent Assoc.* 2005 Apr;71(4):257-61.
5. Kim SH, Tramontina VA, Papalexioiu V, Luczyszyn SM. Orthodontic extrusion and implant site development using an interocclusal appliance for a severe mucogingival deformity: a clinical report. *J Prosthet Dent.* 2011 Feb;105(2):72-7.

6. Smidt A, Lipovetsky-Adler M, Sharon E. Forced eruption as an alternative to tooth extraction in long-term use of oral bisphosphonates: review, risks and technique. *J Am Dent Assoc.* 2012 Dec;143(12):1303-12.
7. Uribe F, Taylor T, Shafer D, Nanda R. A novel approach for implant site development through root tipping. *Am J Orthod Dentofacial Orthop.* 2010 Nov;138(5):649-55.
8. Misch K, Wang HL. Implant surgery complications: etiology and treatment. *Implant Dent.* 2008 Jun;17(2):159-68.
9. Holst S, Blatz MB, Hegenbarth E, Wichmann M, Eitner S. Prosthodontic considerations for predictable single-implant esthetics in the anterior maxilla. *J Oral Maxillofac Surg.* 2005 Sep;63(9 Suppl 2):89-96.
10. Sclar AG. Strategies for management of single-tooth extraction sites in aesthetic implant therapy. *J Oral Maxillofac Surg.* 2004 Sep;62(9 Suppl 2):90-105.
11. Belser UC, Schmid B, Higginbottom F, Buser D. Outcome analysis of implant restorations located in the anterior maxilla: a review of the recent literature. *Int J Oral Maxillofac Implants.* 2004;19 Suppl:30-42.
12. Mantzikos T, Shamus I. Case report: forced eruption and implant site development. *Angle Orthod.* 1998 Apr;68(2):179-86.
13. Brindis MA, Block MS. Orthodontic tooth extrusion to enhance soft tissue implant esthetics. *J Oral Maxillofac Surg.* 2009 Nov;67(11 Suppl):49-59.
14. Mankoo T, Frost L. Rehabilitation of esthetics in advanced periodontal cases using orthodontics for vertical hard and soft tissue regeneration prior to implants - a report of 2 challenging cases treated with an interdisciplinary approach. *Eur J Esthet Dent.* 2011 Winter;6(4):376-404.
15. Maiorana C, Speroni S, Herford AS, Cicciù M. Slow Orthodontic Teeth Extrusion to Enhance Hard and Soft Periodontal Tissue Quality before Implant Positioning in Aesthetic Area. *Open Dent J.* 2012;6:137-42.
16. Borzabadi-Farahani A. Orthodontic considerations in restorative management of hypodontia patients with endosseous implants. *J Oral Implantol.* 2012 Dec;38(6):779-91.
17. Pontoriero R, Celenza F Jr, Ricci G, Carnevale G. Rapid extrusion with fiber resection: a combined orthodontic-periodontic treatment modality. *Int J Periodontics Restorative Dent.* 1987;7(5):30-43.
18. Salama H, Salama M. The role of orthodontic extrusive remodeling in the enhancement of soft and hard tissue profiles prior to implant placement: a systematic approach to the management of extraction site defects. *Int J Periodontics Restorative Dent.* 1993 Aug;13(4):312-33.
19. Makhmalbaf A, Chee W. Soft- and hard-tissue augmentation by orthodontic treatment in the esthetic zone. *Compend Contin Educ Dent.* 2012 Apr;33(4):302-6.
20. Amato F, Mirabella AD, Macca U, Tarnow DP. Implant site development by orthodontic forced extraction: a preliminary study. *Int J Oral Maxillofac Implants.* 2012 Mar-Apr;27(2):411-20.

**Ms. Ana Carolina Rodrigues Danzi Salvia
(Corresponding address)**

Address: Rua Sebastião Tourinho, 11. Jardim Esplanada II.
São José dos Campos, São Paulo, Brazil.
Postal Code: 12242-640.
email: ana_salvia@hotmail.com; ana.salvia@fosjc.unesp.br

Date submitted: 2014 Jul 08

Accept submission: 2014 Nov 03