

# Epidemiological survey of oral and maxillofacial complex biopsies: 13 year retrospective study

Levantamento epidemiológico de biópsias do complexo bucomaxilofacial: um estudo retrospectivo de 13 anos

Antonione Santos Bezerra PINTO<sup>1</sup>, Moara e Silva Conceição PINTO<sup>2</sup>, Ney Soares de ARAÚJO<sup>3</sup>

1 – Dental Radiology and Stomatology – São Leopoldo Mandic – Campinas – SP – Brazil.

2 – University of São Paulo – USP – São Paulo – SP – Brazil.

3 – Discipline of Collective Health, Endodontics, and Dental Clinics – School of Dentistry – Piau State University – Parnaíba – PI – Brazil.

## ABSTRACT

**Objective:** To conduct a retrospective study through epidemiological survey of the biopsies of oral cavity performed at the Center of Pathology, Cytology, and Cytopathology– CEPACC in Parnaíba-PI, from 1998 to 2011. **Material and Methods:** One hundred and thirty-nine referrals and reports were analyzed by evaluating the group and prevalence of oral lesions, anatomical location, and distribution in relation to type, gender, and age. **Results:** Females (52%) showed the greatest prevalence, observing more cases in the age range of 41 to 60 years. The lip was the preferable location of the analyzed lesions. The groups of the lesions in salivary glands (17%), malignant tumors of epithelial origin, benign tumors of conjunctive origin, premalignant lesions of epithelial origin, and odontogenic cysts were the most common lesions. Considering the isolated lesions, squamous cell carcinoma was the most frequent. We observed a greater preference for salivary gland lesions, although great diversity of clinical cases was found. **Conclusion:** The reported lesions occurred mostly in adult females and in groups with salivary gland diseases.

## KEYWORDS

Epidemiology; Oral lesions; Biopsy; Oral Pathology; Diagnosis.

## RESUMO

**Objetivo:** O presente trabalho teve como objetivo realizar um estudo retrospectivo através de um levantamento epidemiológico das biópsias da cavidade oral realizadas no Centro de Patologia, Citologia e Citopatologia – CEPACC em Parnaíba-PI, no período de 1998 a 2011. **Material e Métodos:** Foram analisadas 139 requisições e laudos dos arquivos, avaliando-se o grupo e prevalência das lesões orais, a localização anatômica e a distribuição das mesmas quanto ao tipo, sexo e idade. **Resultados:** Houve um predomínio do gênero feminino (52%), observando-se maior número de casos na faixa etária de 41 a 60 anos, com o lábio como local preferencial das lesões analisadas. Os grupos das lesões de glândulas salivares (17%), tumores malignos de origem epitelial, tumores benignos de origem conjuntiva, lesões pré-malignas de origem epitelial e cistos odontogênicos foram os mais comuns. Considerando-se as lesões de forma isolada, o carcinoma epidermóide foi o mais frequente. Observou-se ainda predileção maior para as lesões de glândulas salivares, embora houvesse grande diversidade para o número encontrado de casos clínicos. **Conclusão:** Concluiu-se que as lesões relatadas foram com maior frequência em mulheres adultas e em grupos como doenças de glândulas salivares.

## PALAVRAS-CHAVE

Epidemiologia; Lesões orais; Biopsia; Patologia bucal; Diagnóstico.

## INTRODUCTION

The oral cavity and the maxillofacial complex have their own anatomical and physiological characteristics that make them different between each other in function of the respective adaptive processes. Among these structures, oral mucosa is the main protection barrier and is exposed to many extrinsic agents as chemical substances (tobacco, alcohol), physical agents (mechanical agents), biological agents (virus), and intrinsic agents corresponding to the systemic or general state of the individual [1].

According to the World Health Organization (WHO) [2], epidemiological survey is one of the main resources to know the current situation and estimate the needs of implementing and maintaining the oral health of a given population. In Brazil, there is the lack of information on the epidemiology of oral lesions in relation to the many variables, such as: age, gender, race, habits, time, stage of development, and working activity [3].

The alterations of tissue normality of oral mucosa exert and are influenced by the individual's general health, in which the knowledge on the frequency and distribution is useful to establish the diagnosis of prevention policies [3].

Having this information provides grants for researches and identification, prevention and controlling programs and enables the diagnosis standardization, which makes easy interpopulational comparison [2,4]. A safe and comprehensive examination of the oral structures should be followed by complementary examinations, such as the biopsy to be further analyzed through the histopathological test, which when properly executed, provides 100% of accuracy in relation to the correct diagnosis [5].

Within this context, the dentist – an especially the Oral and Maxillofacial Surgeon - plays an important role in performing both the examination and diagnosis through biopsy

which is indispensable for the proper planning early treatment, and following-up of the case to reach the cure, reduce sequelae and relapses, and consequently improve the patients' life [6].

The identification of the lesions is guided by the diagnosis process through procedures considering the clinical, imaging, surgical, and histopathological characteristics. This correlation is important to obtain the differential and final diagnosis and to tailor the therapy [7,8].

Thus, this study aimed to perform a retrospective quantitative descriptive study on the main alterations and lesions of the oral and maxillofacial complex treated at the Center of Pathology, Cytology, and Cytopathology – CEPACC in Parnaíba-PI-BR, from 1998 to 2011, by detailing the diagnosis according to the main epidemiological aspects of the lesions, as well as their anatomical location, classification, and prevalence.

## METHODS

This was a descriptive quantitative retrospective study conducted in the Center of Pathology, Cytology, and Cytopathology - CEPACC in the city of Parnaíba-PI-BR, providing services of anatomopathological tests. The referrals and histopathological reports of the Oral and Maxillofacial Complex stored at the aforementioned laboratory from 1998 to 2011 were researched, totalizing 139 samples. Data was tabulated in sheets containing information on the patient, lesion, and histopathological diagnosis.

From the results of the histopathological reports, the final diagnosis of the pathologies occurring in the oral and maxillofacial complex and specific data for the epidemiological analysis were evaluated:

a) gender: male and female;

b) age: the whole years since birth were considered. The age range was divided into four groups: Group 1 (0 to 20 years), Group 2 (21 to

40 years), Group 3 (41 to 60 years), and Group 4 (above 60 years);

c) location: the anatomical area containing the lesion, according to histopathological report;

d) final diagnosis: the diagnosis found in the pathological report of the lesion biopsy and the classification was considered;

These data were transferred to a computer sheet for data interpretation. Inclusion criteria of the histopathological report were:

a) diagnosis of any pathology occurring in the oral and maxillofacial complex;

b) benign, malign, bacterial, viral, and protozoal histological characteristics;

c) results with descriptive diagnosis were excluded;

d) information on gender, age, and anatomical location;

e) all ages were considered;

f) date from 1998 to 2011.

We assumed that CEPACC received anatomopathological samples from oral and maxillofacial area coming from dentists, so that lesions from different areas were submitted to biopsy; comprising different number of

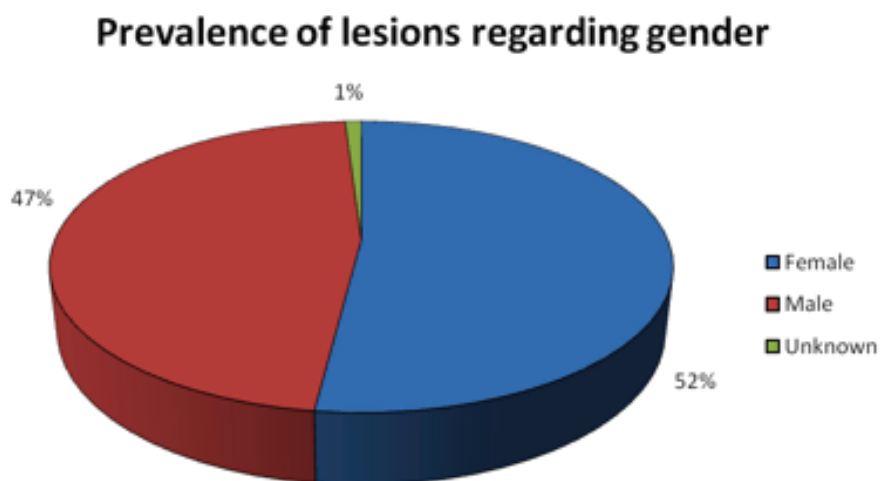
cases distributed by gender, age, and other characteristics that define the profile of cases registered within thirteen years at the aforementioned laboratory.

The Free and Clarified Consent Form was not necessary because the research used data collected from the reports in the files of CEPACC according to the general and specific objectives. No direct involvement, exposure, risks, damages, forms of compensation, and infringement of confidentiality of the material under study. This study was submitted to and approved by the Institution Review Board regarding ethical aspects under protocol no. #2012/0285. The data collected were quantified, statistically analyzed by Microsoft Office® Excel 2010 software, and demonstrated in graphs and tables to visualize and compare the results found.

This research did not provide risks to the patients at CEPACC because it used data from the files and reports.

## RESULTS

Graph 1 shows the comparison between genders with almost equal proportion. We observed a smaller predisposition for females (52%) than males (47%).



**Graph 1** - Prevalence of oral lesions found at Center of Pathology, Cytology, and Cytopathology – CEPACC in the city of Parnaíba-PI, from 1998 to 2011 regarding to gender.  
Source: Direct research.

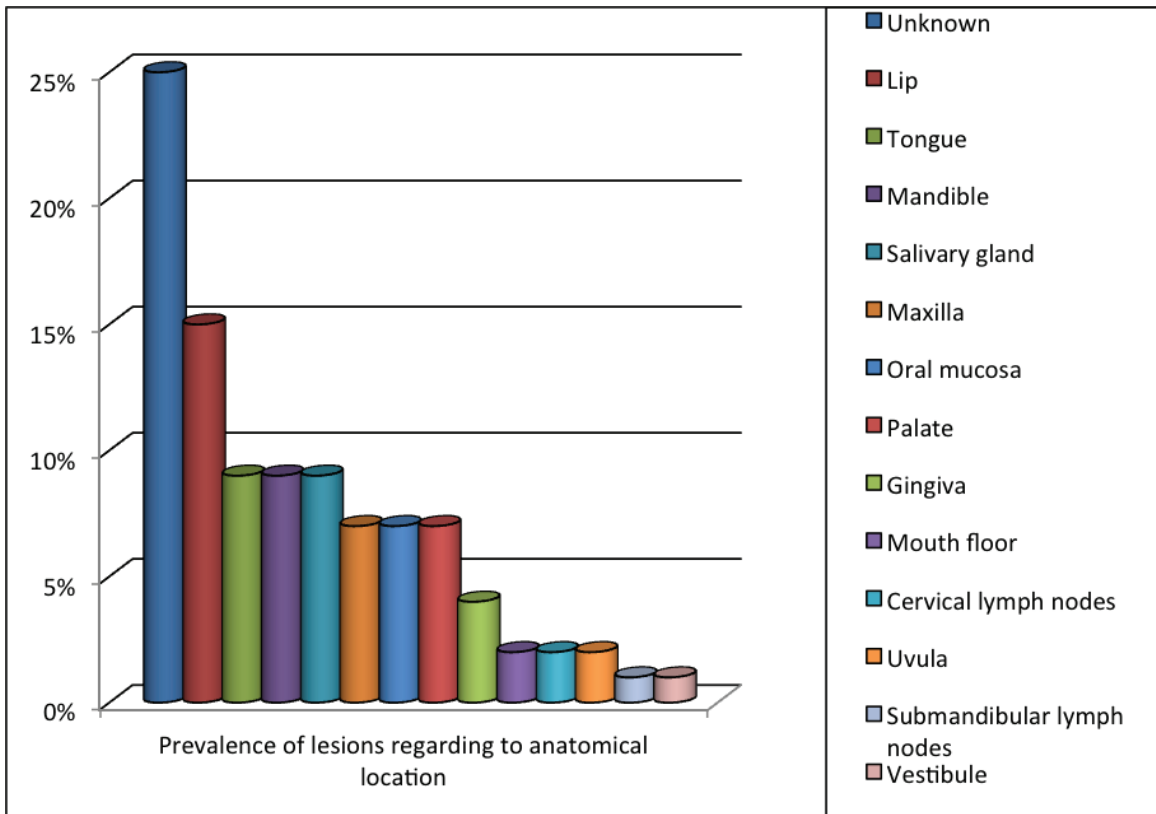
Concerning to anatomical location (Graph 2), the lip was the most common site (15% of the cases), followed by the tongue, mandible, and salivary glands (9%). Oral lesions on maxilla, palate, and oral mucosa occurred in 7% of the cases. The sites of smaller occurrence were the gingiva (4%), mouth floor, uvula, and cervical lymph nodes (2%), mouth vestibule, and submandibular lymph nodes (1%). In most of the cases (25%), the histopathological reports did not provide the necessary information.

By comparing the patients' ages (Graph 3), the age range of greater occurrence of the mouth lesions is between 41 and 60 years, with 32% of the lesions; followed by the age range of 21 and 40 years with 28%; 0 and 20 years with 21%, and smaller prevalence of lesions whose age range above 60 years.

Concerning to the distribution of the lesion groups (Graph 4), the most prevalence

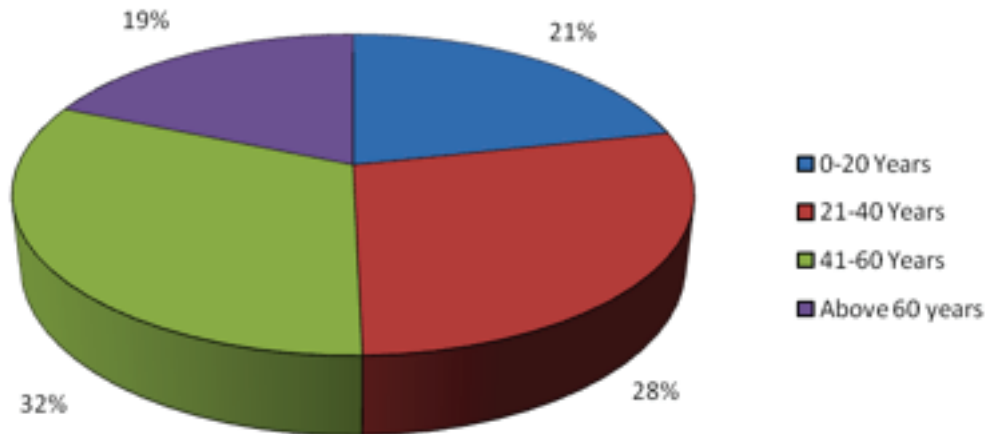
was the salivary glands, respectively followed by malignant tumors of epithelial origin, benign tumors of conjunctive origin, premalignant lesions of epithelial origin, and odontogenic cysts, and other less common groups. No information on the lesion classification were found in 16 (12%) of the samples.

In Table 1, the most prevalent salivary gland lesions were: mucocele, pleomorphic adenoma, chronic sialoadenitis, and Warthin tumor. With regard to the malignant neoplasms of epithelial origin, fifteen cases of squamous cell carcinoma were observed, followed by five cases of basal cell carcinoma. Of the malignant neoplasms of conjunctive origin, the most cited were respectively: fibroma, hemangioma, giant cell granuloma. The most observed premalignant lesions of epithelial origin were leukoplakia and erythroplakia. The most prevalent odontogenic cysts were periapical and dentigerous cysts.

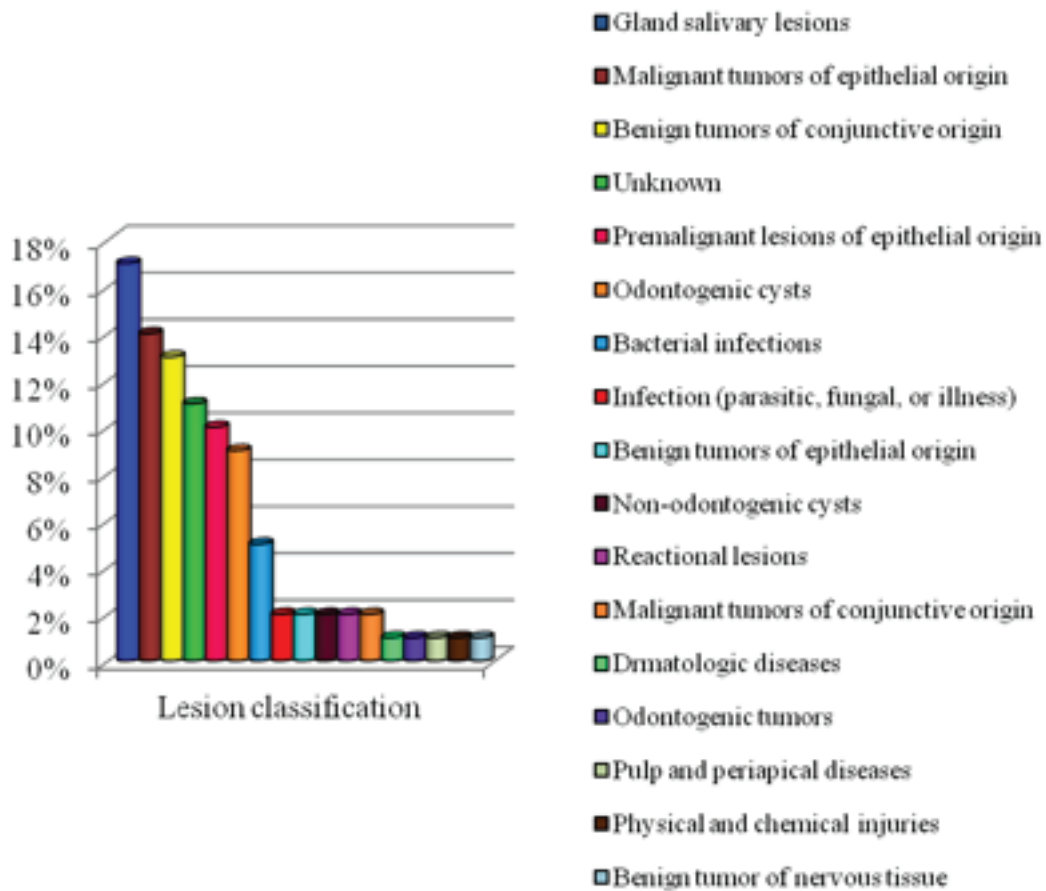


**Graph 2** - Prevalence of oral lesions found at Center of Pathology, Cytology, and Cytopathology – CEPACC in the city of Parnaíba-PI, from 1998 to 2011 regarding to anatomical location. Source: Direct research.

### Prevalence of lesions regarding to age



**Graph 3** - Prevalence of oral lesions found at Center of Pathology, Cytology, and Cytopathology – CEPACC in the city of Parnaíba-PI, from 1998 to 2011 regarding to age. Source: Direct research.



**Graph 4** - Classification and number of oral lesions found in the histopathological reports at Center of Pathology, Cytology, and Cytopathology – CEPACC in the city of Parnaíba-PI, from 1998 to 2011. Source: Direct research.

By observing the lesions per absolute number (Table 2), the most reported lesions were squamous cell carcinoma, leukoplakia, mucocele, fibroma, and periapical cyst.

**Table 1** - Distribution of the lesions from the most prevalent groups, observing the relation with the epidemiological parameters

Most prevalent lesions	n	Gender		Mean age range (Years)
		M	F	
<b>Lesions of Salivary gland</b>	<b>24</b>			
Mucocele	11	04	07	31.9
Pleomorphic adenoma	07	02	05	40.3
Chronic sialoadenitis	04		04	34.5
Wartin Tumor	02	02		41
<b>Malignant tumors of epithelial origin</b>	<b>20</b>			
Squamous cell carcinoma	15	11	04	57.1
Basal Cell carcinoma	05	03	02	59.6
<b>Benign tumor of conjunctive origin</b>	<b>19</b>			
Fibroma	09	02	07	53.4
Hemangioma	06	03	03	42.6
Giant cell granuloma	04	02	02	58
<b>Premalignant lesions of epithelial origin</b>	<b>15</b>			
leukoplakia	12	05	07	66.8
erythroplakia	03	03		22.6
<b>Odontogenic cysts</b>	<b>13</b>			
Radicular cyst	07	03	04	27.2
Dentigerous cyst	06	03	03	17.3

F: Female; M: Male  
Source: Direct research.

**Table 2** - Percentage distribution of the most prevalent oral lesions found at Center of Pathology, Cytology, and Cytopathology – CEPACC, considering the sum (n = 73)

Lesion	%
squamous cell carcinoma	21
leukoplakia	16
Mucocele	15
Fibroma	12
Radicular cyst	10
Pleomorphic Adenoma	10
Hemangioma	8
Dentigerous cyst	8

## DISCUSSION

After the results obtained at the Laboratory of Pathology, Cytology, and Cytopathology – CEPACC in Parnaíba-PI-BR, from 1998 to 2011, the importance of the knowledge on the clinical and pathological variables (especially age, gender, anatomical location, classification, prevalence, time elapsed between the appointment and lesion identification) is emphasized for the diagnosis standardization and development of disease prevention and controlling programs.

This present study highlighted through the retrospective analysis of anatomopathological exams and histological reports the distribution of the oral lesions submitted to biopsy by using epidemiological parameters.

Studies conducted by CRUZ et al. [9] similarly to this study design for oral lesions or mouth alterations observed in a sample of 295 biopsies that 169 cases (57.28%) were female and 126 (42.71%) males, thus showing a predominance of females, corroborating the results of this present study.

This may indicate that women search for dental services more than men because women undergo routine dental and medical examinations, so that the incidence of oral lesions is currently higher [9].

Still, due to a relative inaccuracy and lack of standardization about information on the anatomical location of the lesions is difficult to distribute and categorizing the area because the analysis of the mandible, maxilla, and oral mucosa is surrounded by other structures, which was also found by the studies of Marin et al. [1].

The salivary gland lesions including mucocele (the most common lesion) were more prevalent in females. One of the probable explanations is that this alteration is very common and can appear at any age [10].

Both squamous cell carcinomas and pleomorphic adenoma is frequently found in the

Brazilian population according demonstrated by Lawall et al. [11] and Lopes et al. [12].

The identification of the clinical characteristics of the lesions comprise the comprehensive physical and oral examination, providing important data for the final diagnosis, thus contributing for performing either imaging or histopathological examinations. It is worth noting the lack of information on the characteristics, anatomical location (25%), lesion classification (12%), habits and race of the patient and type of the biopsy, which if accurately informed constitute important data for conducting the diagnosis [1].

Possibly, this occurred due to the lack of knowledge of the professional who executed the surgical procedure on the importance of the biopsy for the histopathological diagnosis. The correct filling of the biopsy reports could influence the frequency distribution of the information analyzed in the population groups of the city of Parnaíba. Also, they would know deeply the behavior profile of the pathologies in the individuals.

It has been estimated that more than two hundred diseases may affect the mouth. Certain lesions have their own characteristics inside the mouth, so that the professional should know the frequency of many lesion types occur in different anatomical locations [9].

The dentist plays a very important role in preventing and early diagnosing of oral cancer. The dentist is the professional with privileged access to oral cavity, has the knowledge to act on the health education, and is responsible to act directly on improving the oral and general health of the population. Therefore, the dentist must apply this knowledge that should be constantly improved to contribute with early cancer prevention [5].

The patient should not be seen as a single kidney or tooth, but fully. The patient is an individual with expectations on the way he/she understands the disease, and has the right to be treated entirely, from primary to tertiary

attention. The patient should not undergo treatment in which initial lesions and less time-consuming treatment are postponed to more advanced stages, because of the segmentally prevention performed by the dentist [10].

Preventive actions target to clarify the population about the disease, risk factor, treatment, and cure possibilities should be implemented to make viable the early diagnosis, a fact that may modify the epidemiological profile of the disease. This is unaltered or higher in some Brazilian regions [13].

Likely to other epidemiological surveys, this study limitation is that it worked with data in the clinical files filled by different professionals and the omission of important clinical data is frequent.

## CONCLUSION

According the methodology employed and based on the results obtained, it can be concluded that the patients whose lesions were diagnosed in the Center of Pathology, Cytology, and Cytopathology – CEPACC in the city of Parnaíba-PI, from 1998 to 2011 were predominantly women at the age range of 41 to 60 years. The location of the lesions was preferably on the lip. The most frequent lesion group was the salivary glands, highlighting the mucocele and the pleomorphic adenoma, followed by malignant tumors of epithelial origin, benign tumors of conjunctive origin, premalignant lesions of epithelial origin, and odontogenic cysts. The most prevalent lesion was the squamous cell carcinoma.

## REFERENCES

1. Adeyemi BF, Kolude BM, Akang EE. A retrospective histopathological review of oral squamous cell carcinoma in a Nigerian teaching hospital. *Afr J Med Med Sci.* 2011 Jun;40(2):153-8.
2. Demko CA, Sawyer D, Slivka M, Smith D, Wotman S. Prevalence of oral lesions in the dental office. *Gen Dent.* 2009 Sep-Oct;57(5):504-9.
3. Dhanuthai K, Banrai M, Limpanaputtajak S. A retrospective study of paediatric oral lesions from Thailand. *Int J Paediatr Dent.* 2007 Jul;17(4):248-53.

4. Gervásio OL, Dutra RA, Tartaglia SM, Vasconcellos WA, Barbosa AA, Aguiar MC. Oral squamous cell carcinoma: a retrospective study of 740 cases in a Brazilian population. *Braz Dent J*. 2001;12(1):57-61.
5. Thulesius H, Pola J, Håkansson A. Diagnostic delay in pediatric malignancies—a population-based study. *Acta Oncol*. 2000;39(7):873-6.
6. Jensen JL. Superficial mucoceles of the oral mucosa. *Am J Dermatopathol*. 1990 Feb;12(1):88-92.
7. Lima GS, Fontes ST, Araújo LMA, Etges A, Tarquinio SBC, Gomes APN. A survey of oral and maxillofacial biopsies in children. A single-center retrospective study of 20 years in Pelotas-Brazil. *J Appl Oral Sci*. 2008;16(6):397-402.
8. Löhler J, Gerstner AO, Bootz F, Heinritz H, Fryen A, Fryen G, et al. Prevalence of abnormal mucosal findings in patients in HNO practices. *HNO*. 2012 Mar;60(3):240-8.
9. Osterne RL, Costa FW, Mota MR, Vidal Patrocínio RM, Alves AP, Soares CE, Sousa FB. Lip lesions in a Brazilian population. *Craniofac J Surg*. 2011 Nov;22(6):2421-5.
10. Shah SK, Le MC, Carpenter WM. Retrospective review of pediatric oral lesions from a dental school biopsy service. *Pediatr Dent*. 2009 Jan-Feb;31(1):14-9.
11. Sousa FB, Etges A, Corrêa L, Mesquita RA, de Araújo NS. Pediatric oral lesions: a 15-year review from São Paulo, Brazil. *J Clin Pediatr Dent*. 2002;26(4):413-8.
12. Splieth CH, Sümrig W, Bessel F, John U, Kocher T. Prevalence of oral mucosal lesions in a representative population. *Quintessence Int*. 2007 Jan;38(1):23-9.
13. Takashima RM, Etges A. Epidemiological survey of biopsy performed in a residency program in bucco maxillofacial surgery. *RG0 (Porto Alegre)*. 2012;60(3):337-42.

**Antonione Santos Bezerra Pinto  
(Corresponding address)**

Rua Maria Teresa Dutra, 90, CEP 64202-338,  
Parnaíba-PI.  
E-mail: antonione182@hotmail.com

Date submitted: 2014 Feb 16

Accept submission: 2015 Nov 30