

## Dental approach in unilateral osteoarthritis of temporomandibular joint: case report

Abordagem odontológica na osteoartrite unilateral da articulação temporomandibular: relatório do caso

Carlos Wallace CUNHA<sup>1</sup>, Carolina Almeida RODRIGUES<sup>1</sup>, Laís Valencise MAGRI<sup>1</sup>, Bruno Henrique Figueiredo MATOS<sup>1</sup>, César BATAGLION<sup>1</sup>, Marcelo Oliveira MAZZETTO<sup>1</sup>

1 – Department of Restorative Dentistry – Ribeirão Preto School of Dentistry – University of São Paulo (FORP/USP) – Ribeirão Preto – SP – Brazil.

### ABSTRACT

**Objective:** To describe a case of unilateral TMJ osteoarthritis from the Dentistry point of view, aiming to restore the quality of life through non-invasive procedures. **Description of case:** M.C.B., female, 69 years, complaining about a sudden change in the bite, difficulty to chewing/opening mouth and pain in the orofacial region. At extraoral examination, we observe the presence of crepitus in the left TMJ, click in the right TMJ (electrovibratography) and pain on palpation in the left TMJ region. Absence of tooth contacts on the right side in maximum habitual intercuspation (MHI). The intraoral examination revealed the presence of inflammation and excessive wear in the left mandibular condyle (osteoarthritis), visualized by computed tomography and magnetic resonance imaging with contrast. The patient underwent treatment by occlusal splint (night use), overlay removable partial dentures (daytime use), application of lower level laser therapy and transcutaneous electrical nervous stimulation (TENS). Masticatory function, mouth opening, and aesthetics improved. **Conclusion:** Conservative therapies may be a good option for the re-establishment of the quality of life in subjects with TMJ osteoarthritis, inasmuch as it can postpone or delete the indication of more invasive techniques (e.g. surgery).

### KEYWORDS

Osteoarthritis; Temporomandibular joint disorders; Temporomandibular joint.

### RESUMO

**Objetivo:** Descrever um caso de osteoartrite da ATM unilateral do ponto de vista Odontológico, com o objetivo de restaurar a qualidade de vida através de procedimentos não invasivos. **Descrição do caso:** M.C.B., do gênero feminino, 69 anos, com queixa principal de mudança repentina na mordida, dificuldade de mastigação e dor na região orofacial durante a abertura bucal. Ao exame físico, observamos a presença de crepitação na ATM esquerda, estalido na ATM direita (eletrovibratografia) e dor à palpação da região da ATM esquerda. Ausência de contatos dentais no lado direito em intercuspidação habitual máximo (MHI). O exame intraoral revelou a presença de inflamação e desgaste excessivo no côndilo mandibular esquerdo (osteoartrite), visualizado pela tomografia computadorizada e ressonância magnética com contraste. O paciente foi submetido a tratamento por placa oclusal (uso noturno) e prótese parcial removível (uso durante o dia), aplicação de laserterapia de baixa intensidade e estimulação nervosa elétrica transcutânea (TENS). Houve melhora na função mastigatória, a abertura bucal, e estética. **Conclusão:** terapias conservadoras podem ser uma boa opção para o restabelecimento da qualidade de vida em indivíduos com osteoartrite da ATM, na medida em que pode adiar ou eliminar a indicação de técnicas mais invasivas (por exemplo, cirurgia).

### PALAVRAS-CHAVE

Osteoartrite; Desordens temporomandibulares; Articulação temporomandibular.

## BRIEF LITERATURE REVIEW

Temporomandibular disorders (TMD) are considered a significant public health problem, affecting approximately 5-12% of the population [1]. They are characterized by a set of conditions affecting the temporomandibular joints (TMJ) and/or muscles of mastication, exhibiting pain and functional limitation [2,3]. The reference standard for diagnosis in the field is based on the Diagnostic Criteria for Temporomandibular Disorders, which features as one of the categories for classification of intra-articular TMJ degenerative diseases [4].

Osteoarthritis, also known as osteoarthrosis or degenerative joint disease, is defined as a condition characterized by deterioration and abrasion of articular tissue and concomitant remodeling of the underlying subchondral bone due to overload mechanism of remodeling [3]. The progressive loss of articular disc in TMJ osteoarthritis is an imbalance between the reparative processes predominantly and degradation controlled by chondrocytes [5]. When this mechanism is involved in non-idiopathic joint collapse process, e.g., direct trauma to the TMJ, local infection or a history of active systemic arthritis, this is classified as a secondary osteoarthritis [3].

Individuals presenting TMJ degenerative diseases usually have crepitus; long shifting from centric relation (CR) to maximum habitual intercuspation (MHI) position; also, skeletal anterior open bite, overbite reduction, and increased overjet may also be associated with osteoarthritis and are extreme variations of these conditions [6,7]. In severe cases, the masticatory function is compromised and limited mouth opening occurs.

When the diagnosis is established, treatment can be directed to the control of active inflammation, preservation of function, preventing the increase of deformities and pain relief, so that different types of

treatment may be used [7]. Among the more conservative modalities are physical therapy, electrical stimulation, medications, ointments, supplements, steroid injections, hyaluronic acid injections and acupuncture [8]. In some cases, surgical treatment also may be indicated [9].

Because of the complexity of establishing a correct diagnosis of the clinical condition of osteoarthritis, its complications and the various therapeutic modalities that may be involved, the purpose of this case report was to demonstrate the whole process of achieving the correct diagnosis, along with the clinical characteristics found and other laboratory tests as well as the entire therapeutic process employed to date.

Therefore, this study aimed to describe a case of unilateral TMJ osteoarthritis from a dental point of view, aiming to restore the quality of life through non-invasive procedures.

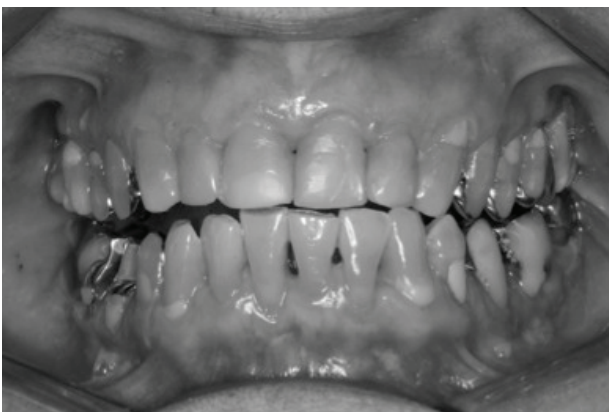## DESCRIPTION OF CASE

This is a clinical case does not demand approval by the Ethical Research Committee of the institution. The patient read and signed a free and clarified consent form allowing the publication considering that the identity remains anonymous.

M.C.B., female, aged 69 years, attended at the Temporomandibular Disorders and Orofacial Pain Service of the School of Dentistry of Ribeirão Preto (FORP / USP) complaining about change in biting, masticatory disability and difficulty in opening the mouth, but without complaining about pain. During data collection, the patient reported that her complaints had lasted approximately 12 months. Also, she reported already searching for other dental professionals, otorhinolaryngologist, and psychologist. In these previous appointments, some therapies have been tested, such as replacement of the articular disc and some medications were prescribed: benzodiazepine and tricyclic antidepressant.

During anamnesis, the presence of night and day bruxism was noted. The complaints of discomfort from the bite was always repeated, as well as reports of great emotional stress in relation to family issues that existed, requiring psychological counseling. At the initial evaluation, active mouth opening was of 39 mm with no pain, lateral right of 2 mm, left of 4 mm, and protrusion of 2 mm. During mandibular opening, there was the presence of left shift and joint noises: crepitus and clicking from the left to the right side, confirmed by electrovibratography (SonoPAK QS-System - BioReserch, Inc., Milwaukee, Wisconsin).

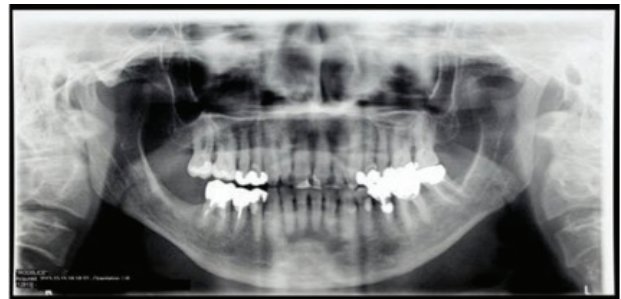At intraoral examination, the patient was in satisfactory condition, but with totally unfavorable occlusion, absence of right tooth contacts in relation to the antagonist at MHI, (Figure 1). During manipulation to centric relation, it was observed marked stiffness, preventing the centric assessment. Furthermore, on the palpation of the main muscles involved in the stomatognathic system functions, there was total absence of pain. Notwithstanding, the patient reported moderate pain on the lateral pole of the left TMJ. Still, the Vertical Dimension (VD) and Free Functional Area (FFA) was evaluated, and the values found were 74 mm, 72 mm and 2 mm for the rest vertical dimension, vertical dimension of occlusion and FFA, respectively.



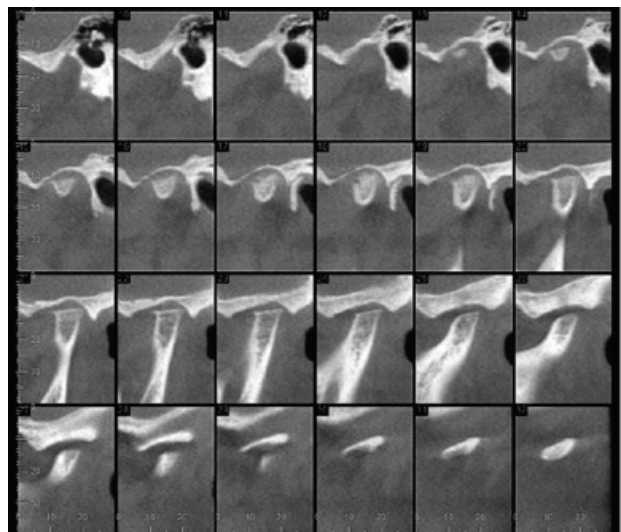
**Figure 1** - Occlusion at maximum habitual intercuspation (MHI). Note the absence of contacts between antagonist teeth on the right side.

The patient underwent some additional tests such as panoramic radiograph (Figure 2), transcranial tomography (Figure 3) and MRI (Figure 4). It was possible to observe excessive wear of the left condyle with displacement and structural changes on the surface of the disc. The torque due to left mandibular condylar intrusion led to the absence of dental MIH contacts at the right side, as reported by Okeson [10].

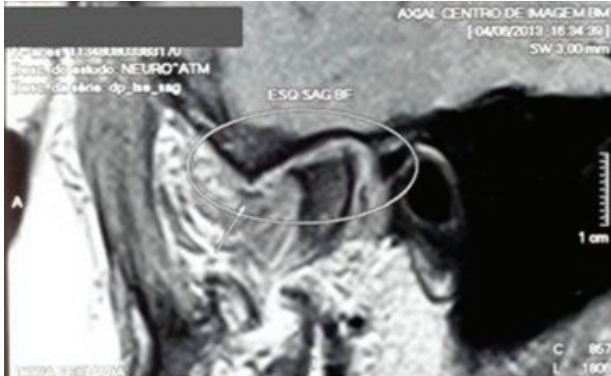
Besides all the evaluations performed in the dental field, the patient went to a rheumatologist to assist in determining the correct diagnosis. Magnetic resonance imaging with gadolinium enhancement, requested by the rheumatologist revealed an inflammatory process in the left TMJ, associated with the degenerative process (Figure 5). Thus, it was possible to establish the diagnosis of secondary unilateral osteoarthritis (left side).



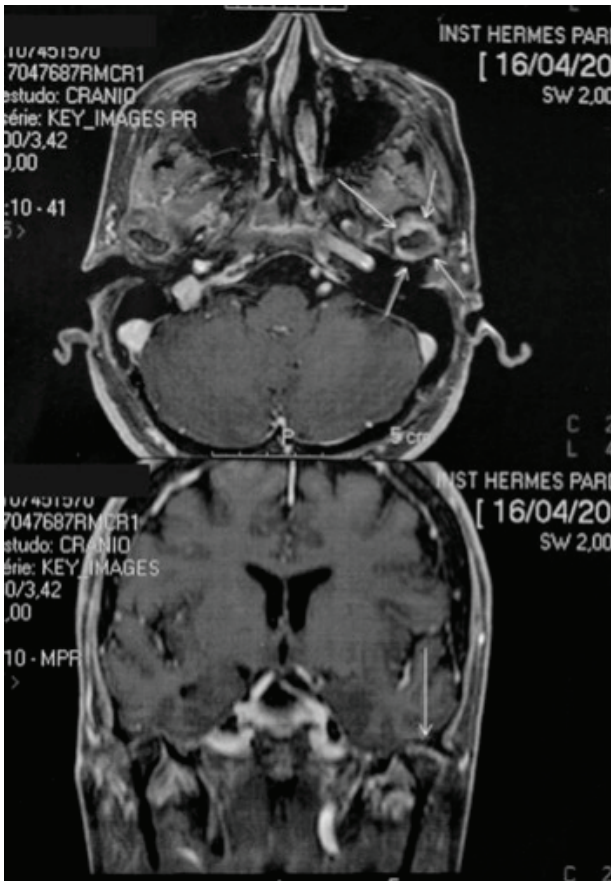
**Figure 2** - Panoramic radiograph.



**Figure 3** - Computed tomography scan (CT) of the left TMJ.



**Figure 4** - Magnetic Resonance Imaging (MRI) of the left TMJ.



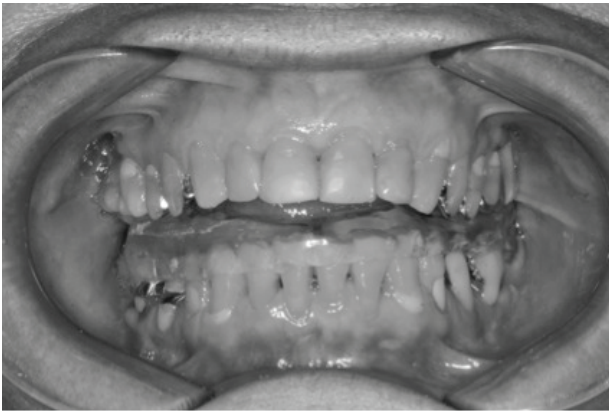**Figure 5** - Magnetic Resonance Imaging (MRI) with contrast showing inflammation in the left TMJ.

The following dental therapy was applied: application of Transcutaneous Electric Nerve Stimulation (TENS) and Low Level Laser Therapy (LLLT) in order to improve the range of mandibular movements and the patient's mandible manipulation. The TENS protocol

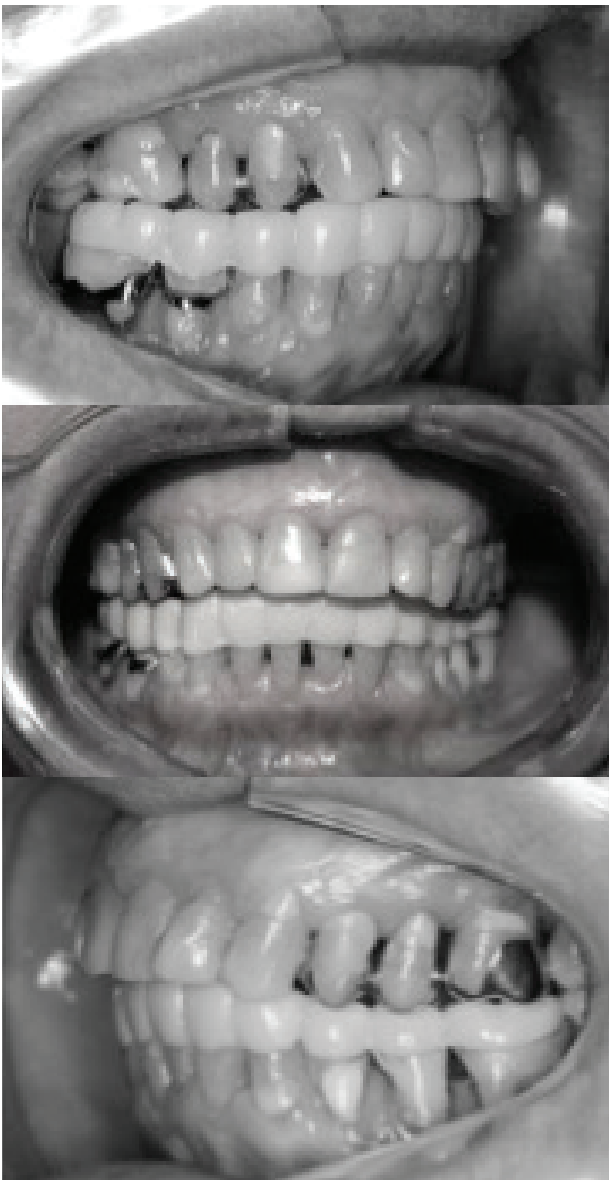
(TENS digital med IV - CARCI - São Paulo, Brazil) was used by applying a pulse of 100, at a frequency of 150 Hz for 35 minutes for a period of four weeks. LLLT was applied as standard protocol of the Temporomandibular Disorders and Orofacial Pain Service (FORP). It was used a Gallium-Aluminum-Arsenic laser (GaAlAs - TWIN LASER MMOptics Ltd., São Carlos, São Paulo) with 780 nm, under application of 75 J/cm<sup>2</sup> (60mW/50 s) on 5 points: central, superior, inferior, anterior and posterior sides of the TM. On the facial muscles, the laser application was 30J/cm<sup>2</sup> (60mW/20 s) on three regions of the superficial masseter muscle (the upper, middle and lower thirds) and the anterior bundle of the temporalis muscle.

An oclusal splint made with acrylic resin was performed in order to give a better distribution of the loads on the teeth and minimize loads on the TMJ during sleep (Figure 6). Furthermore, an overlay removable partial denture (ORPD) was installed on the lower arch generating dental contacts at MHI on all teeth, and facilitating mastication (Figure 7).

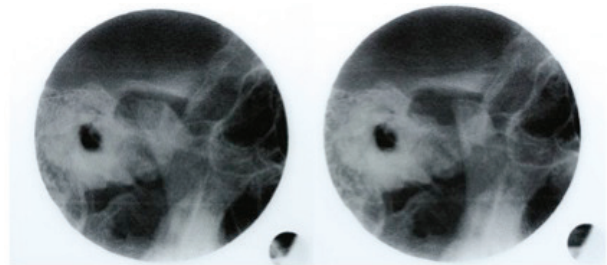
The stabilizing plate was used at nighttime to induce neuromuscular balance and ORPD was used during the day to improve the grinding of food. The stabilizing plate established by a more favorable TMJ position, proven by transcranial radiograph (Figure 8). Besides all dental treatment modalities used, the patient was referred for treatment with a rheumatologist, in order to stop the inflammatory process of the left TMJ preventing the progression of degenerative changes.



**Figure 6** - Stabilizing plate.



**Figure 7** - The overlay removable partial denture (ORPD).



**Figure 8** - Transcranial Radiograph with occlusal splint.

## DISCUSSION

Degenerative joint disease of the TMJ is a common finding and presents as a chronic debilitating disease, a result of changes in joint structure due to the degradation and loss of articular tissue, along with changes in subchondral bone and adjacent soft tissues [11]. The progressive nature of the disease leads to the need for early diagnosis and treatment in order to stop the process of joint wear and change in bone structures.

In this case report, osteoarthritis was present only in the left TMJ, but it is known that in some cases it can affect both joints. In addition, the literature reveals a higher prevalence in women, which some authors explain by changes that occur in estrogen receptors, leaving the women more predisposing to degenerative diseases [12,13].

It has a complex and multifactorial etiology with the following risk factors: age, genetic (congenital and developmental abnormalities), trauma (previous fracture cases, excessive loads and twisting, etc.) disorders of joint instability or inadequate muscular strength/muscular endurance, internal disorders and systemic conditions (generalized osteoarthritis, infection and degenerative idiopathic process) [7,14].

The infection plays an important role in the destruction of articular tissue in osteoarthritis with the interaction of multiple agents, immune cells, fibroblasts and chondrocytes and may quickly destroy the joint structures [15]. In this present clinical case, it seemed that the infection found in the left TMJ by MRI has acted as the

main etiological factor of all the degenerative process, establishing a diagnosis of secondary osteoarthritis. That was increased by the clenching performed by the patient under great influence of psychological and emotional aspects.

Both the clinical approaches of osteoarthritis and the patient's uncomfortable masticatory function caused due to limited mouth opening and rigidity of mandibular region impact on her quality of life. Accordingly, dental treatment should not interfere with treatment of osteoarthritis, but improves the effect determined by the medical approach. In this case report, obviously, the treatment of the etiological cause is of medical competence, so that the patient was referred to a rheumatologist who diagnosed the TMJ inflammation, prescribed anti-inflammatory drugs to stop the inflammatory process, preventing new stages of left TMJ deterioration.

Due to the absence of reported pain in this case, the established therapies presented aimed to reduce muscle stiffness, facilitating the opening, lateral, and protrusive movements and improving the masticatory function, initially compromised by unilateral posterior open bite.

The stabilizing plate may be considered as the most preferred method for treatment of most TMD, since they are capable of providing a suitable occlusion at centric relation [16]. The centric relation position has been considered capable of reducing abnormal muscle activity, contributing to the formation of so-called "neuromuscular balance" of the masticatory system [17]. In this case report, the installation of the stabilizing plate was precisely to: 1) create that neuromuscular balance, because the patient had limitation in opening, lateral and protrusion movements; 2) handle the large stiffness of the muscles. It was observed throughout following-up period that the mandibular opening (44 mm), left lateral (5 mm) and right lateral (3.5 mm) movements improved. Furthermore, during use of the plate, there is an increase in the intra-articular space (Figure 8), which also serves as protection of joint structures, avoiding major wear.

Considering the age of the patient and aiming at procedures that could restore the masticatory function conservatively, installing an ORPD to compensate for the absence of posterior contacts was considered the best treatment option. The ORPD is usually defined as an atypical partial denture that covers the occlusal surfaces of the teeth without additional wear for support, aiming to restore the vertical dimension, in the presence of tooth wear or improve masticatory function, which was the main purpose of this case report [18]. With the presence of bilateral and simultaneous contacts after installing the ORPD, the stomatognathic system functions are now in balance, facilitating the food fragmentation and swallowing. The stabilizing plate continued to be used at night to sleep in a position to facilitate muscle balance. And the primary goal of therapy was achieved, the patient satisfaction, after installing the ORPD was notorious, causing an increase in quality of life reported by the patient.

By facing secondary osteoarthritis, it was possible to emphasize the importance of a correct diagnosis, often involving many professionals from various fields and exams for making the correct therapeutic approach. In this case, conservative therapies were able to significantly improve the quality of life by eliminating or delaying the indication of more invasive techniques such as surgical procedures associated with the manufacture of condylectomy prosthesis (total joint reconstruction).

## REFERENCES

1. National Institute of Dental and Craniofacial Research. Facial Pain [Internet]. Disponível em <http://www.nidcr.nih.gov/DataStatistics/DataTop/FacialPain/> (acessado 06/09/2014).
2. Ohrbach R, Fillingim RB, Mulkey F, Gonzalez Y, Gordon S, Gremillion H, et al. Clinical findings and pain symptoms as potential risk factors for chronic TMD: descriptive data and empirically identified domains from the OPPERA case-control study. *J Pain*. 2011 Nov;12(11 Suppl):T27-45. doi: 10.1016/j.jpain.2011.09.001.
3. De Leeuw R, Klasser GD. *Orofacial Pain: Guidelines for Assessment, Diagnosis, and Management*. 5.ed. São Paulo: Quintessence; 2013.

4. Schiffman E, Ohrbach R, Truelove E, Look J, Anderson G, Goulet JP, et al. Diagnostic Criteria for Temporomandibular Disorders (DC/TMD) for Clinical and Research Applications: recommendations of the International RDC/TMD Consortium Network\* and Orofacial Pain Special Interest Group†. *J Oral Facial Pain Headache*. 2014 Winter;28(1):6-27. doi: 10.11607/jop.1151.
5. Dijkgraaf LC, de Bont LG, Boering G, Liem RS. The structure, biochemistry and metabolism of osteoarthritic cartilage: a review of the literature. *J Oral Maxillofac Surg*. 1995 Oct;53(10):1182-92.
6. Pullinger AG, Seligman DA. Quantification and validation of predictive values of occlusal variable in temporomandibular disorders using a multifactorial analysis. *J Prosthet Dent*. 2000 Jan;83(1):66-75.
7. Tanaka E, Detamore MS, Mercuri LG. Degenerative disorders of the temporomandibular joint: etiology, diagnosis, and treatment. *J Dent Res*. 2008 Apr;87(4):296-307.
8. Langworthy MJ, Saad A, Langworthy NM. Conservative treatment modalities and outcomes for osteoarthritis: the concomitant pyramid of treatment. *Phys Sportsmed*. 2010 Jun;38(2):133-45. doi: 10.3810/psm.2010.06.1792.
9. Villanueva-Alcojol L, Monje-Gil F, Gonzalez-Garcia, Moreno-Garcia, Serrano-Gil H, Maestre-Rodriguez Q, et al. Costochondral graft with green-stick fracture used in reconstruction of the mandibular condyle: experience in 13 clinical cases. *Med Oral Patol Oral Cir Bucal*. 2009 Dec 1;14(12):e663-7.
10. Okeson JP. *Tratamento das Desordens Temporomandibulares e Oclusão*. 7.ed. São Paulo: Mosby Elsevier. 2013.
11. Kalladka M, Quek S, Heir G, Eliav E, Mupparapu M, Viswanath A. Temporomandibular joint osteoarthritis: Diagnosis and long-term conservative management: A topic review. *J Indian Prosthodont Soc*. 2014 Mar;14(1):6-15. doi: 10.1007/s13191-013-0321-3.
12. Magnusson C, Nilsson M, Magnusson T. Degenerative changes of the temporomandibular joint. Relationship to ethnicity, sex, and occlusal supporting zones based on a skull material. *Acta Odontol Scand*. 2012 May;70(3):207-12. doi: 10.3109/00016357.2011.629628.
13. Kang SC, Lee DG, Choi JH, Kim ST, Kim YK, Ahn HJ. Association between estrogen receptor polymorphisms and pain susceptibility in female temporomandibular joint osteoarthritis patients. *Int J Oral Maxillofac Surg*. 2007 May;36(5):391-4.
14. Buckwalter JA. The role of mechanical forces in the initiation and progression of osteoarthritis. *HSS J*. 2012 Feb;8(1):37-8. doi: 10.1007/s11420-011-9251-y.
15. Sun L, Wang X, Kaplan DL. A 3D cartilage- Inflammatory cell culture system for the modeling of human osteoarthritis. *Biomaterials*. 2011 Aug;32(24):5581-9. doi: 10.1016/j.biomaterials.2011.04.028.
16. Al-Ani Z, Gray RJ, Davies SJ, Sloan P, Glennly AM. Stabilization splint therapy for the treatment of temporomandibular myofascial pain: a systematic review. *J Dent Educ*. 2005 Nov;69(11):1242-50.
17. Gray RJM, Davies SJ. Occlusal splints and temporomandibular disorders: why, when, how? *Dent Update*. 2001 May;28(4):194-9.
18. Pavarina AC, Machado AL, Vergani CE, Giampaolo ET. Overlay removable partial dentures for a patient with ectodermal dysplasia: a clinical report. *J Prosthet Dent*. 2001 Dec;86(6):574-7.

**Carolina Almeida Rodrigues  
(Corresponding address)**

School of Dentistry of Ribeirão Preto, University of São Paulo (FORP-USP), Av. do Café s/n, Ribeirão Preto, SP, Brazil, CEP:14040-904  
E-mail: carolinaalmeidarodrigues@hotmail.com

Date submitted: 2015 Aug 17

Accept submission: 2016 Feb 15