



CASE REPORT

doi: 10.14295/bds.2017.v20i3.1379

Anticoagulant-induced oral bleeding

O uso de anticoagulante induzindo o sangramento bucal

Victor COSTA¹; Estela KAMINAGAKURA¹

1 – São Paulo State University (Unesp) – Institute of Science and Technology – São José dos Campos – Department of Biosciences and Oral Diagnosis – SP – Brazil.

ABSTRACT

Warfarin is an anticoagulant used to prevent thrombosis, cardiac arrhythmias, atrial fibrillation, and recurrence of pulmonary embolism. A 69-year-old male patient reported episodes of four heart attacks, stroke, pulmonary emphysema, varicose veins, thyroid dysfunction, and a history of angioplasty. They use daily dose of 5 mg. Intraoral clinical examination revealed a bleeding nodular lesion of purple color with irregular borders and a smooth surface. The prothrombin time was 68.9 seconds, activity was 10%, and the international normalized ratio (INR) was 8.26. Based on these results, the patient received a single dose of 2.5 mg vitamin K via subcutaneous route. The final diagnosis was oral anticoagulant-induced lesions. Clinicians should be familiar with the side effects of anticoagulants, which are rare in the oral cavity, but can be life-threatening if diagnosed late or inaccurately, especially in older patients that often use many drugs.

KEYWORDS

Anticoagulant; Hemorrhage; Warfarin; Mouth.

RESUMO

A varfarina é um anticoagulante usado para prevenir a trombose, arritmias cardíacas, fibrilação atrial e a recorrências de embolia pulmonar. Um paciente do sexo masculino de 69 anos de idade relatou quatro episódios de ataques cardíacos, um acidente vascular cerebral, enfisema pulmonar, varizes, disfunção da tireoide e histórico de angioplastia. O paciente utilizava uma dose diária de 5 mg de varfarina. O exame clínico intraoral revelou uma lesão nodular hemorrágica de cor púrpura com bordas irregulares e uma superfície lisa. O tempo de protrombina foi de 68,9 segundos, a atividade foi de 10%, e a proporção normalizada internacional (INR) foi de 8,26. Com base nestes resultados, o paciente recebeu uma dose única de 2,5 mg de vitamina K por via subcutânea. O diagnóstico final foi de lesões hemorrágicas bucais induzidas pelo uso de anticoagulantes. Profissionais clínicos devem estar familiarizados com os efeitos colaterais causados pelo uso de anticoagulantes, que são raros na cavidade bucal, mas podem ser fatais se diagnosticados tardiamente ou de forma imprecisa, principalmente em pacientes idosos que costumam fazer uso de muitos outros medicamentos.

PALAVRAS-CHAVE

Anticoagulante; Hemorragia; Varfarina; Boca.

INTRODUCTION

Warfarin is an anticoagulant used to prevent thrombosis, cardiac arrhythmias, atrial fibrillation, and recurrence of pulmonary embolism [1]. The drug acts as a vitamin K antagonist, blocking the recycling of vitamin K and preventing the

γ -carboxylation of glutamate residues in clotting factors II, VII, IX and X and proteins C, S and Z [2,3]. Warfarin is mostly metabolized by CYP-2CP microsomal liver enzymes, this metabolism may be affected by different environmental factors, such as genetic mutations, especially in CYP2 complex, drug interactions and diet, those factors can change the pharmacodynamics and pharmacokinetics of warfarin metabolism

prolonged international normalized ratio (INR) and leading to toxicity. The INR is used to monitor warfarin anticoagulation and values > 3.0 are considered abnormal. [3,4]. Inappropriate doses of warfarin can cause bleeding and vascular injuries, putting the patient's life at risk [2].

CASE PRESENTATION

A 69-year-old male patient complained of "blood blisters in the mouth and a purple tongue". During anamnesis, the patient reported episodes of four heart attacks, stroke, pulmonary emphysema, varicose veins, thyroid dysfunction, and a history of angioplasty. In view of these different health problems, the patient needed to take many drugs, including warfarin at a daily dose of 5 mg. The patient was a smoker for 40 years and reported chronic alcohol consumption for 15 years. Intraoral clinical examination

revealed a bleeding nodular lesion of purple color with irregular borders and a smooth surface. The lesion measured 3 cm in its major diameter and was located in the left soft palate (Figure 1A). Similar lesions were detected in the lateral border and dorsum of the tongue (Figure 1B). The patient had no breathing or swallowing difficulties. The differential diagnosis included vascular hamartoma, angina bullosa haemorrhagica, and drug-induced hematoma. Reassessment of the patient by a hematologist was requested. The prothrombin time was 68.9 seconds, activity was 10%, and the international normalized ratio (INR) was 8.26. Based on these results, the patient received a single dose of 2.5 mg of vitamin K via subcutaneous route for systemic re-establishment. The final diagnosis was oral anticoagulant-induced lesions. The warfarin dose was adjusted to 2.5 mg/day. Resolution of the oral lesions was observed after 1 week (Figure 1C and 1D).

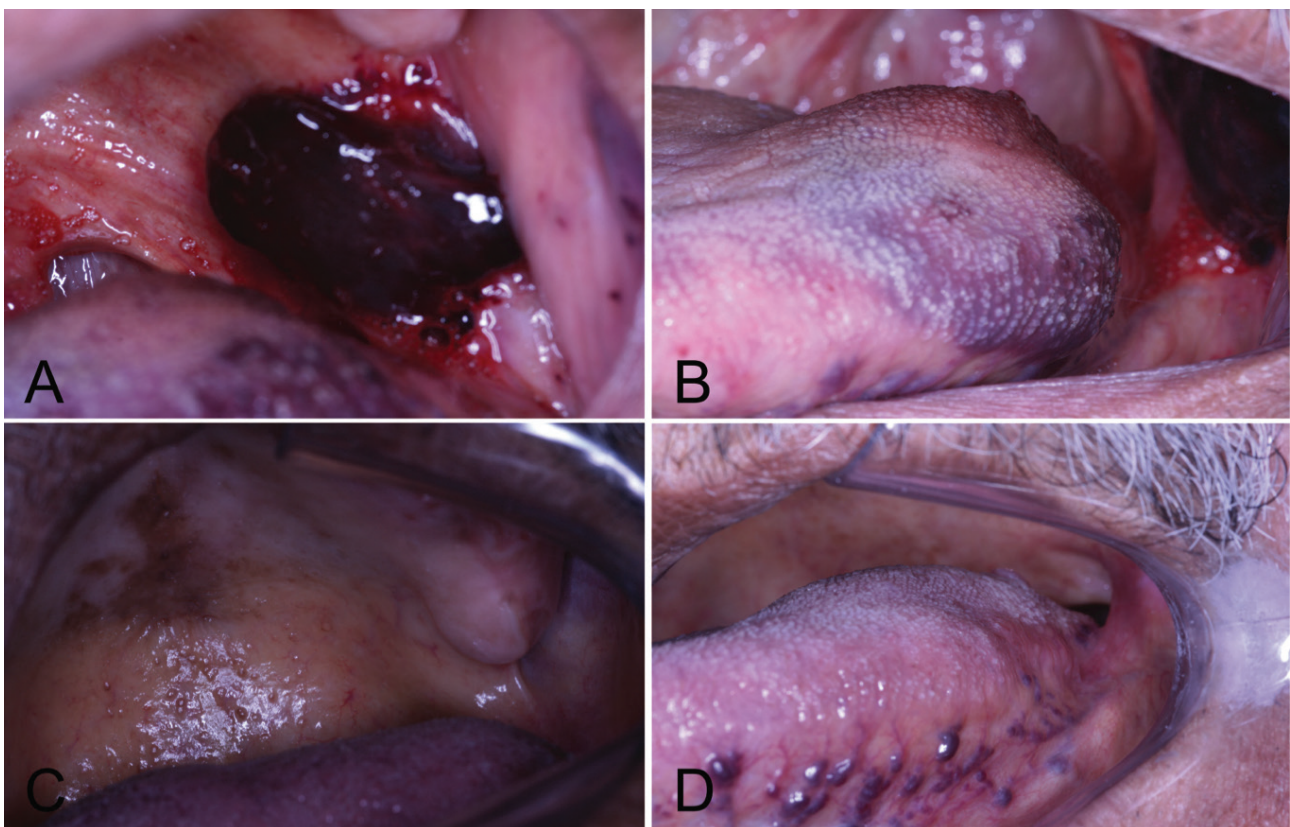


Figure 1 - Clinical appearance. A) Initial bleeding lesion on the soft palate. B) Initial nodular purple lesion on the left side of the tongue. C) After 1 week of treatment on the soft palate. D) After 1 week of treatment on the tongue.

DISCUSSION

The use of warfarin requires rigorous control of its action in plasma. This control is performed by the measurement of prothrombin time and activity and INR [5,6]. Excessive doses can lead to an imbalance in the coagulation cascade and consequent local and systemic hemorrhage at invisible sites of difficult access, including the brain and joints, putting the patient's life at risk [7]. Sublingual and retropharyngeal hematomas are uncommon [5,6,8]. Bleeding in these regions is life-threatening because it can obstruct the upper airways [5,8] and can cause brain damage due to anoxia and death if not treated in a timely manner [9].

Some factors can potentiate the action of oral anticoagulants, such as drug interactions, chronic alcohol consumption and diet [5,10]. Older adults are more susceptible to spontaneous bleeding since they generally use different drugs for the control of comorbidities. This was the case of the present patient who reported abusive alcohol consumption and chronic tobacco use. Warfarin, alcohol and tobacco are all metabolized through the hepatic cytochrome P450 (CYP) enzyme system [10,11]. Smoking can increase the clearance of warfarin, reducing the effects of the drug [11]. On the other hand, alcohol consumption can increase the free fraction of the drug available for clinical activity [10]. In this report, the patient was taking salicylate, which raises blood alcohol levels by inhibiting the action of alcohol dehydrogenase, preventing oxidation to acetaldehyde in the stomach [12].

The patient was treated with vitamin K as recommended in the literature [5,6]. Hematoma drainage has also been suggested [9]. However, in the present case in which bleeding compromised the intrinsic tongue muscles, the choice was to wait for spontaneous resolution

of the lesion, which occurred after 1 week of follow-up. Another important approach is the adjustment of the dose regimen and follow-up based on hematocrit, INR, clotting time, and prothrombin activity.

Dentists should be familiar with the side effects of oral anticoagulants, which are uncommon in the oral cavity, but can be life-threatening if diagnosed late or inaccurately.

REFERENCES

1. Connolly BJ, Pearce LA, Hart RG. Vitamin K antagonists and risk of subdural hematoma: meta-analysis of randomized clinical trials. *Stroke*. 2014 Jun;45(6):1672-8. doi: 10.1161/STROKEAHA.114.005430.
2. Crispian S, Wolff A. Oral surgery in patients on anticoagulant therapy. *Oral Surg Oral Med Oral Pathol Oral Radiol Endod*. 2002 Jul;94(1):57-64.
3. Timson DJ. Dicoumarol: A Drug which Hits at Least Two Very Different Targets in Vitamin K Metabolism. *Curr Drug Targets*. 2017;18(5):500-10. doi: 10.2174/1389450116666150722141906.
4. Mendonca S, Gupta D, Valsan A, Tewari R. Warfarin related acute kidney injury: A case report. *Indian J Nephrol*. 2017 Jan-Feb;27(1):78-80. doi: 10.4103/0971-4065.177142.
5. Bloom DC, Haegen T, Keefe MA. Anticoagulation and spontaneous retropharyngeal hematoma. *J Emerg Med*. 2003 May;24(4):389-94.
6. Pathak R, Supplee S, Aryal MR, Karmacharya P. Warfarin induced sublingual hematoma: a Ludwig angina mimic. *Am J Otolaryngol*. 2015 Jan-Feb;36(1):84-6. doi: 10.1016/j.amjoto.2014.08.008.
7. Lee SM, Park HS, Choi JH, Huh JT. Location and characteristics of warfarin associated intracranial hemorrhage. *J Cerebrovasc Endovasc Neurosurg*. 2014 Sep;16(3):184-92. doi: 10.7461/jcen.2014.16.3.184.
8. de Moraes HH, de Santana Santos T, Camargo IB, de Holanda Vasconcellos RJ. Sublingual hematoma after usual warfarin dose. *J Craniofac Surg*. 2013;24(5):1858-9. doi: 10.1097/SCS.0b013e3182997ca0.
9. Rosenbaum L, Thurman P, Krantz SB. Upper airway obstruction as a complication of oral anticoagulation therapy. Report of three cases. *Arch Intern Med*. 1979 Oct;139(10):1151-3.
10. Havrda DE, Mai T, Chonlahan J. Enhanced antithrombotic effect of warfarin associated with low-dose alcohol consumption. *Pharmacotherapy*. 2005 Feb;25(2):303-7.
11. Nathisuwan S, Dilokthornsakul P, Chaiyakunapruk N, Morarai T, Yodting T, Piriyaachanusorn N. Assessing evidence of interaction between smoking and warfarin: a systematic review and meta-analysis. *Chest*. 2011 May;139(5):1130-9. doi: 10.1378/chest.10-0777.
12. Weathermon R, Crabb DW. Alcohol and medication interactions. *Alcohol Res Health*. 1999;23(1):40-54.

**Estela Kaminagakura
(Corresponding address)**

Av. Eng. Francisco José Longo 777,
São José dos Campos, SP, Brazil
+55 12 39479000

Date submitted: 2016 Feb 09

Accept submission: 2017 Sep 09