



Metallic frames of removable partial denture: a planning proposal

Armações Metálicas de Próteses Parciais Removíveis: Proposta de Planejamento

Rodrigo Lorenzi POLUHA¹, Flávia Fonseca Carvalho SOARES², Giancarlo De la Torre CANALES¹

1 – Department of Prosthodontics – Bauru School of Dentistry – University of São Paulo – Bauru – SP – Brazil.

2 – Department of Biological Sciences – Bauru School of Dentistry – University of São Paulo – Bauru – SP – Brazil.

ABSTRACT

Objective: Removable partial denture (RPD) is an important oral rehabilitation resource with an acceptable result even over a very long observation period. However, it is still difficult for many clinicians to make an appropriate RPD. One of the main causes of RPD failure is the missing or incorrect planning of the metal frame. Perhaps, this lack of planning occurs because of the difficulty that clinicians have to choose the components for the metallic frame among the enormous number of possibilities that exist. Thus, the present article aims to propose a simple sequence for the planning of metallic frames of the RPD following five steps: I) Classification of partially edentulous arches; II) Choice of the retainer (direct and indirect, when needed); III) Saddle drawing; IV) Choice of the major connector; and, V) Minor connector drawing.

KEYWORDS

Dental prosthesis; Planning; Removable partial denture.

RESUMO

Objetivo: A prótese parcial removível (PPR) é um importante recurso na reabilitação oral, apresentando resultados aceitáveis mesmo durante um longo período de acompanhamento. No entanto, ainda é difícil para muitos clínicos fazer uma PPR apropriada. Uma das principais causas de falha em PPR é o planejamento ausente ou incorreto da estrutura metálica. Possivelmente, essa deficiência no planejamento ocorra devido à dificuldade na escolha dos componentes para a armação metálica entre o enorme número de possibilidades existentes. Assim, o presente artigo tem como objetivo propor uma sequência simples para o planejamento de armações metálicas de PPR seguindo cinco etapas: I) Classificação de arcos parcialmente desdentados; II) Escolha do retentor (direto e indireto, quando necessário); III) Desenho de sela; IV) Escolha do conector maior; e, V) Desenho do conector menor.

PALAVRAS-CHAVE

Prótese dentária; Planejamento; Prótese parcial removível.

INTRODUCTION

The prevalence of partial edentulism is already estimated greater than 20% in some world regions [1]. Those kinds of patients certainly require replacement of missing teeth and associated structures in order to enhance appearance, improve masticatory efficiency, prevent unwanted movement of teeth (overeruption/drift), and/or improve phonetics [2]. Removable partial denture (RPD) is an important prosthetic option

for oral rehabilitation for partially edentulous patient [3, 4]. Depending on geographic location and socioeconomic conditions, it is estimated that approximately 13% to 29% of adult patients use RPD [5]. That kind of dental prosthesis shows acceptable results even over long observation periods (25 years) [6].

RPD presents some advantages over other rehabilitation procedures which keep RPD consolidated within a social and professional context, such as: cost/benefit ratio; little teeth

structure wear; easy maintenance compared to other types of prosthesis; efficient solution for mechanically difficult situations to solve; and, versatility [7,8]. However, it is still difficult for many clinicians to make an appropriate and functional RPD [9]. In addition, a study showed that about 70% of the RPDs had some type of defect [10]. One of the main causes of RPD failure is the incorrect planning of the metal frame, which leads to unsatisfactory retention, instability and incurring impairment to the teeth and soft tissues [11-13]. The metallic frame of the RPD is usually composed of: retainer (direct and indirect, when needed), major connector, minor connector and saddle [14,15].

Previous studies showed that only 9.1%-23.4% of the clinicians send the planning of the metallic frame to the dental prosthetics laboratory [16,17]. Perhaps, this lack of planning occurs because of the difficulty that clinicians have to choose the components for the metallic frame among the enormous number of possibilities that exist. Thus, the present article aims to propose a simple sequence for the planning metallic frames of the RPD, which would allow the resolution of the vast majority of cases, therefore facilitating the correct planning for the clinician.

PLANNING PROPOSAL

The planning of the metallic frame of the RPD should follow five steps (Figure 1): 1) Classification of partially edentulous arches; 2) Choice of the retainer (direct and indirect, when needed); 3) Saddle drawing; 4) Choice of the major connector; and, 5) Minor connector drawing.

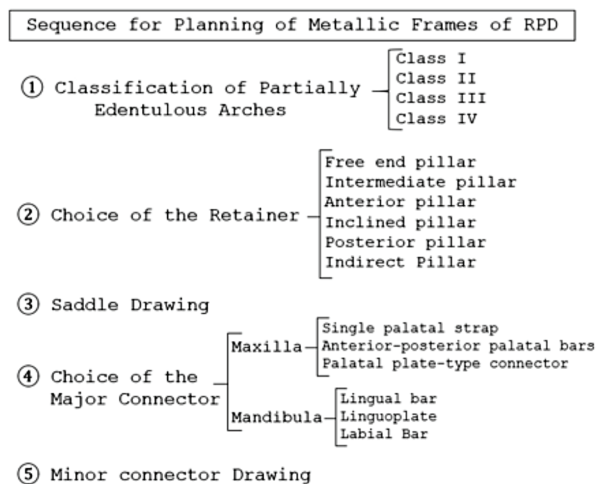


Figure 1 - Sequence for Planning of Metallic Frames of Removable Partial Denture (RPD).

1) Classification of partially edentulous arches

The partially edentulous arches can be grouped under four different categories [18]: Class I (bilateral free ended partially edentulous); Class II (unilateral free ended partially edentulous); Class III (unilateral bounded posterior, there is no free-end); Class IV (bilateral bounded anterior partially edentulous). This classification should be done considering the following rules [19]: The most posterior area always determines the classification; The absence of molars should only be considered as a determinant of classification if they will be replaced by the prosthesis; Modifications are edentulous spaces beyond of those who characterize the class; There can be no modification areas in Class IV arches.

2) Choice of the retainer

Retainers are the components of an RPD used to retain and prevent dislodgement [14]. The retainers can be direct (adjacent to the prosthetic space) or indirect (distant from prosthetic space). All direct retainers must have a clasp. In a partially edentulous arch, the tooth can be group hierarchically in 6 categories (being the first five composed by direct retainers). It is important to follow a sort order since a tooth may be within more than one category and should prevail whichever comes first. In each category a specific type of retainer can be used [7]. In this proposal, only extracoronal retainers will be utilized. The retainer choice is made after the analysis performed on the delineator in order to determine the insertion trajectory, guide planes, retentive areas and the adjustment of the prosthetic equator [3]:

1) Free end pillar: It is the last teeth of the arch, next to a free end that will be rehabilitated. In this type of pillar, it should be used an RPI (rest proximal plate I bar) clasp. Depending on the case, variations of Bar/Roach clasp (T, U, Y, 7) can be used. The occlusal rest should be put on the opposite side of the free end (usually, on the mesial surface of the teeth) [3,20] (Figure 2).

2) Intermediate pillar: Isolated teeth between two prosthetic spaces to be rehabilitated.

In this situation, should be used an Ottolengui clasp. In this scenario, the occlusal rest should be put next to prosthetic spaces on both sides [3,7] (Figure 3).

3) Anterior pillar: Anterior teeth next to a prosthetic space. In this situation, should be used an I - Bar clasp. For the cingulum rest, an enamel preparation should be done [3,7,15] (Figure 4).

4) Inclined pillar: It is usually a tooth that has lost the adjacent element and tilted into the prosthetic space. In this situation, should be used a Ring clasp. It is important to use two occlusal rest to help transmit the forces axially [3,7] (Figure 5).

5) Posterior pillar: They are usually molars and/or premolars delimiting a segment edentulous in arches class II, III and IV. In this situation, should be used a Circumferential/

Akers clasp. The occlusal rest should be put next to prosthetic spaces [3,7,15] (Figure 6).

6) Indirect Pillar: Is the component of an RPD, not adjacent to the prosthetic space, which that assists the direct retainer(s) in preventing displacement of the distal-extension denture base. This component works through lever action on the opposite side of the fulcrum line, when the denture base attempts to move away from the tissues in pure rotation around the fulcrum line [21]. Thus, the main function of the indirect pillar is to neutralize the fulcrum line in arches class I, II and IV. Class III the fulcrum line is non-existent. The indirect pillar should be put on as far as possible of the prosthetic space and at approximately 90° degrees with the fulcrum line. As an indirect pillar, there are Occlusal rest, Embrasure clasp, and, in the mandibular arch, the Continuous clasp [3,7] (Figure 7).

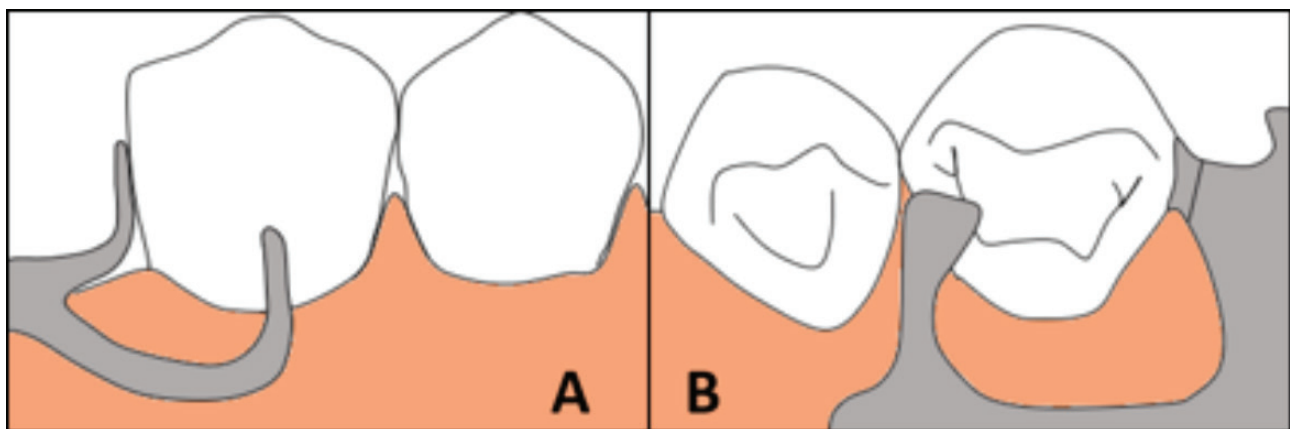


Figure 2: Free end pillar with an RPI clasp. A: Buccal view, B: Occlusal view, note the occlusal rest distant from the free end.

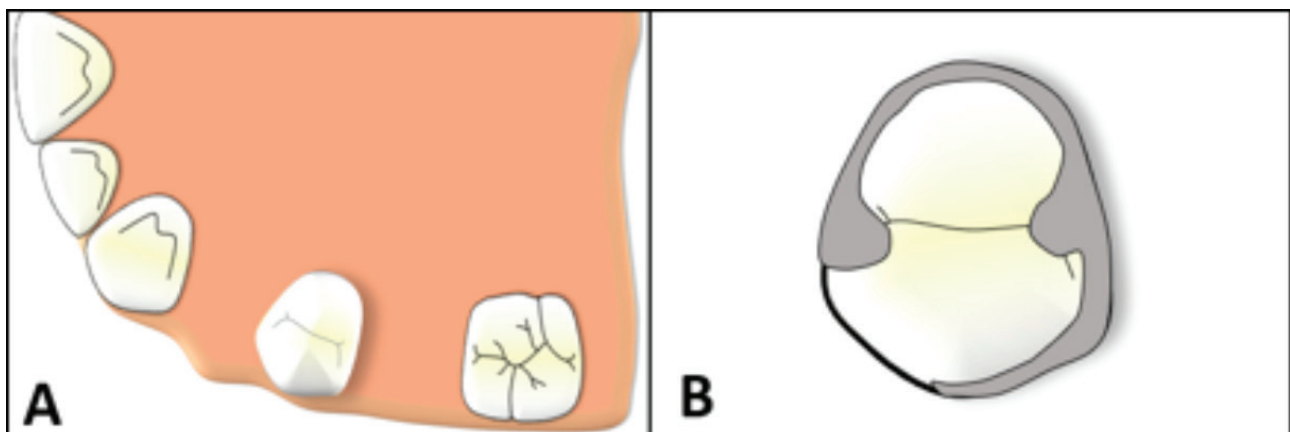


Figure 3: Intermediate pillar. A: Premolar between two prosthetic spaces. B: Ottolengui clasp with two occlusal rest next to prosthetic spaces.

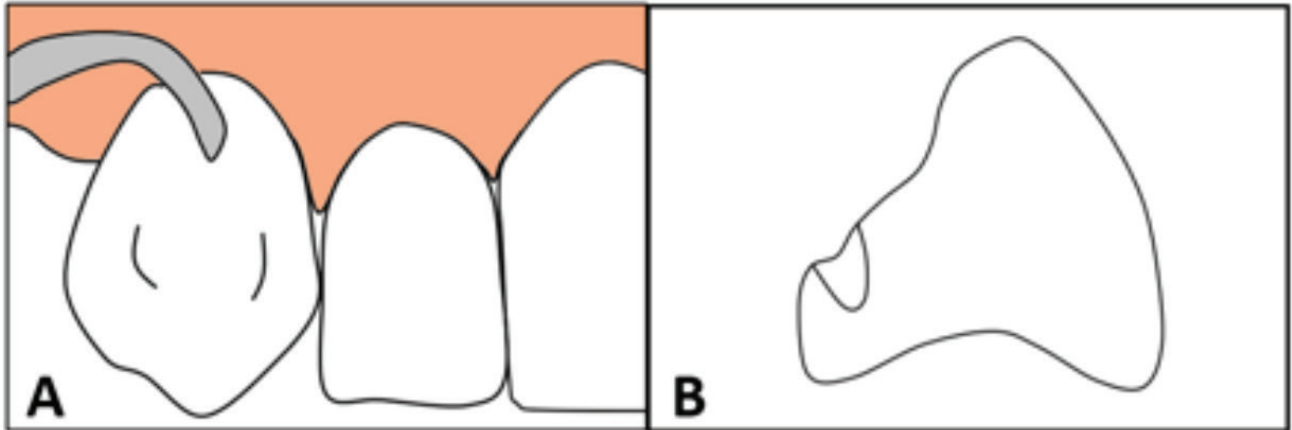


Figure 4: Anterior pillar. A: I - Bar clasp. B: Enamel preparation for cingulum rest.

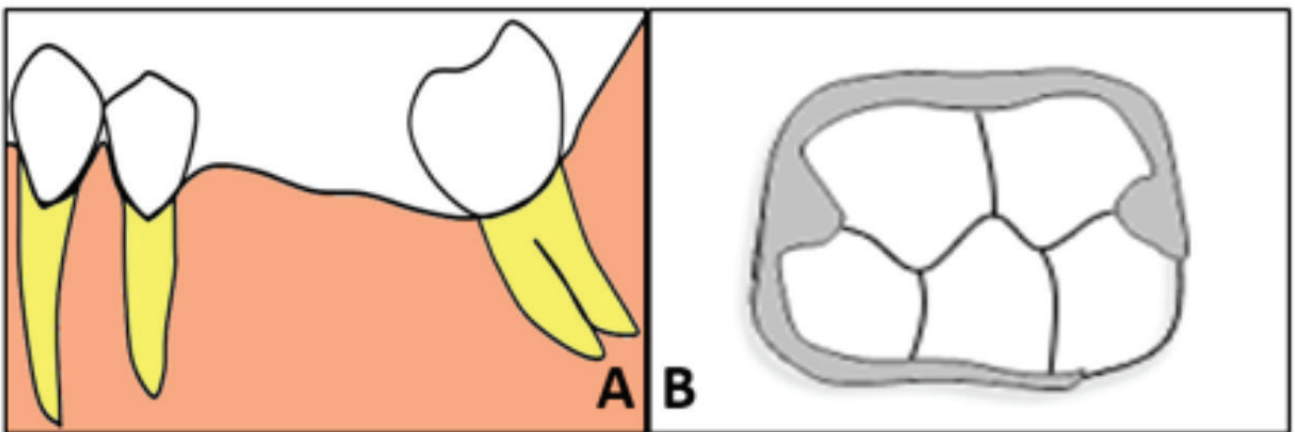


Figure 5: Inclined pillar. A: Mesialized lower molar. B: Ring clasp with two occlusal rest.

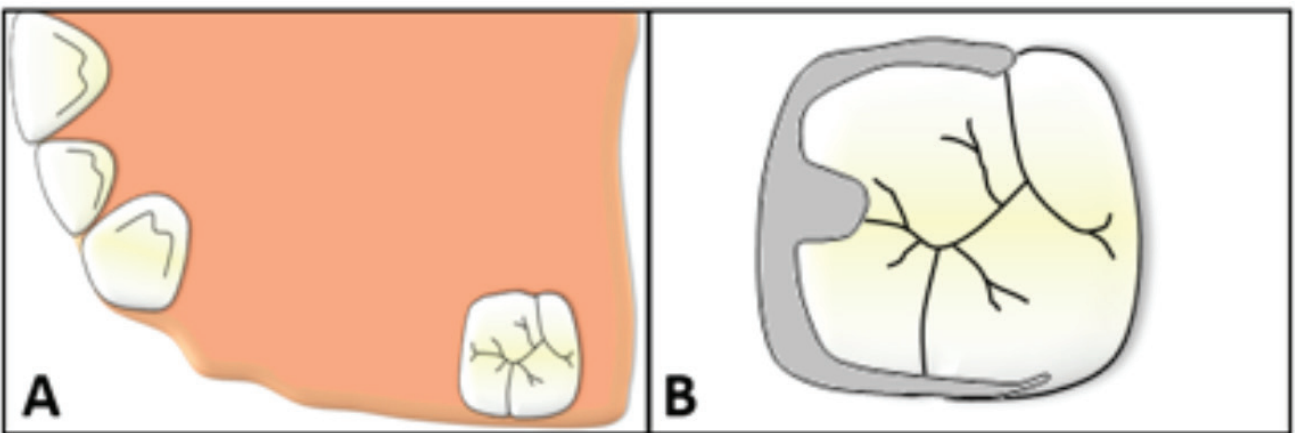


Figure 6: Posterior pillar. A: Molar is the last tooth of the segment edentulous. B: Circumferential/Akers clasp with occlusal rest next to prosthetic space.

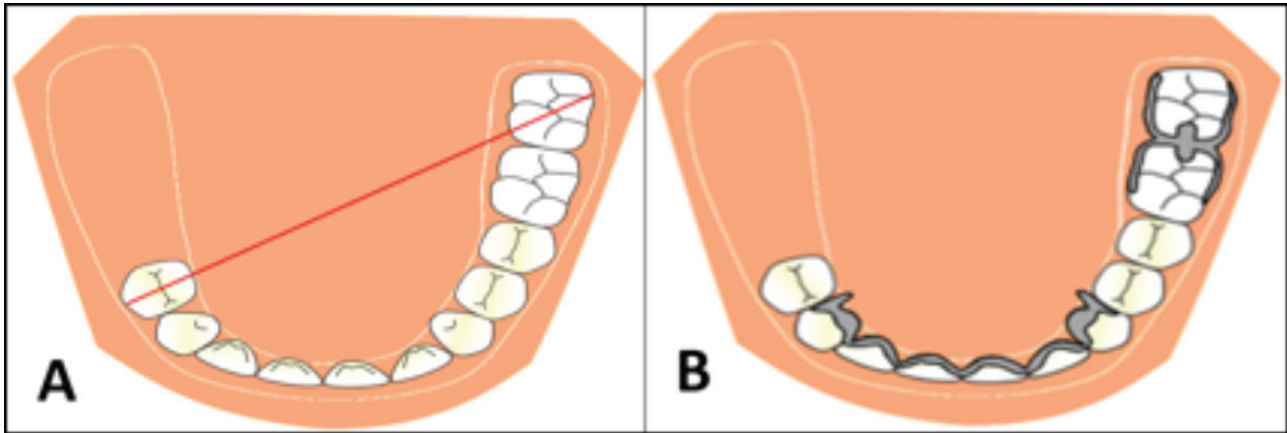


Figure 7: Indirect pillar. A: Arch class II, fulcrum line drawn (red line). B: Continuous clasp and Embrasure clasp, neutralizing the fulcrum line.

3) Saddle drawing

Saddle is the part of the metal frame that will fill the prosthetic spaces and support the resin base and artificial teeth. The saddle will artificially reconstruct the tissues altered by tooth loss, aiding in the transmission of masticatory forces, avoiding the food impaction and favouring the phonetics. The saddle should be drawing only in the prosthetic spaces that will be rehabilitated.

4) Choice of the major connector

A major connector is the metal frame component that connects the parts of the prosthesis located on one side of the arch with those on the opposite side. It is a unit to which all other parts are directly or indirectly attached. The choice, the designer, and the location of the major connector should be based on these rules: These connectors must be rigid and provide cross-arch stability through the principle of broad distribution of stress; Do not interfere with and are not irritating to the tongue, gingival tissue, and bony and soft tissue prominences; Do not cover more tissue than is absolutely necessary; and, Minimize food impaction [22].

In short, for the maxillary arch, the main types are [3,23]: Single palatal strap (in class III arch); Anterior-posterior palatal bars (in class I, II and VI arches; in inoperable palatal tori cases); and, Palatal plate-type connector (in most situations in which there are only a few remaining teeth and greater palatal support is required).

For the mandibular arch, the main types are [3,24]: Lingual bar (can be used in all class); Linguoplate (when there is no sufficient space for lingual bar between the marginal gingiva and the activated lingual frenum and of the mouth); and, Labial Bar (when an extreme lingual inclination of the remaining lower teeth prevents the use of a lingual bar major connector or there is an inoperable mandibular tori).

5) Minor connector drawing.

Minor connectors are components that serve to connect retainers and the saddle to the major connector, integrating the entire prosthesis. Also, it helps to transfer functional stress to the support tooth and to the major connector and can assist in the retention, the stability and guide the insertion of the RPD. The minor connectors should be drawing from the components toward the major connector.

CONCLUSION

This planning proposal expects be able to assist clinicians in the elaboration of metallic frames of the RPD. Of course, there are a lot of components that were not addressed such as the intracoronary retainers and other major connectors, since they are employed in only a small number of situations. In more complex cases, the biomechanical factor may ask for a more elaborate planning of the case to avoid factors such as the formation of levers around

the fulcrum, inclined planes, premature occlusal contacts in the supporting teeth and bone resorption in the residual ridge, factors that may be unfavourable to treatment success. Thus, each case should be evaluated individually and with caution. However, following this planning proposal, clinician could design in a simple and rational way the vast majority of the RPD cases.

REFERENCES

- Cooper LF. The current and future treatment of edentulism. *J Prosthodont*. 2009 Feb;18(2):116-22. doi: 10.1111/j.1532-849X.2009.00441.x.
- Campbell SD, Cooper L, Craddock H, Hyde TP, Nattress B, Pavitt SH, et al. Removable partial dentures: The clinical need for innovation. *J Prosthet Dent*. 2017 Sep;118(3):273-280. doi: 10.1016/j.prosdent.2017.01.008. Epub 2017 Mar 23.
- Carr A, Brown D. *McCracken's Removable Partial Prosthodontics*. 13th ed. Elsevier; Saint Louis: 2017.
- Bohnenkamp DM. Removable partial dentures: clinical concepts. *Dent Clin North Am*. 2014 Jan;58(1):69-89. doi: 10.1016/j.cden.2013.09.003.
- Zitzmann NU, Hagmann E, Weiger R. What is the prevalence of various types of prosthetic dental restorations in Europe? *Clin Oral Implants Res*. 2007 Jun;18 Suppl 3:20-33.
- Moldovan O, Rudolph H, Luthardt RG. Clinical performance of removable dental prostheses in the moderately reduced dentition: a systematic literature review. *Clin Oral Investig*. 2016 Sep;20(7):1435-47. doi: 10.1007/s00784-016-1873-5. Epub 2016 Jun 9.
- Bonachela WC, Telles D. *Planning in Oral Rehabilitation with Removable Partial Prosthesis*. 1st ed. São Paulo; Santos: 1998.
- Jones JD, Turkyilmaz I, Garcia LT. Removable partial dentures--treatment now and for the future. *Tex Dent J*. 2010 Apr;127(4):365-72.
- Franceschini Jr L, Rizatti-Barbosa CM, Ambrosano GMB, Darugue Jr E, Fernandes MM, Santos LSM. Dentist's knowledge on quality evaluation of partial removable dentures and the responsibility related to their manufacturing and installation. *Saúde, Ética & Justiça*. 2009;14(1):9-16.
- Hummel SK, Wilson MA, Marker VA, Nunn ME. Quality of removable partial dentures worn by the adult U.S. population. *J Prosthet Dent*. 2002 Jul;88(1):37-43.
- Benso B, Kovalik AC, Jorge JH, Campanha NH. Failures in the rehabilitation treatment with removable partial dentures. *Acta Odontol Scand*. 2013 Nov;71(6):1351-5. doi: 10.3109/00016357.2013.777780. Epub 2013 Jul 9.
- Moldovan O, Rudolph H, Luthardt RG. Biological complications of removable dental prostheses in the moderately reduced dentition: a systematic literature review. *Clin Oral Investig*. 2018 Sep;22(7):2439-2461. doi: 10.1007/s00784-018-2522-y. Epub 2018 Jun 29.
- Witter D, Barèl JC, Keltjens HM, Creugers NH. Designing metal frame removable partial dentures. *Ned Tijdschr Tandheelkd*. 2011 Feb;118(2):79-87.
- Aloña G Jr. Essentials of removable partial denture prosthesis. *J Philipp Dent Assoc*. 1974 Dec-1975 Mar;21-22(4-1):14-28.
- McCord JF, Grey NJ, Winstanley RB, Johnson A. A clinical overview of removable prostheses: 3. Principles of design for removable partial dentures. *Dent Update*. 2002 Dec;29(10):474-81.
- Torres EM, Rocha SS, Carvalho MA, Maffra PET, Costa RF. Avaliação do planejamento para prótese parcial removível e da qualidade dos modelos e requisições enviados aos laboratórios. *Rev Odontol Bras Central*. 2011;20(52):25-30.
- Batista AUD, Sales JPLA, Neto AF, Carreiro ADFP. Evaluation of the Planning of Removable Partial Denture in Plaster Models Received from Prosthodontic Laboratories of the City of João Pessoa, PB, Brazil. *Pesq Bras Odontoped Clin Integr*. 2011;11(1):53-58.
- Kennedy E. *Partial denture construction*. New York: Dental Items of Interest Publishing Co; 1928.
- Applegate OC. Clasificación. In: *Elementos de prótesis de dentaduras parciais removíveis*. Buenos Aires: Ed Bibliográfica Argentina; 1959.
- Krol AJ. RPI (rest, proximal plate, I bar) clasp retainer and its modifications. *Dent Clin North Am*. 1973 Oct;17(4):631-49.
- Glossary of Prosthodontic Terms Committee of the Academy of Prosthodontics (GPT). The Glossary of Prosthodontic Terms. *J Prosthet Dent*. 2017;117(5S):e1-e105.
- Itoh H, Baba K, Aridome K, Okada D, Tokuda A, Nishiyama A, et al. Effect of direct retainer and major connector designs on RPD and abutment tooth movement dynamics. *J Oral Rehabil*. 2008 Nov;35(11):810-5. doi: 10.1111/j.1365-2842.2008.01868.x. Epub 2008 May 9.
- Arigbede AO, Dosumu OO, Esan TA, Akeredolu PA. Acceptability of maxillary major connectors in removable partial dentures. *Afr Health Sci*. 2006 Jun;6(2):113-7.
- Satheesh Kumar KS, Preeti SK, Savadi R, Patel R, Vinod V, John J. Deflections in Mandibular Major Connectors: A FEM Study. *J Indian Prosthodont Soc*. 2013 Dec;13(4):560-70. doi: 10.1007/s13191-012-0191-0. Epub 2012 Oct 30.

Rodrigo Lorenzi Poluha (Corresponding address)

Department of Prosthodontics, Bauru School of Dentistry,
University of São Paulo
Al. Octávio Pinheiro Brisola, 9-75.
CEP 17012-901 Bauru, SP, Brazil
E-mail: rodrigopoluha@gmail.com

Date submitted: 2018 Jul 20

Accept submission: 2018 Sep 27