



Assessment of Mesial Canals Morphology of Mandibular First Molars Using CBCT: An In-vitro Study

Avaliação da morfologia dos canais mesiais dos primeiros molares inferiores usando TCCB: um estudo in vitro

Eyhaa Siddig ALAGEB¹, Abbas G. ABDULLAH², Asim Alsadig SATII³, Salma Amin ELSAYED¹

1 - Department of Conservative Dentistry – Faculty of Dentistry – University of Khartoum – Khartoum – Sudan.

2 - Department of Basic Sciences - Faculty of Dentistry - University of Khartoum - Khartoum – Sudan.

3 - Department of Researches and Informatics - Khartoum Teaching Dental Hospital - Khartoum – Sudan.

ABSTRACT

Objective: The current study aimed to investigate the relationship between canal configuration, distance between mesiobuccal (MB) and mesiolingual (ML) orifices and the degree of canals curvature in the mesial root of permanent mandibular first molars in a sample of Sudanese population using cone-beam computed tomography (CBCT). **Material and Methods:** A total of 143 extracted mandibular first molars were processed and scanned with CBCT to determine the configuration of the mesial root canals according to the Vertucci classification. The interorifical distance and the degree of canal curvature in clinical (CV) and proximal (PV) views using Schneider technique were assessed. **Results:** The commonest canal configuration was type IV (53.1%). The interorifical distance was significantly shorter in type VI compared to other types ($P < 0.05$). Significant association was found for type IV between the MB and ML canal in the primary curvature regarding CV and PV, and for type II regarding PV in primary and secondary curvature ($P < 0.05$). In type IV the degree of secondary curvature of MB canal regarding PV, and in the ML canal in CV was significantly lower compared to other types ($P < 0.05$). Significant correlation was seen in PV of primary curvature in the MB for type VI ($P < 0.05$). **Conclusion:** The interorifical distance and secondary curvatures in CV for MB canal were found to be key factors for predicting root canal patterns in PV.

KEYWORDS

Canal morphology; Canal curvature; Interorifical distance; Mandibular molars.

RESUMO

Objetivo: O presente estudo teve como objetivo investigar a relação entre a configuração do canal, a distância entre os orifícios de entrada dos canais mesiovestibular (MB) e mesiolingual (ML) e o grau de curvatura dos canais na raiz mesial dos primeiros molares inferiores permanentes em uma amostra da população sudanesa usando tomografia computadorizada cone-beam (TCCB). **Material and Methods:** Um total de 143 primeiros molares inferiores extraídos foram processados e escaneados com TCCB para determinar a configuração dos canais radiculares mesiais de acordo com a classificação de Vertucci. A distância inter orifícios e o grau de curvatura do canal nas vistas clínica (CV) (acredito que a tradução seja essa mesma, seria como uma foto intra oral clínica/perguntei a um endodontista, mas não soube me responder) e proximal (PV) usando a técnica de Schneider foram avaliados. **Resultado:** A configuração mais comum do canal foi do tipo IV (53,1%). A distância inter-orifícios foi significativamente menor no tipo VI em comparação com outros tipos ($P < 0,05$). Associação significativa foi encontrada para o tipo IV entre o canal MB e ML na curvatura primária em relação à CV e PV, e para o tipo II em relação à PV na curvatura primária e secundária ($P < 0,05$). No tipo IV, o grau de curvatura secundária do canal MB em relação à PV e no canal ML na CV foi significativamente menor em comparação com outros tipos ($P < 0,05$). Correlação significativa foi observada na PV da curvatura primária no MB para o tipo VI ($P < 0,05$). **Conclusão:** A distância inter orifícios e as curvaturas secundárias na CV para o canal MB foram consideradas fatores-chave na predição dos padrões do canal radicular na PV.

PALAVRAS-CHAVE

Morfologia do canal; Curvatura do canal; Distância inter orifícios; Molares inferiores.

INTRODUCTION

Endodontic treatment is generally done through biomechanical instrumentation, chemical debridement, followed by hermetic obturation of the root canal system [1]. A good understanding of human root canal anatomy and morphology is desirable for performing a successful endodontic procedure. Variations in the morphology of the dental pulp are caused by genetic and environmental influences, hence there is very definite need for clinicians to be made aware of the frequency of racially determined forms [2]. Curved narrow root canals pose difficulties in cleaning and shaping [3,4] with documented increased risk of instrument breakage [5], canal transportation, zipping, ledging, and root perforations [4]. Mandibular first molar is a common endodontically treated tooth due to its early eruption in the oral cavity. It has a complex anatomy, and a lot of varieties in the morphology and configurations of the mesial canals, which may affect the outcome of endodontic treatment [6]. Moreover, the anatomical complexity of the root canal system of mandibular first molar roots, and organization of the flora as biofilms in inaccessible areas of the canal system presents, difficulties in which instrumentation and irrigation alone are hard to achieve [7]. This might strongly implicate that well-built knowledge of root morphology will positively impact the quality of treatment [8], and also essential to determine the most appropriate method for instrumentation and obturation as some types might present challenges in both aspects [9-12].

Successful management of endodontic problems is reliant on diagnostic imaging techniques and together with a thorough clinical exploration of the interior and exterior of the tooth [13] to provide critical information about the teeth under investigation, and their surrounding anatomy [14]. There are several other methods which are mostly designed in non-clinical settings to observe and study the internal anatomy of dental roots and canals system. Examples are: Canal staining and tooth clearing, plastic resin injection, sectioning, in vitro macroscopic examination, in vivo root canal therapy with magnification,

scanning electron microscopy evaluation, computed tomography (CT) techniques, micro-CT, and cone beam CT (CBCT) [11]. Cone-beam computed tomography (CBCT) has been used successfully in morphological root canal analyses for both clinical settings as well as in the intention for studying, it has proven to be a practical tool for non-invasive and three-dimensional reconstructive imaging [15]. The ability of CBCT to reduce or even, eliminate the superimposition of the surrounding structures makes it superior to conventional apical films and digital ones [14,16]. When compared with conventional medical CT, CBCT, it allows less scan time, a lower radiation dose and an adequate accuracy of the imaging along with high resolution [16]. There is still a lack of information among Sudanese population about the interorificial distance between the mesial canals and its relationships with the morphology and configuration of these canals using CBCT technology. In the current study an attempt was made to 1) investigate the configuration of the mesial canals of mandibular first molar according to Vertucci classification, 2) measure canal curvatures of the mesial canals in mandibular first molars according to Schneider technique, 3) measure the distance between mesiobuccal (MB) and mesiolingual (ML) canal orifices (interorificial distances) in the pulp chamber floor in mandibular first molar, and 4) to find out if there is a relationship between these variables.

MATERIAL AND METHODS

Teeth preparation

A total of 554 human extracted mandibular first molars were collected. Teeth included in this study were selected according to the following criteria: permanent mandibular first molars with intact roots and fully formed apices. On the other hand, teeth with root fracture, root canal filings, posts, and crown restorations and teeth with signs of root resorption were excluded from the study. After exclusion of teeth that did not comply with the study prerequisites the final sample size was 143 mandibular first molars. The extracted teeth were disinfected with 5% sodium hypochlorite for 30 minutes, and adherent tissue and cementum were

removed with the use of curettes. Subsequently, teeth were stored in 10% formalin water until use. In order to homogenize and stabilize the specimen's position, teeth were mounted in rose wax box shape (7X7cm). Every 20 teeth were mounted in one box and scanned by CBCT.

Measurements

Planmeca CBCT imaging machine was used (Planmeca, Helsinki, Finland). The analysis of the CBCT imaging was done using Planmeca Romexis software in a Dell Precision T5400 workstation (Dell, Round Rock, TX, USA), with a 32-inch HP LCD screen with a resolution of 1280 x 1024 pixels in a darkroom. The contrast and brightness of images were adjusted using the image processing tool in the software to ensure optimal visualization. Teeth were analyzed by using three planes (sagittal, axial, and coronal) with a slice thickness of 0.1 mm. Measurement of interorifical distance was done by measuring the distance between the mesiobuccal and the mesiolingual root canal orifices in the pulp chamber floor (Figure 1). Measuring the primary and secondary curvatures in the mesial canals in both clinical and proximal views was done according to the method described by Schneider [17] (Figure 2). Determining the canal configuration of the mesial root was done according to Vertucci classification [9].




Figure 1 - Measurement of the interorifical distance.

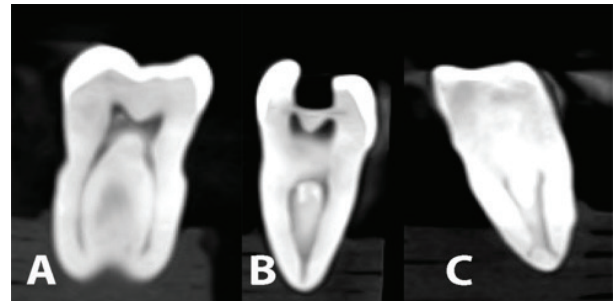


Figure 2 - Measurement of primary and secondary canal curvature.

Statistical analysis

To ensure precision of readings, inter-rater reliability test was performed on 10% of radiographs selected randomly and measured by two investigators. After two weeks, repeated measurements were performed by the same investigators and the agreement between readings was calculated using Intraclass Correlation Coefficient (ICC). The ICC value between readings of the first investigator was 0.986, between readings of the second investigator was 0.979, and between readings of both investigators was 0.977. All values were highly statistically significant ($P < 0.001$). Data were analysed using SPSS version 20 (IBM, Chicago, IL). In addition to the descriptive statistics, One-way ANOVA, and Pearson's Correlation Coefficient tests were performed to detect any significant results. P-value < 0.05 was considered significant.

RESULTS

Canal configuration and interorifical distance

Based on Vertucci classification, type IV was detected in more than half of the investigated samples (53.1%) (Figure 3-A), followed by Type II (37.1%) (Figure 3-B), and type VI was detected in 9.8 % of canals (Figure 3-C). The other types of canal configuration were not detected. The mean value of interorifical distance was 2.5 ± 0.45 mm for the whole tested groups. This distance was significantly ($P = 0.048$) shorter in type VI (2.2 ± 0.4 mm) compared to type II (2.4 ± 0.39 mm) and type IV (2.5 ± 0.51 mm) (Table I).

Table I - Mean values of interorificial distance by canal Configuration.

	N	Mean	SD
Type II	53	2.44	0.39
Type IV	76	2.54	0.51
Type VI	14	2.21	0.41
Total	143	2.47	0.47

One way ANOVA; P-value= 0.048.

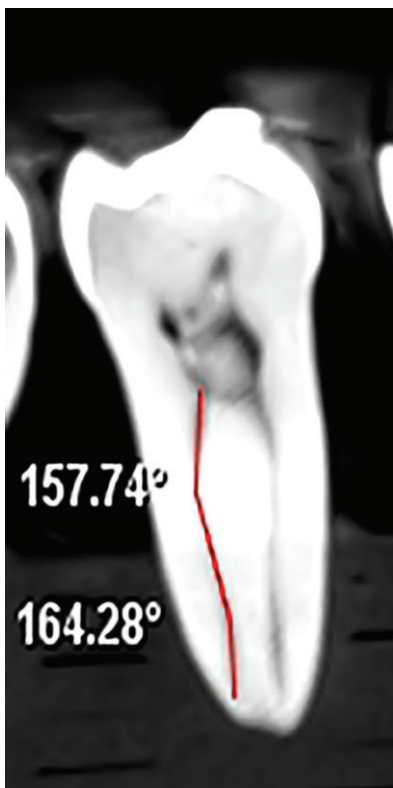


Figure 3 - Canal configuration according to Vertucci classification; A) Type IV, B) Type II, and C) Type VI.

All samples shown varying degrees of curvatures in both clinical and proximal views. Primary curvatures were shown in both clinical and proximal views in 100% of the samples. In the clinical view, the mean values of primary curvatures were 22.4 ± 13.4 and 21.9 ± 6.2 degrees for mesiobuccal and mesiolingual canals, respectively. Whereas in proximal view, the mean values of primary curvatures were 21.4 ± 6.8 and 21.7 ± 7.9

degrees for mesiobuccal and mesiolingual canals, respectively. Secondary curvature was seen more frequent in the clinical views for both mesiobuccal (32.9%) and mesiolingual (30.8%) canals than in proximal views (23.8% and 24.5% for mesiobuccal and mesiolingual canals, respectively). The mean values of secondary curvatures in clinical views for the whole sample were 25.1 ± 14.3 and 23.3 ± 10.6 degree for mesiobuccal and mesiolingual canals, respectively. In proximal views, the mean values of secondary curvatures were 22.7 ± 10.5 degree for mesiobuccal canals and 25.7 ± 11.7 degree for the mesiolingual for the whole sample. When the degree of curvature in CV and PV was related to canal configuration, the degree of the secondary curvature of mesiolingual canal in proximal views was significantly ($P= 0.003$) lower in type IV (19.9 ± 10.2 degree) than type II (30.1 ± 11.0 degree) and type VI (30.5 ± 11.7 degree). While, degree of secondary curvature in mesiobuccal canal for clinical view was significantly ($P= 0.003$) lower in type IV (18.99 ± 11.4 degree) compared to type II (25.9 ± 14.5 degree) and type VI (33.3 ± 14.7 degree). More details are illustrated in Table II.

Correlation between MB and ML canal for canal curvature

Statistically significant correlations were found between mesiobuccal canal and mesiolingual canal for primary curvature obtained in the proximal view for type IV ($r= 0.442$, $P= 0.001$) and type II ($r= 0.294$, $P= 0.033$). In the clinical view, for primary curvature, significant correlation ($r= 0.387$, $P= 0.001$) was found between mesiobuccal canal and mesiolingual canals for type IV only. For secondary curvature, a statistically significant correlation ($r= 0.735$, $P= 0.038$) was found between mesiobuccal canal and mesiolingual canals for type II in the proximal view. However, no statistically significant correlation was observed for type VI ($P > 0.05$) in curvature between mesiobuccal and mesiolingual canals for both primary and secondary curvatures in both clinical and proximal views (Table III).

Table II - Mean values of canal curvature of MB and ML in CV and PV.

		MB Canal				ML Canal			
		N	Mean	SD	P value	N	Mean	SD	P value
Primary curvature in CV	Type II	53	24.77	20.35	0.260	53	21.42	5.96	0.724
	Type IV	76	21.07	6.53		76	22.32	6.47	
	Type VI	14	20.46	4.39		14	21.90	6.09	
	Total	143	22.38	13.39		143	21.95	6.22	
Primary curvature in PV	Type II	53	22.49	5.41	0.270	53	21.22	7.72	0.417
	Type IV	76	21.06	7.96		76	22.50	8.18	
	Type VI	14	19.52	3.12		14	19.33	5.09	
	Total	143	21.44	6.77		143	21.72	7.78	
Secondary curvature in CV	Type II	16	25.87	14.53	0.030**	14	22.01	8.76	0.155
	Type IV	17	18.99	11.36		21	21.32	8.70	
	Type VI	11	33.31	14.72		12	28.40	14.20	
	Total	44	25.08	14.29		47	23.33	10.58	
Secondary curvature in PV	Type II	11	27.80	9.22	0.109	12	30.13	11.01	0.031**
	Type IV	17	19.31	8.54		15	19.89	10.16	
	Type VI	7	22.98	14.31		7	30.48	11.74	
	Total	35	22.71	10.47		34	25.68	11.69	

One way ANOVA; **P value is significant; MB: mesiobuccal canal; ML: mesiolingual canal; CV: clinical view; PV: proximal view

Table III - Correlation between MB and ML canal in CV and PV for Primary and secondary curvatures.

	Clinical View (CV)			Proximal View (PV)	
	N	Correlation	P value	Correlation	P value
Primary Curvature					
Type II	53	0.233	0.093	0.294	0.033**
Type IV	76	0.387	0.001**	0.442	0.001**
Type VI	14	0.393	0.165	0.454	0.103
Secondary Curvature					
Type II	13	-0.034	0.913	0.735	0.038**
Type IV	15	0.212	0.448	0.253	0.481
Type VI	11	0.416	0.203	0.535	0.274

**P value is significant; MB: mesiobuccal canal; ML: mesiolingual canal; CV: clinical view; PV: proximal view.

Correlation between canal curvature and interorifical distances:

On observing the correlation between the degree of curvature of the root canals in clinical and proximal views and interorifical distances, a negative significant correlation was found in proximal view of primary curvature in the mesiobuccal canal for type VI ($r = -0.627$, $P =$

0.016) only. No further significant correlation was found.

DISCUSSION

Knowledge of root canal morphology and degree of curvature are important factors for success in different stages of endodontic treatment [18]. It reduces the risk of procedural

errors like instrument breakage [5], canal transportation, zipping, ledging, and root perforations [4]. The technique of cone beam computed tomography, used in the current study has proven to be a practical tool for non-invasive, three-dimensional reconstructive imaging technique [15]. It is helpful in the detection of the anatomical details with more accuracy when compared to most techniques used [16,19]. However, it cannot be used for retains endodontic treatment due to it is high radiation dose, at the same time it is expensive compared to traditional periapical images, that why the current study trying to provide basic data to enhance the understanding of root canal morphology during root canal treatment. To the best of our knowledge, this is the first study among Sudanese population using CBCT technology to investigate the mesial canal morphology and interorifical distance in mandibular first molars.

Canal configuration and interorifical distance

In the present study, Vertucci type IV was found the most prevalent configuration type in mesial roots. This result is similar to that observed by Mukhaimer [20], de Pablo et al [1], and Kartal et al [21]. Ahmed et al in 2007 conducted a study among Sudanese population assessing the variations in the root canal systems of first permanent mandibular molar teeth using clearing technique. It was found a higher prevalence of Vertucci type IV in mesial canal [10]. The present study showed that type VI was observed in fewer number of the sample, which is consistent with previous finding of some studies [21,22]. However, these results might be different from that of Torres et al, who studied canal configurations in the Belgian and Chilean sample and found that Vertucci types V and III were the most prevalent canal configurations in the Belgian sample while, Vertucci types III, IV, and V were more frequent in the Chilean sample [23]. Moreover, in 2011, a study in Chinese population done by Zhang et al reported that type IV was the most frequent type followed

by type V [24]. Ethnic origin, sample size and methods used might play an important role in these contradictory findings [24].

In this study, the mean value of interorifical distance in Vertucci type VI was significantly the shortest compared to other types. This is not comparable concerning with the findings of the study done by Cimilli et al who reported the shortest interorifical distance in Vertucci type II compared to Vertucci type IV [4]. Karaman et al stated that the mean interorifical distance in both maxillary first and second molars was significantly longer in type III Weine classification (type IV canal configuration in Vertucci classification) when compared with type II Weine classification (type II canal configuration in Vertucci classification) [25]. The measurement of the distance between two mesial canals orifices in the mandibular first molars could provide clinician with predictive factor for the occurrence of what type of canal configurations may be found; which help clinician to decide or modify the biomechanical preparation to eliminate transportation, ledging, or fracture of the instruments during endodontic therapy.

Correlation between MB and ML canal for canal curvature

When assessing the correlation of primary curvature between mesiobuccal and mesiolingual canals, a significant correlation was observed in the clinical view for Vertucci type IV only. This is partially in agreement of the study done by Cimilli et al [4], who found significant correlations between MB and ML in CV for Vertucci type II and IV. This correlation demonstrated the direct relationship in degree of curvature between the mesiobuccal and mesiolingual canals when viewed from a clinical radiograph where the increase in primary curvatures in MB canal provide a predictive factor for increase in the in primary curvatures in ML canal in Vertucci type IV. Observation of secondary curvatures in PV in the present study showed significant correlation between MB and ML canals in Vertucci type II. This

means that secondary curvatures of MB in PV canal can provide information about secondary curvatures of ML in PV.

Correlation between canal curvature and interorifical distances

In Vertucci type VI, negative significant correlation between the primary curvature of mesiobuccal canal in proximal view and interorifical distances was observed while, for type II and type IV no significant correlations were observed. This is in accordance with finding of Cimilli et al [4]. Decrease in distant between MB and ML canals provide a predictive factor for the occurrence of Vertucci type VI.

Although the result of the current study provides beneficial information that may serve as basic data to enhance the understanding of root canal morphology and how to deal with complex variation of anatomy of mandibular first molars to get non-surgical successful root canal treatment for clinicians; this data may initiate questions which need to be answered in future studies: What further information can be provided when the same study is conducted in vivo with larger size of population? What information can be obtained if the same study is carried out to examine the anatomy of maxillary first molars among Sudanese population using CBCT imaging technique?

CONCLUSION

Based on the findings of the current study, the following conclusions could be drawn:

- In Vertucci type IV, increase in primary curvatures in MB canal provide increase in the primary curvatures in ML canal in CV.

- In Vertucci type II, secondary curvatures in PV of MB canal provide a predictive factor for secondary curvatures in PV of ML.

- Decrease in distant between MB and ML canals provide a predictive factor for the occurrence of Vertucci type VI.

Conflict of interests: The authors have stated explicitly that there are no conflicts of interest in connection with this article.

REFERENCES

1. de Pablo OV, Estevez R, Peix Sanchez M, Heilborn C, Cohenca N Root anatomy and canal configuration of the permanent mandibular first molar: a systematic review. *Journal of Endodontics*. 2010;36:1919-31. doi: 10.1016/j.joen.2010.08.055.
2. Harty FJ: *Endodontics in clinical practice*. Bistol:Wright;1982, 1982.
3. Peters OA Current challenges and concepts in the preparation of root canal systems: a review. *Journal of Endodontics*. 2004;30:559-67. doi: 10.1016/j.joen.2004.08.015.
4. Cimilli H, Mumcu G, Cimilli T, Kartal N, Wesselink P The correlation between root canal patterns and interorifical distance in mandibular first molars. *Oral Surgery, Oral Medicine, Oral Pathology, Oral Radiology, and Endodontology*. 2006;102:e16-21. doi: 10.1016/j.tripleo.2005.11.015.
5. Pruett JP, Clement DJ, Carnes DL, Jr. Cyclic fatigue testing of nickel-titanium endodontic instruments. *Journal of Endodontics*. 1997;23:77-85. doi: 10.1016/s0099-2399(97)80250-6.
6. Estrela C, Bueno MR, Sousa-Neto MD, Pecora JD Method for determination of root curvature radius using cone-beam computed tomography images. *Brazilian Dental Journal*. 2008;19:114-8. doi: 10.1590/s1513-04762008000300008.
7. Nair PN, Henry S, Cano V, Vera J Microbial status of apical root canal system of human mandibular first molars with primary apical periodontitis after "one-visit" endodontic treatment. *Oral Surgery, Oral Medicine, Oral Pathology, Oral Radiology, and Endodontology*. 2005;99:231-52. doi: 10.1016/j.tripleo.2004.10.005.
8. de Pablo OV, Estevez R, Heilborn C, Cohenca N Root anatomy and canal configuration of the permanent mandibular first molar: clinical implications and recommendations. *Quintessence International*. 2012;43:15-27. doi: 10.11606/q1.2012.43.15-27.
9. Vertucci FJ Root canal anatomy of the human permanent teeth. *Oral Surgery, Oral Medicine, Oral Pathology, Oral Radiology*. 1984;58:589-99. doi: 10.1016/0099-2399(84)90130-9.
10. Ahmed HA, Abu-bakr NH, Yahia NA, Ibrahim YE Root and canal morphology of permanent mandibular molars in a Sudanese population. *International Endodontic Journal* 2007;40:766-71. doi: 10.1111/j.1365-2591.2007.01283.x.
11. Demirbuga S, Sekerci AE, Dincer AN, Cayabatmaz M, Zorba YO Use of cone-beam computed tomography to evaluate root and canal morphology of mandibular first and second molars in Turkish individuals. *Medicina Oral Patologia Oral y Cirugia Bucal*. 2013:e737-e44. doi: 10.4317/medora.18473.
12. Skidmore AE, Bjorndal AM Root canal morphology of the human mandibular first molar. *Oral Surgery, Oral Medicine, Oral Pathology, Oral Radiology*. 1971;32:778-84. doi: 10.1016/0099-2399(71)90130-9.
13. vertucci FJ root canal morphology and its relationships to endodontic procedures. *Endodontic Topics*. 2005;10:3-29. doi: 10.1016/j.endo.2005.03.003.
14. Durack C, Patel S Cone beam computed tomography in endodontics. *Brazilian Dental Journal*. 2012;23:179-91. doi: 10.1590/s1513-04762012000300008.
15. Arslan H, Capar ID, Ertas ET, Ertas H, Akcay M A cone-beam computed tomographic study of root canal systems in mandibular premolars in a Turkish population: Theoretical model for determining orifice shape. *European Journal of Dentistry*. 2015;9:11-9. doi: 10.4103/1305-7456.149632.
16. Han X, Yang H, Li G, Yang L, Tian C, Wang Y A study of the distobuccal root canal orifice of the maxillary second molars in Chinese individuals evaluated by cone-beam computed tomography. *Journal of Applied Oral Science*. 2012;20:563-7. doi: 10.1590/s1513-04762012000300008.
17. Schneider SW A comparison of canal preparations in straight and curved root canals. *Oral Surgery, Oral Medicine, Oral Pathology, Oral Radiology*. 1971;32:271-5. doi: 10.1016/0099-2399(71)90130-9.

18. Sadeghi S, Poryousef V A novel approach in assessment of root canal curvature. *Iran Endodontic Journal*. 2009;4:131-4. doi.
19. Netto C, Lins CCdSA, Lins CV, Lima GA, Frazão MAG, CAMPOS NETTO P, et al. Study of the Internal Morphology of the Mesio Buccal Root of Upper First Permanent Molar Using Cone Beam Computed Tomography. *International Journal of Morphology*. 2011;29. doi.
20. Mukhaimer RH Evaluation of Root Canal Configuration of Mandibular First Molars in a Palestinian Population by Using Cone-Beam Computed Tomography: An Ex Vivo Study. *International Scholarly Research Notices*. 2014;2014:1-7. doi: 10.1155/2014/583621.
21. Kartal N, Cimilli HK The degrees and configurations of mesial canal curvatures of mandibular first molars. *Journal of Endodontics*. 1997;23:358-62. doi.
22. Peiris R, Takahashi M, Sasaki K, Kanazawa E Root and canal morphology of permanent mandibular molars in a Sri Lankan population. *Odontology*. 2007;95:16-23. doi: 10.1007/s10266-007-0074-8.
23. Torres A, Jacobs R, Lambrechts P, Brizuela C, Cabrera C, Concha G, et al. Characterization of mandibular molar root and canal morphology using cone beam computed tomography and its variability in Belgian and Chilean population samples. *Imaging Science in Dentistry*. 2015;45:95-101. doi: 10.5624/isd.2015.45.2.95.
24. Zhang R, Wang H, Tian YY, Yu X, Hu T, Dummer PM Use of cone-beam computed tomography to evaluate root and canal morphology of mandibular molars in Chinese individuals. *International Endodontic Journal* 2011;44:990-9. doi: 10.1111/j.1365-2591.2011.01904.x.
25. Karaman GT, Onay EO, Ungor M, Colak M Evaluating the potential key factors in assessing the morphology of mesio buccal canal in maxillary first and second molars. *Australian Endodontic Journal*. 2011;37:134-40. doi: 10.1111/j.1747-4477.2010.00240.x.

Eyhaa Siddig Alageb
(Corresponding address)

Department of Conservative Dentistry
Faculty of Dentistry
University of Khartoum
Khartoum, Sudan
E-mail: eyhaa82@gmail.com

Date submitted: 2019 Oct 11

Accept submission: 2020 Feb 05