



# Comparative evaluation of inter appointment pain and analgesic intake with calcium hydroxide and triple antibiotic paste as intracanal medicaments in patients with apical periodontitis – a randomized controlled single-blinded clinical trial

Avaliação comparativa da dor entre consultas e ingestão de analgésicos com hidróxido de cálcio e pasta de antibióticos triplos como medicamentos intracanaís em pacientes com periodontite apical - um ensaio clínico randomizado controlado simples-cego

Sanu NARAYANAN<sup>1</sup>, Kavalipurapu Venkata TEJA<sup>1</sup>, Sindhu RAMESH<sup>1</sup>

1 - Saveetha University, Saveetha Institute of Medical & Technical Sciences, Saveetha Dental College & Hospitals, Department of Conservative Dentistry & Endodontics. Chennai, Tamil Nadu, India.

## ABSTRACT

**Objective:** This study aimed to evaluate the effect of calcium hydroxide and triple antibiotic paste as intracanal medication on the interappointment pain at 8, 24, and 48 hours postoperatively in patients with symptomatic apical periodontitis undergoing multiple visit root canal treatment. **Material and Methods:** Two hundred and seven systemically healthy patients under the age group of 18-45 years with mandibular molars presenting with symptomatic apical periodontitis which require root canal treatments were included in this study. After access cavity preparation, cleaning and shaping was done till ISO 25 size file, and the patients were randomized into three groups (each group of 69 samples). Group I: no medicament, group II: calcium hydroxide and group III: triple antibiotic paste (TAP). Postoperative pain was evaluated at 8 hours, 24 hours and 48 hours. **Results:** The results showed that at 8 hours, 24 hours and 48 hours, there was a statistical difference between I and III ( $p < 0.05$ ); and Group III and Group II ( $p < 0.05$ ). Within the group, there was a statistical difference at all time points IN Group I and II ( $p < 0.05$ ) except between 24 hours and 48 hours in the Group III ( $p > 0.05$ ). **Conclusion:** Within the limitations of this study, TAP was more effective than calcium hydroxide in relieving pain and reducing the analgesic intake at the first 24 hours.

## KEYWORDS

Intracanal medicament; Calcium hydroxide; Triple antibiotic paste; Interappointment pain; Apical periodontitis.

## RESUMO

**Objetivo:** Este estudo teve como objetivo avaliar o efeito do hidróxido de cálcio e da pasta tripla de antibiótico como medicação intracanal na dor na interconsulta às 8, 24 e 48 horas de pós-operatório em pacientes com periodontite apical sintomática submetidos ao tratamento endodôntico por múltiplas visitas. **Material e Métodos:** Duzentos e sete pacientes sistemicamente saudáveis com idade inferior a 18-45 anos com molares inferiores apresentando periodontite apical sintomática que requerem tratamento de canal radicular foram incluídos neste estudo. Após o preparo da cavidade de acesso, a limpeza e modelagem foram feitas até arquivo ISO 25, e os pacientes foram randomizados em três grupos (cada grupo de 69 amostras). Grupo I: sem medicamento, grupo II: hidróxido de cálcio e grupo III: pasta tripla de antibiótico (TAP). A dor pós-operatória foi avaliada em 8 horas, 24 horas e 48 horas. **Resultados:** Os resultados mostraram que às 8 horas, 24 horas e 48 horas, houve diferença estatística entre I e III ( $p < 0,05$ ); e Grupo III e Grupo II ( $p < 0,05$ ). Dentro do grupo, houve diferença estatística em todos os momentos do Grupo I e II ( $p < 0,05$ ), exceto entre 24 horas e 48 horas no Grupo III ( $p >$

0,05). **Conclusão:** Dentro das limitações deste estudo, o TAP foi mais eficaz do que o hidróxido de cálcio no alívio da dor e na redução da ingestão de analgésicos nas primeiras 24 horas.

## PALAVRAS-CHAVE

Medicamento intracanal; Hidróxido de cálcio; Pasta antibiótica tripla; Dor na entrevista; Periodontite apical.

## INTRODUCTION

The pain of endodontic origin has been a significant concern to the patients and clinicians for many years [1]. Postoperative pain is associated with inflammation in the periradicular tissues caused by irritants exiting from the root canal during treatment. Irritation can be of biological (microorganisms) or non-biological (chemical or mechanical) origin. It has been suggested that microbial injury is probably the major and the most common cause of postoperative pain, and some Gram-negative anaerobic bacteria may play an essential role in the development of symptoms [2,3]. The reported incidence of interappointment emergencies in approximately 50% of 2000 patients who had received root canal treatment in pulpless teeth [4]. Certain factors also may predispose to the development of postoperative pain, such as preoperative pain and retreatment [4-6].

The ultimate goals of endodontic treatment are to remove as many bacteria, their byproducts, and pulpal remnants from the infected root canal system [7]. However, complete elimination of bacteria and its contents from the root canal system is challenging to accomplish [8]. Byproducts and degradation products of both microorganisms and pulpal tissue if left unremoved, even for a few millimeters in infected root canals, can lead to interappointment pain [9]. These microorganisms may be responsible for the production of enzymes and endotoxins, inhibiting the chemotaxis and phagocytosis resulting in persistence of painful periapical lesion [10]. Bacteria located inside dentinal tubules are protected from host defence cells, systemic antibiotics and chemomechanical preparation [11,12]. Chemomechanical preparation of root canal can reduce bacteria. However, about 40–60% of the canals still yield positive cultures after instrumentation and irrigation [13,14]. Thus, to achieve maximum disinfection of the root canals, the use of intracanal medication has been recommended [15].

The crucial role of an intracanal medicament is to reduce the possible regrowth of microorganisms and induce bacterial suppression. An interappointment antibiotic medication can eliminate bacterial flora and inhibits the proliferation of bacteria [16].

Antibiotics are not frequently advised to be used as an intracanal medication. But, there are certain conditions which necessitate antibiotics to use to achieve maximal disinfection. In cases with long-standing infections with polymicrobial contamination, a single antibiotic may not serve the purpose. Hence, a combination of antibiotic is efficient to achieve optimal disinfection in such cases [17,18]. Especially in cases with immature root apex, requiring revascularisation and apexification procedures, the complex microbial flora cannot be eliminated by the irrigation protocol alone. In such conditions, to achieve the optimal reduction of the bacteria, a triple antibiotic paste is used as an intracanal medication, before the procedure [19]. The concept of lesion sterilization and tissue repair (LSTR) employs the usage of multiple combinations of antibiotics for disinfection of oral infections, including the dentinal, pulpal and periradicular lesions [20]. So, preferably antibiotics are not frequently used as an intracanal medication for routine cases in daily practice, treatments resistant to routine intracanal medication requires usage of multiple antibiotic combinations to address the issues [17].

The modern concept of medicine emphasizes on the prevention and the reversal of diseases. Surgical interventions or restoration with the prosthesis are advised when preventive strategies fail [21]. Especially in endodontics, the success of the non-surgical endodontic treatment depends on the adequate chemomechanical disinfection, asepsis and adequate three dimensional obturation and seal of the root canal [22]. Based on the concepts of modern endodontics, the triple antibiotic paste became popular especially in addressing the issues on root canal optimal disinfection with minimal or

no instrumentation in cases of immature apexes undergoing revascularisation procedures [19,20]. The systemic administration of antibiotics relies on patient compliance with dosage regimens, absorption via GIT and distribution through the circulation, to reach the infected site. Hence, the infected area requires adequate blood supply, which is no longer in cases with infected necrotic pulps and in subjects with excised pulp tissue. So, to achieve the proper reduction of bacteria and optimal disinfection, local drug delivery of antibiotics in the root canal seemed to be a useful mode of delivery. Especially in regards to the endodontic infections, local application of antibiotics in the root canal space appears to be an effective mode of a delivery system [23]. When systemically administered, antibiotic effectiveness to the infected site relies on a blood supply to the site. So, logically, in cases of infected and necrotic pulps, which no longer have blood supply, local drug delivery using antibiotics is a valuable therapy in such conditions.

But the primary concern in the current scenario is the development of resistant strains to the antibiotic therapy [24]. Widespread usage of the antibiotics induces resistance and reduces the effectiveness of the treatment [24,25]. To combat the current threat of the antimicrobial resistance, combination of antibiotics against all endodontic pathogens can prevent the microbial resistance. Usage of antibiotics is only advised in cases which are reluctant to the normal mode of the therapy performed. Literature also supports the use of a wide range of natural plant extracts to be effective and exhibiting the antimicrobial properties [26,27]. So, to address the current threat on the development of antibiotic resistance, other adjunctive therapies should be concentrated more rather relying on the conventional mode of antibiotic administration.

Calcium hydroxide alters bacterial cell walls and detoxifies a potent endotoxin, a lipopolysaccharide, thereby rendering it less antigenic [28,29]. It has been suggested that calcium hydroxide has pain-preventive properties because of its antimicrobial or tissue-altering effects. Besides, it controls inflammatory processes and induces repair [30]. The antibacterial action of calcium hydroxide is due to its ability to release and diffusion of OH<sup>-</sup> ions. The high pH of calcium hydroxide alters the biologic properties of bacterial Lipopolysaccharides (LPS) in the cell wall of gram negative species and inactivates

membrane transport mechanism resulting in bacterial cell toxicity [31].

Local application of antibiotics in the root canal has been suggested to overcome the potential risk of adverse systemic effects of antibiotics and as a useful for drug delivery in teeth lacking blood supply due to necrotic pulps or pulp-less status [32]. Because root canal infections are polymicrobial consisting of both aerobic and anaerobic bacterial species [33], a single antibiotic may not be effective in canal disinfection. Therefore, a combination of antibiotics, mainly consisting of Ciprofloxacin, Metronidazole, and Minocycline, referred to as triple antibiotic (TA) paste has been suggested for root canal disinfection [34]. Ciprofloxacin has broad spectrum activity and acts against both Gram positive and Gram negative bacteria by inactivating enzymes and inhibiting cell division [35]. Metronidazole is effective against obligate anaerobes and acts by disrupting bacterial DNA [35]. Minocycline is a broad-spectrum tetracycline antibiotic and acts by inhibiting MMPs [35].

The literature is scarce on the evaluation of triple antibiotic paste sole as an intracanal medicament on postoperative pain reduction and especially on the postoperative analgesic intake. But the recent study evaluated triple antibiotic solution at the concentration of 1mg/ml, proved the effectiveness and ease of the delivery of the antibiotic solution, making it an appropriate medicament in non-surgical root canal treatment with least comparable side effects [36].

Hence, the aim of this randomized controlled clinical trial was to compare and evaluate postoperative pain between calcium hydroxide and triple antibiotic paste as an intracanal medicament in patients with symptomatic apical periodontitis undergoing multiple visit root canal treatment.

## MATERIALS AND METHODS

It was a Randomized, Controlled Single Blinded Clinical Trial. Approval for the project was obtained from the institutional review board of Saveetha University, India [SRB/SDMDS120]. The sample size was determined from a pilot study using the G power 3.1 version. The minimum sample size for each group was calculated by assuming alpha- and beta errors:

the power of 0.90 and  $p \leq 0.05$  and sample size 69 per group. For compensation of participants' dropouts during follow up, the total sample size was set at 245.

Two hundred forty-five volunteer patients under the age group of 18-45 years, fitting the inclusion criteria described above were included in this study (Table I). The study participants (Table II) were recruited from the pool of patients in the Department of Conservative Dentistry and Endodontics at Saveetha Dental College, Saveetha University, India. Randomization was done using block randomization.

Before the treatment, a careful medical and dental history was taken, and the 10-point Visual Analogue Scale measured the severity of pain. Multiple operators carried out the treatments. Sensibility was checked for the teeth using both cold testing 1,1,1,2 tetra fluoro ethane (Hygenic Corp., Akron, OH) and electric pulp tester (Parkell Inc, Edgewood, Newyork). All the patients received a topical anesthetic (Lidfast 2% Jelly; Samarth Life Sciences Private LTD, Gujarat, India). The tooth was anaesthetized using nerve blocks with 1.8ml of 2% Lignocaine with 1:80000 epinephrine. (Lignox 2% A, INDOCO Remedies LTD, Gujarat, India).

In the present study only mandibular first molars with symptomatic apical periodontitis

were only selected. Teeth with lesion were excluded from the study. Teeth were relieved out of occlusion, before the start of the procedure. Each tooth was isolated using a rubber dam. The occlusal reduction was done, and the access cavity was prepared using sterile carbide burs under an operating microscope (Carl Zeiss OPMI Pico, Germany). The access cavity was prepared using endo access bur size 2 (Dentsply, USA). Working length was determined with stainless steel hand K-file size # 10 (Mani, Tachigiken, Japan) using apex locator (Root ZX mini, J Morita CORP, USA). Canals were then pre flared using Gates Glidden drills up to size 2. Patency checked with No.10 K file. (Mani Inc, Tachigiken, Japan). The shaping of canals was done using Protaper next rotary files (Dentsply Sirona, USA) till size 25-30 in narrow canals and 35-40 in large canals). Throughout shaping, saline was used as an irrigant. Following instrumentation, canals are dried using paper points and divided into three groups. In Group I, no intracanal medication was placed. In Group II, calcium hydroxide was placed and in Group III, triple antibiotic paste was placed using lentulo spirals.

Triple antibiotic paste used in this study was prepared by removing the coating and crushing of antibiotic ciprofloxacin (Ciplox 500 mg, Cipla, India), metronidazole (Metrogyl 400 mg, J.B.Chemicals and Pharmaceuticals Ltd., India), and minocycline (Minoz 100mg, Cipla, India) tablets separately using a mortar and pestle. The powder thus obtained was mixed with macrogol + propylene glycol in 1:3:3 proportions, respectively, to get a paste-like consistency. The medication was placed inside the canal using lentiospiral. Calcium hydroxide used in this study was a formulation of calcium Hydroxide with barium sulphate in ready to use paste form (RC CAL, Prime Dental products, India). RC CAL is highly alkaline radiopaque water-soluble paste and is non-setting in nature. After preparation of root canal cleaning and drying, calcium hydroxide paste is placed into the canal using lentilospirals.

The intracanal medication was used only for a week. All patients were advised to take oral analgesics if they had pain. Patients under Group II and Group III were recalled approximately after one week, canals cleaned and shaped completely and irrigated with 3% NaOCl (Parcan, Gujarat, India) and 17% EDTA liquid (MD Cleanser, MetaBiomed. Co. LTD, Korea) and obturated

**Table I** - Inclusion and exclusion criteria

Inclusion Criteria	Exclusion Criteria
1. Mandibular first molars with symptomatic apical periodontitis having pain more than or equal to 4 in 10-point visual analogue scale,	1. Teeth associated with swelling/lesion/open apex
2. Teeth with adequate crown structure	2. patients who received antibiotic or analgesics within three months, having more than one tooth to be root canal treated
3. Patients under the age group of 18-45 years with good general health	3. Medically compromised patients

**Table II** - Demographic Data

Groups	N	Mean	Std. Deviation
I	81	34.7	7.4
II	82	34.9	7.5
III	82	34.7	7.9

with Gutta Percha points (MetaBioMed. Co. LTD, Korea) using AH-Plus sealer (Dentsply Sirona, USA) by lateral condensation technique. Only in group I, patients were again given a calcium hydroxide intracanal medicament for a week and then were obturated after a standard irrigation protocol, during their final visit.

Our study was solely aimed at assessing the efficacy of the interappointment disinfectants. Hence we did not use any disinfectants such as NaOCl and CHX as they have an added benefit in reducing the infection and this would not give a precise understanding on the real scenario on the efficacy of the agents alone. Hence in our study, we used the saline alone as an irrigant. Once the experimental protocol was finished, all the cases were treated using a standard disinfection protocol, before the Obturation. So, the present study results showed a positive effect of tap over the calcium hydroxide. Our study was aimed only at assessing the efficacy of Intracanal medicaments alone. We thought the usage of adjunctive disinfection aids may cause biased results and may not truly reciprocate the efficacy of these agents used solely.

All participants received a sheet containing a 10-point Visual Analogue Scale after the procedure. Preoperative pain score was recorded. A note containing the VAS was given to each patient for them to record the intensity of pain felt after 8 hours, 24 hours and 48 hours. Patients were called over the telephone and asked for their general feeling in the area of the root canal. Each patient was prescribed with 200 mg of Ibuprofen tablets and asked to take a maximum of 4 pills a day, in case of uncontrolled pain. The pain intensity was recorded using 10 point Visual Analogue Scale and the total number of tablets that had been taken by the patients at each follow-up period were recorded on the patient's chart.

### Statistical analysis

SPSS version 22.0 was used to analyze the data. Significance level is fixed as 5% ( $\alpha = 0.05$ ). To compare the pain scores values between groups (Intergroup analysis), Kruskal Wallis test was used. Mann Whitney test was used for multiple pairwise comparisons. The intragroup analysis was done using the Friedman test. Pain scores values between time points were compared using repeated-measures ANOVA.

## RESULTS

The VAS pain score preoperatively (Figure 1; Table III), in all groups was 5.81, 5.99, 5.80 at 8hour, 24hour and 48hour postoperatively in Group I was 4.09, 2.34, 1.07, respectively (Table IV,V,VI). In Group II, it was 4.06, 2.06 and 0.75 (Table IV,V,VI). In Group III, the mean pain score was 2.34, 0.77 and 0.34, respectively. (Table IV,V,VI) Preoperative scores between the three groups were not significant while there was a statistical difference between the three

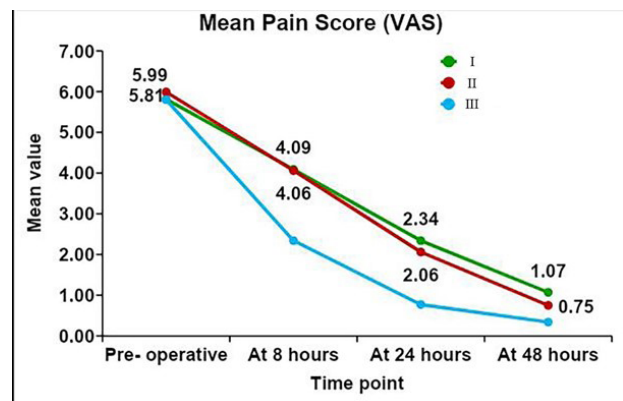


Figure 1 - Mean Pain Score (VAS).

Table III - Table presenting the preoperative pain scores and tablet intake

Groups	Pain Scores	Tablet Intake (Percentage)
I	5.81	-
II	5.99	-
III	5.80	-

Table IV - Table presenting the pain scores and tablet intake at 8 hours

Groups	Pain Scores	Tablet Intake (Percentage)
I	4.09	67.1
II	4.06	72.5
III	2.34	14.3

Table V - Table presenting the pain scores and tablet intake at 24 hours

Groups	Pain Scores	Tablet Intake (Percentage)
I	2.34	31.4
II	2.06	26.1
III	0.77	4.3

groups at all-time intervals. ( $p > 0.05$ ) At 8 hours, and 48 hours, there was a statistical difference between Group I and Group III; and Group III and Group II.

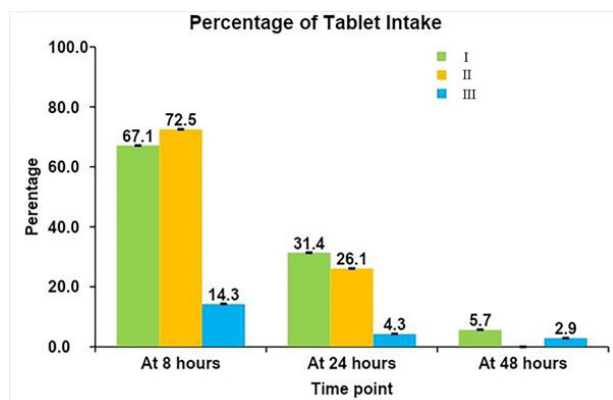
Within the Group there was a statistical difference at all time points ( $p < 0.05$ ) in Group I and II, except at 24 and 48 hours in Group III ( $p > 0.05$ ). A similar trend can be seen in the case of tablet intake, also (Figure 2; Table IV,V,VI). The proportion of patients taking tablets was comparable between Group I and Group II at 8 and 24 hours. However, at 48 hours, none of the patients in Group II took pills while in Group I, 5% of patients had to take tablets. In Group III, the proportion of patients taking tablets was greatly reduced from the 8th hour (51%) to 48th hour (2.9%).

## DISCUSSION

Patients with apical periodontitis were selected for this study. Previous studies have shown that preoperative pain can significantly increase the probability of postoperative pain [37]. So patients with pain score more than or equal to 4 were recruited for this study. The diagnosis was performed through pulp sensibility testing. Further status was confirmed by the absence of vital pulp/bleeding during access opening.

**Table VI** - Table presenting the pain scores and tablet intake at 48 hours

Groups	Pain Scores	Tablet Intake (Percentage)
I	1.07	5.7
II	0.75	-
III	0.34	2.9



**Figure 2** - Tablet intake.

Clinical and radiographic evidence of apical periodontitis was confirmed by tenderness to percussion and widening of periodontal ligament space.

In this trial, the occlusal reduction was done before preparing the access cavity. Once the access cavity was prepared, all canals were pre flared using Gates Glidden drills up to size two and prepared in a crown down technique. This crown down technique produces less extrusion of debris apically which will decrease chances for any inflammatory response and hence, decrease in postoperative pain [38,39]. Apical patency was maintained throughout the chemomechanical procedure by using a small K-file. The recent systematic review stated no significance on postoperative pain on maintaining apical patency using smaller files. Therefore, certain factors affecting the treatment outcome were eliminated [40].

Calcium hydroxide is the most commonly used intracanal medicament in root canal therapy [41]. The previous study shows that the vehicle used with calcium hydroxide influences their biological and antimicrobial properties and also affects the diffusion capability of calcium hydroxide [42]. In the present study, a paste form of commercially available calcium hydroxide was used.

Because of the complexity of the root canal infection, it is unlikely that any single antibiotic could result in effective sterilization of the canal. A combination of antibiotics would be needed to address the diverse flora encountered. A combination of antibiotics would also decrease the likelihood of the development of resistant bacterial strains [43]. Triple antibiotic paste has been vastly used in endodontic treatments. It can eliminate the root canal microorganisms and prepare an appropriate matrix for further treatments [44]. The previous study reported that the vehicle and antibiotic formulation influenced cytotoxicity. The pastes prepared with tablets or capsules with macrogol+propylene glycol were less cytotoxic than United States Pharmacopeia (USP) grade antibiotics with water formulations [45]. Hence in the present study, we used the tablets and capsule formulations mixed with a combination of macrogol+propylene glycol.

There was no statistical difference in the pain score between the groups preoperatively.

Postoperatively there was a statistical difference between the groups at all periods. Within the groups, there was no statistical difference between calcium hydroxide and no medicament at all periods postoperatively. Still, there exists a controversy on whether calcium hydroxide is effective in relieving pain. Results of this show that there is no superior pain-relieving property to calcium hydroxide compared with no intracanal medicament placed. The results were following a systematic review by Anjaneyulu and Nivedhitha [46] When Group II and Group III were compared, the difference was observed in terms of postoperative pain at all periods. Similarly, Group I and Group III had significant differences at all periods.

Within each group, the pain score was statistically significant. There was no difference in pain level at 24 and 48 hours in Group III. Pain score in all the groups gradually decreased over time. In 8 and 24 hours, the mean pain score in Group I and Group II was comparable. However, at 48hours, Group II had significant mean score reduction when compared to Group I. In Group III, the mean pain score drastically reduced, and at the end of 48hours, the pain score was negligible.

A similar trend can be seen in the case of tablet intake also. The proportion of patients taking tablets was comparable between Group I and Group II at 8 and 24 hours. However, at 48 hours, none of the patients in Group II took tablets while in Group I, 5% of patients had to take tablets. In Group III, the proportion of patients taking tablets was greatly reduced from the 8th hour (51%) to 48th hour (2.9%).

Literature reported an overall incidence of intense postoperative pain was low (~3%) and ranged up to 58% [47]. Maximum post-treatment pain occurs within the first 24 hours after treatment, and this finding is consistent with the previous studies [48].

The comparable pain score between Group I and Group II at 8 hours and 24 hour shows insignificant pain reduction at specific periods. The substantial reduction of pain score was seen at 48 hours in Group II as compared to the group I.

The reduction of pain was seen even in Group I when compared to other groups in which an intracanal medicament has been placed.

So, the debridement of pulp tissue and cleaning of the pulp space remains the most critical strategy to reduce pain. The intracanal medicament can be used for additional disinfection of those areas which are left untouched by chemomechanical preparation of root canal.

The current evidence states that systemic antibiotics are less effective in endodontic infections and that antibiotics should be prescribed only in cases with systemic spread of disease [49]. However, localized drug delivery of antibiotics alone or in combination would give a better therapeutic outcome for endodontic infections. Hence, our study was mainly assessing on the TAP compared to calcium hydroxide on the contrary.

Triple antibiotic paste showed a more significant reduction in pain score at all periods compared to other groups. This could be attributed to the combined spectrum of antimicrobial activity and synergistic of additive actions of antibiotics ciprofloxacin, metronidazole and minocycline found in TAP. The increased reduction of pain with TAP could also be attributed to the anti-inflammatory property of antibiotic minocycline [50].

Previous literature was scarce on evaluating the postoperative pain using TAP and calcium hydroxide. The present study results were in correlation with the previous literature, which showed the favourable results to TAP in postoperative pain reduction [51]. Although previous studies reported the reduction in pain, the consideration was not given for patients with preoperative pain [52]. As mentioned earlier, patients presenting with preoperative pain have higher chances of eliciting postoperative pain scores [37].

The other uniqueness of the present study was standardizing only the mandibular first molar teeth. Previous literature has reported the incidence of severe postoperative pain in mandibular arches and especially with the molar teeth [53]. Hence, the present study considered only evaluating these patients. Previous literature on occlusal reduction concluded that teeth reduced out of occlusion elicited lesser interappointment pain [54]. Hence, to exclude the confounding factor related bias, all the included patients underwent occlusal reduction to maintain the teeth out of occlusion. There was no previous literature on postoperative analgesic intake. The present study was the first one to assess

the amount of intake at different experimental periods precisely.

Although the results of the present study proved that TAP was more effective than calcium hydroxide in reducing pain and analgesic intake in first 24 hours, we cannot justify this as a fact and use antibiotics in routine practice. The fact is reducing antibiotic intake is more beneficial to the patient than reducing analgesic intake, as analgesics are less harmful to the patient than antibiotics. Although localized drug delivery might not be more dangerous than a systemic mode of therapy, they are always preferred as an adjunctive mode of treatment. Better to use antibiotics only when the conventional therapeutic modes fail to elicit the beneficial effect. But, our study was mainly aimed at assessing the intracanal medicaments alone, without any adjunctive therapeutic or combined regimens. So, the results of our study might not reciprocate the true clinical scenario.

Ideally, in daily clinical practice, antibiotics should be considered only when other medicaments and regimens fail to achieve the therapeutic benefit. With the advancements in disinfection systems in the present scenario, the dependency on the antibiotics is reduced. So, especially in multi-visit root canal treatments, triple antibiotic paste should be considered only in reluctant cases or in cases where the routine therapeutic approaches fail to achieve success.

One of the main problems in studying pain is the patient's subjective evaluation and its measurement, which depend on personal feelings. Within the limitations of this study, it was seen that patients in which TAP intracanal medicament was placed had more significant pain reduction as compared to calcium hydroxide. The attributed reason would be due to the protocol of the present study. As we assessed only the effectiveness of medicaments used alone, we don't rely on any irrigation regimen and used only the saline as an irrigant in the entire experimentation. So, the disinfection capacity of TAP alone is more as compared to CaOH<sub>2</sub>. Hence patients would have presented with more pain in Group II. Patients had negligible pain after 48 hours if calcium hydroxide or TAP was placed. Also, it was found that patients rarely required analgesics after 48 hours. Systemic antibiotics had an only negligible effect in endodontic infections. It was also seen that proper cleaning

and shaping remains the primary strategy in relieving interappointment pain.

## CONCLUSION

Within the limitations of this study, it was seen that

1. Use of TAP as an intracanal medicament can reduce the number of analgesics required during root canal treatment.
2. TAP was more effective than calcium hydroxide in relieving pain in the first 24 hours.

## Authors' Contribution

SN: Concept and design of the study, Data acquisition, Revising the manuscript critically for intellectual content, Analysis and interpretation of data; KVT: Data acquisition, Revising the manuscript critically for intellectual content, Analysis and interpretation of data; SR: Data acquisition, Revising the manuscript critically for intellectual content, Analysis and interpretation of data.

## Conflict of Interest

The authors have no proprietary, financial, or other personal interest of any nature or kind in any product, service, and/or company that is presented in this article.

## Funding

There is no external source of funding.

## Regulatory Statement

Nil.

## REFERENCES

1. Singh RD, Khatter R, Bal RK, Bal CS. Intracanal medications versus placebo in reducing postoperative endodontic pain—a double-blind randomized clinical trial. *Braz Dent J.* 2013;24(1):25-9. <http://dx.doi.org/10.1590/0103-6440201302039>. PMID:23657409.
2. Seltzer S, Naidorf IJ. Flare-ups in endodontics: I. Etiological factors. 1985. *J Endod.* 2004;30(7):476-81, discussion 475. <http://dx.doi.org/10.1097/00004770-200407000-00005>. PMID:15220641.
3. Siqueira JF Jr. Microbial causes of endodontic flare-ups. *Int Endod J.* 2003;36(7):453-63. <http://dx.doi.org/10.1046/j.1365-2591.2003.00671.x>. PMID:12823700.
4. Torabinejad M, Kettering JD, McGraw JC, Cummings RR, Dwyer TG, Tobias TS. Factors associated with endodontic



- interappointment emergencies of teeth with necrotic pulps. *J Endod.* 1988;14(5):261-6. [http://dx.doi.org/10.1016/S0099-2399\(88\)80181-X](http://dx.doi.org/10.1016/S0099-2399(88)80181-X). PMID:3251982.
5. Kissin I, Weiskopf RB. Preemptive analgesia. *Anesthesiology.* 2000;93(4):1138-43. <http://dx.doi.org/10.1097/00000542-200010000-00040>. PMID:11020772.
  6. Imura N, Zuolo ML. Factors associated with endodontic flare-ups: a prospective study. *Int Endod J.* 1995;28(5):261-5. <http://dx.doi.org/10.1111/j.1365-2591.1995.tb00311.x>. PMID:8626209.
  7. Kawashima N, Wadachi R, Suda H, Yeng T, Parashos P. Root canal medicaments. *Int Dent J.* 2009;59(1):5-11. PMID:19323305.
  8. Teja KV, Ramesh S. Shape optimal and clean more. *Saudi Endod J.* 2019;9(3):235.
  9. Siqueira JF Jr, Rôças IN, Favieri A, Machado AG, Gahyva SM, Oliveira JC, et al. Incidence of postoperative pain after intracanal procedures based on an antimicrobial strategy. *J Endod.* 2002;28(6):457-60. <http://dx.doi.org/10.1097/00004770-200206000-00010>. PMID:12067129.
  10. Gomes BPPA, Herrera DR. Etiologic role of root canal infection in apical periodontitis and its relationship with clinical symptomatology. *Braz Oral Res.* 2018;32(Suppl 1):e69. <http://dx.doi.org/10.1590/1807-3107bor-2018.vol32.0069>. PMID:30365610.
  11. Jhajharia K, Parolia A, Shetty KV, Mehta LK. Biofilm in endodontics: a review. *J Int Soc Prev Community Dent.* 2015;5(1):1-12. <http://dx.doi.org/10.4103/2231-0762.151956>. PMID:25767760.
  12. Siqueira JF Jr, Lopes HP. Mechanisms of antimicrobial activity of calcium hydroxide: a critical review. *Int Endod J.* 1999;32(5):361-9. <http://dx.doi.org/10.1046/j.1365-2591.1999.00275.x>. PMID:10551109.
  13. Sjögren U, Figdor D, Persson S, Sundqvist G. Influence of infection at the time of root filling on the outcome of endodontic treatment of teeth with apical periodontitis. *Int Endod J.* 1997;30(5):297-306. <http://dx.doi.org/10.1111/j.1365-2591.1997.tb00714.x>. PMID:9477818.
  14. Siqueira JF Jr, Guimarães-Pinto T, Rôças IN. Effects of chemomechanical preparation with 2.5% sodium hypochlorite and intracanal medication with calcium hydroxide on cultivable bacteria in infected root canals. *J Endod.* 2007;33(7):800-5. <http://dx.doi.org/10.1016/j.joen.2006.11.023>. PMID:17804315.
  15. Siqueira JF Jr, Magalhães KM, Rôças IN. Bacterial reduction in infected root canals treated with 2.5% NaOCl as an irrigant and calcium hydroxide/camphorated paramonochlorophenol paste as an intracanal dressing. *J Endod.* 2007;33(6):667-72. <http://dx.doi.org/10.1016/j.joen.2007.01.004>. PMID:17509403.
  16. Mirza MB, Alhedyan FS, Alqahtani AM. Antibiotics in endodontics. *J Dent Res Rev.* 2019;6(3):65. [http://dx.doi.org/10.4103/jdrr.jdrr\\_52\\_19](http://dx.doi.org/10.4103/jdrr.jdrr_52_19).
  17. Mohammadi Z. Chemomechanical strategies to manage endodontic infections. *Dent Today.* 2010;29(2):91-6, 94, 96 passim, quiz 99. PMID:20196338.
  18. Windley W III, Teixeira F, Levin L, Sigurdsson A, Trope M. Disinfection of immature teeth with a triple antibiotic paste. *J Endod.* 2005;31(6):439-43. <http://dx.doi.org/10.1097/01.don.0000148143.80283.ea>. PMID:15917683.
  19. Couto AM, Espaladori MC, Leite APP, Martins CC, Aguiar MCF, Abreu LG. A systematic review of pulp revascularization using a triple antibiotic paste. *Pediatr Dent.* 2019;41(5):341-53. PMID:31648664.
  20. Hoshino E. LSTR 3Mix-MP method-better and efficient clinical procedures of lesion sterilization and tissue repair (LSTR) therapy. *Dent Rev.* 1998;666:57-106.
  21. Huang GT. A paradigm shift in endodontic management of immature teeth: conservation of stem cells for regeneration. *J Dent.* 2008;36(6):379-86. <http://dx.doi.org/10.1016/j.jdent.2008.03.002>. PMID:18420332.
  22. Taneja S, Kumari M, Parkash H. Nonsurgical healing of large periradicular lesions using a triple antibiotic paste: a case series. *Contemp Clin Dent.* 2010;1(1):31-5. <http://dx.doi.org/10.4103/0976-237X.62519>. PMID:22114375.
  23. Thomas MS, Parolia A, Kundabala M, Vikram M. Non-Surgical endodontic therapy using triple-antibiotic paste—case report. *Kerala Dent J.* 2010;33(2):88-91.
  24. Leibovici L, Paul M, Garner P, Sinclair DJ, Afshari A, Pace NL, et al. Addressing resistance to antibiotics in systematic reviews of antibiotic interventions. *J Antimicrob Chemother.* 2016;71(9):2367-9. <http://dx.doi.org/10.1093/jac/dkw135>. PMID:27169438.
  25. Bell BG, Schellevis F, Stobberingh E, Goossens H, Pringle M. A systematic review and meta-analysis of the effects of antibiotic consumption on antibiotic resistance. *BMC Infect Dis.* 2014;14(1):13. <http://dx.doi.org/10.1186/1471-2334-14-13>. PMID:24405683.
  26. Gummuluri S, Kavalipurapu VT, Kaligotla AV. Antimicrobial efficacy of Novel ethanolic extract of morinda citrifolia against *Enterococcus Faecalis* by agar well diffusion method and minimal inhibitory concentration-an invitro study. *Braz Dent Sci.* 2019;22(3):365-70. <http://dx.doi.org/10.14295/bds.2019.v22i3.1731>.
  27. Teja KV, Kaligotla AV, Gummuluri S. Antibacterial efficacy of conventional versus herbal products on *Streptococcus mutans* in adult population—a systematic review & meta-analysis. *Braz Dent Sci.* 2020;23(4):1-18. <http://dx.doi.org/10.14295/bds.2020.v23i4.2012>.
  28. Safavi KE, Nichols FC. Effect of calcium hydroxide on bacterial lipopolysaccharide. *J Endod.* 1993;19(2):76-8. [http://dx.doi.org/10.1016/S0099-2399\(06\)81199-4](http://dx.doi.org/10.1016/S0099-2399(06)81199-4). PMID:8509740.
  29. Walton RE, Holton IF Jr, Michelich R. Calcium hydroxide as an intracanal medication: effect on posttreatment pain. *J Endod.* 2003;29(10):627-9. <http://dx.doi.org/10.1097/00004770-200310000-00003>. PMID:14606782.
  30. Fava LR. Acute apical periodontitis: incidence of post-operative pain using two different root canal dressings. *Int Endod J.* 1998;31(5):343-7. <http://dx.doi.org/10.1046/j.1365-2591.1998.00159.x>. PMID:9823137.
  31. Mohammadi Z, Dummer PM. Properties and applications of calcium hydroxide in endodontics and dental traumatology. *Int Endod J.* 2011;44(8):697-730. <http://dx.doi.org/10.1111/j.1365-2591.2011.01886.x>. PMID:21535021.
  32. Mohammadi Z, Abbott PV. On the local applications of antibiotics and antibiotic-based agents in endodontics and dental traumatology. *Int Endod J.* 2009;42(7):555-67. <http://dx.doi.org/10.1111/j.1365-2591.2009.01564.x>. PMID:19467048.
  33. Zehnder M. Root canal irrigants. *J Endod.* 2006;32(5):389-98. <http://dx.doi.org/10.1016/j.joen.2005.09.014>. PMID:16631834.
  34. Windley W III, Teixeira F, Levin L, Sigurdsson A, Trope M. Disinfection of immature teeth with a triple antibiotic paste. *J Endod.* 2005;31(6):439-43. <http://dx.doi.org/10.1097/01.don.0000148143.80283.ea>. PMID:15917683.
  35. Brunton LL, Lazo JS, Parker KL. Goodman and Gilman's the pharmacological basis of therapeutics. 11th ed. New York: McGraw Hill companies; 2006.
  36. Arruda MEF, Neves MAS, Diogenes A, Mdala I, Guilherme BPS, Siqueira JF Jr, et al. Infection control in teeth with apical periodontitis using a triple antibiotic solution or Calcium Hydroxide with Chlorhexidine: a randomized clinical trial. *J Endod.* 2018;44(10):1474-9. <http://dx.doi.org/10.1016/j.joen.2018.07.001>. PMID:30144986.

37. Smith EA, Marshall JG, Selph SS, Barker DR, Sedgley CM. Nonsteroidal anti-inflammatory drugs for managing postoperative endodontic pain in patients who present with preoperative pain: a systematic review and meta-analysis. *J Endod.* 2017;43(1):7-15. <http://dx.doi.org/10.1016/j.joen.2016.09.010>. PMID:27939729.
38. Kustarci A, Akdemir N, Siso SH, Altunbas D. Apical extrusion of intracanal debris using two engine driven and step-back instrumentation techniques: an in-vitro study. *Eur J Dent.* 2008;2(4):233-9. <http://dx.doi.org/10.1055/s-0039-1697386>. PMID:19212528.
39. Bidar M, Rastegar AF, Ghaziani P, Namazikhah MS. Evaluation of apically extruded debris in conventional and rotary instrumentation techniques. *J Calif Dent Assoc.* 2004;32(9):665-71. PMID:15553960.
40. Abdulrab S, Rodrigues JC, Al-Maweri SA, Halboub E, Alqutaibi AY, Alhadainy H. Effect of apical patency on postoperative pain: a meta-analysis. *J Endod.* 2018;44(10):1467-73. <http://dx.doi.org/10.1016/j.joen.2018.07.011>. PMID:30170845.
41. Kim D, Kim E. Antimicrobial effect of calcium hydroxide as an intracanal medicament in root canal treatment: a literature review - Part I. In vitro studies. *Restor Dent Endod.* 2014;39(4):241-52. <http://dx.doi.org/10.5395/rde.2014.39.4.241>. PMID:25383341.
42. Gomes BP, Ferraz CC, Vianna ME, Rosalen PL, Zaia AA, Teixeira FB, et al. In vitro antimicrobial activity of calcium hydroxide pastes and their vehicles against selected microorganisms. *Braz Dent J.* 2002;13(3):155-61. <http://dx.doi.org/10.1590/S0103-64402002000300002>. PMID:12428587.
43. Mohammadi Z, Jafarzadeh H, Shalavi S, Yaripour S, Sharifi F, Kinoshita JI. A review on triple antibiotic paste as a suitable material used in regenerative endodontics. *Iran Endod J.* 2018;13(1):1-6. PMID:29692827.
44. Parhizkar A, Nojehdehian H, Asgary S. Triple antibiotic paste: momentous roles and applications in endodontics: a review. *Restor Dent Endod.* 2018;43(3):e28. <http://dx.doi.org/10.5395/rde.2018.43.e28>. PMID:30135847.
45. Faria G, Rodrigues EM, Coaguila-Llerena H, Gomes-Cornélio AL, Neto Angéloco RR, Swerts Pereira MS, et al. Influence of the vehicle and antibiotic formulation on cytotoxicity of triple antibiotic paste. *J Endod.* 2018;44(12):1812-6. <http://dx.doi.org/10.1016/j.joen.2018.09.009>. PMID:30477667.
46. Anjaneyulu K, Nivedhitha MS. Influence of calcium hydroxide on the post-treatment pain in Endodontics: a systematic review. *J Conserv Dent.* 2014;17(3):200-7. <http://dx.doi.org/10.4103/0972-0707.131775>. PMID:24944439.
47. Sathorn C, Parashos P, Messer H. The prevalence of postoperative pain and flare-up in single- and multiple-visit endodontic treatment: a systematic review. *Int Endod J.* 2008;41(2):91-9. PMID:17956561.
48. Pak JG, White SN. Pain prevalence and severity before, during, and after root canal treatment: a systematic review. *J Endod.* 2011;37(4):429-38. <http://dx.doi.org/10.1016/j.joen.2010.12.016>. PMID:21419285.
49. Segura-Egea JJ, Gould K, Şen BH, Jonasson P, Cotti E, Mazzoni A, et al. European Society of Endodontology position statement: the use of antibiotics in endodontics. *Int Endod J.* 2018;51(1):20-5. <http://dx.doi.org/10.1111/iej.12781>. PMID:28436043.
50. Dunston CR, Griffiths HR, Lambert PA, Staddon S, Vernallis AB. Proteomic analysis of the anti-inflammatory action of minocycline. *Proteomics.* 2011;11(1):42-51. <http://dx.doi.org/10.1002/pmic.201000273>. PMID:21182193.
51. Pai S, Vivekananda Pai AR, Thomas MS, Bhat V. Effect of calcium hydroxide and triple antibiotic paste as intracanal medicaments on the incidence of inter-appointment flare-up in diabetic patients: an in vivo study. *J Conserv Dent.* 2014;17(3):208-11. <http://dx.doi.org/10.4103/0972-0707.131776>. PMID:24944440.
52. Uyan HM, Olcay K, Özcan M. Comparative evaluation of postoperative pain intensity after single-visit and multiple-visit retreatment cases: a prospective randomized clinical trial. *Braz Dent Sci.* 2018;21(1):26-36. <http://dx.doi.org/10.14295/bds.2018.v21i1.1515>.
53. Sadaf D, Ahmad MZ. Factors associated with postoperative pain in endodontic therapy. *Int J Biomed Sci.* 2014;10(4):243-7. PMID:25598754.
54. Shamszadeh S, Shirvani A, Asgary S. Does occlusal reduction reduce post-endodontic pain? A systematic review and meta-analysis. *J Oral Rehabil.* 2020;47(4):528-35. <http://dx.doi.org/10.1111/joor.12929>. PMID:31880822.

**Sindhu Ramesh**  
(Corresponding address)

Saveetha University, Saveetha Institute of Medical & Technical Sciences, Saveetha Dental College & Hospitals, Department of Conservative Dentistry & Endodontics, Chennai, Tamil Nadu, India.  
Email: [sindhuramesh@saveetha.com](mailto:sindhuramesh@saveetha.com)

Date submitted: 2020 Sept 27  
Accept submission: 2021 Jan 04