



Replacement of maxillary lateral incisors with digitally manufactured single tooth retained all-ceramic pontics: a clinical report

Reabilitação da região de incisivo lateral superior ausente por pôntico modelo cantiléver em cerâmica pura fabricado digitalmente: relato de caso clínico

Bahar ELTER¹ , Akın ALADAĞ², Muharrem Erhan ÇÖMLEKOĞLU³, Mine Dündar ÇÖMLEKOĞLU³

1 - Istanbul Okan University, Faculty of Dentistry, Department of Prosthodontics Tuzla, Istanbul, Turkey

2 - Muğla Sıtkı Koçman University, Faculty of Dentistry, Department of Prosthodontics, Muğla, Turkey

3 - Ege University, Faculty of Dentistry, Department of Prosthodontics, Bornova, Izmir, Turkey

ABSTRACT

Several treatment options for replacement of anterior missing teeth exist, varying from no-prep (no preparation) adhesive restorations to implants. Patients' biological, psychological, economic conditions or age have an effect on the treatment choice. It is important to perform the most conservative and beneficial treatment option considering the patient based factors. The aim of this case report was to demonstrate a single session, minimally invasive, cantilevered 2-unit all-ceramic restorations replacing anterior missing teeth combined with the advantages of CAD/CAM technology and materials.

KEYWORDS

CAD/CAM; Cantilever; Digital dentistry; Resin-bonded Fixed dental prostheses.

RESUMO

Existem várias opções de tratamento para reabilitação de dentes anteriores ausentes, variando de restaurações adesivas sem preparo (sem preparação) até implantes. As condições biológicas, psicológicas, econômicas ou a idade dos pacientes têm um efeito na escolha do tratamento. É importante realizar a opção de tratamento mais conservadora e benéfica, considerando os fatores baseados no paciente. O objetivo deste relato de caso foi demonstrar em sessão única, minimamente invasiva, um cantiléver de restaurações de cerâmica pura de 2 unidades, reabilitando a região de dentes anteriores ausentes combinadas com as vantagens da tecnologia CAD/CAM.

PALAVRAS-CHAVE

CAD/CAM; Cantilever; Odontologia digital; Próteses dentárias fixas com resina.

INTRODUCTION

Advanced techniques in adhesive cementation and ceramic strengthening systems eased the fabrication of minimal or no-preparation requiring, esthetic, durable and conservative resin bonded fixed partial dental prostheses (RBFDPs) [1-10].

Various treatment options exist for the replacement of congenitally missing teeth, like orthodontic enclosure of the empty space, conventional FDP, RBFDPs, removable partial dentures or dental implants. Decision of the clinician depends on clinical and radiographic assessments and on the knowledge of the long-term survival and complication rates of each of these treatment options. If orthodontic treatment of any gap closure is not indicated, implants seem to be the most conservative treatment for permanent teeth replacement [11-13]. However, if implant supported prostheses are not indicated for anatomical, medical, financial or psychological reasons, cantilevered and resin bonded partial dentures are an exceptional non-invasive choice for anterior single teeth replacement instead of conventional FDP especially for young patients [1, 3, 4, 14, 15].

Several different materials have been used for fabrication of RBFDPs. Advances in more biocompatible all ceramic systems have led to increased use of these restorations for definitive and temporary treatment goals [16-19]. Glass ceramics and oxide ceramics have been widely used to produce similar optical properties with natural teeth in conservative treatment approaches [3, 4]. With developments in digital dentistry, difficulties of processing these strong materials have also been highly solved.

In clinical use, it is possible to perform cantilevered RBFDPs using zirconium dioxide as a framework due to material's high fracture toughness and strength [3, 6]. But the fact that zirconia does not involve a glass phase, thus not prone to hydrofluoric acid etching for microretention, as well as limited use of silanes which promote bonding of glass ceramics to denture and dental substrates, for zirconia surface treatment; resin bonding to zirconia or other oxide ceramics is a problem that is still in debate. Limited bonding of zirconia resin bonded fixed dental prosthesis (RBFDPs) to dental substrates would be a major problem for the long term success of such prostheses [20].

Glass ceramics have the benefit of well established, predictable adhesive cementation and debonding is rarely seen in all ceramic FDP [21]. But the load bearing capacity of glass ceramics may be questionable considering occlusal forces. However lithium disilicate reinforced glass-ceramics have a moderate flexural strength and fracture toughness which is acceptable for most of the anterior and some of the posterior restorations [22]. Although zirconia fulfills mechanical requirements for stress bearing restorations, reinforced glass ceramics also can be satisfying with proper restoration design, material thickness and luting agent combinations. With the correct design and framework material choice, all ceramics seem to be the most appropriate material for the replacement of missing anterior teeth, where dental implants are contraindicated [5, 21, 23, 24].

In this case report; manufacturing of chairside overcemented RBFDP with the materials and the advantages of digital CAD/CAM dentistry have been presented.

CASE REPORT

A 22 year-old male patient referred to the prosthodontics department with maxillary lateral teeth agenesis (Figure 1).

After orthodontic treatment, the patient was obliged to use lateral teeth added Hawley retainer until completion of his prosthetic treatment for the maintenance of the space. Considering treatment options, implant rehabilitation was rejected because of the inadequate bone volume and the patient's disapproval for advanced surgical procedures for hard and soft tissue augmentation. Therefore, single tooth retained,

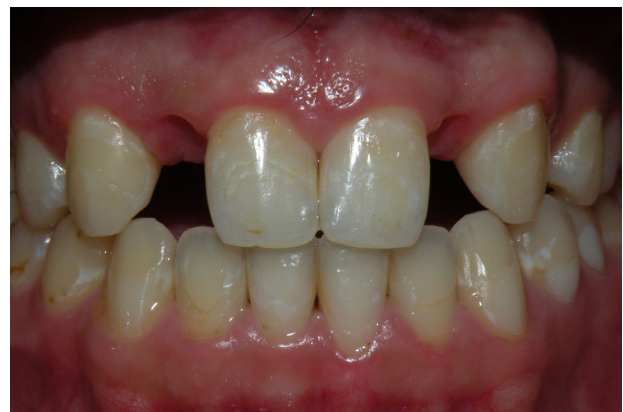

Figure 1 - Anterior view of the patient with lateral agenesis.

chairside, no-prep RBFDP through CAD/CAM technology was decided to be fabricated. Before starting prosthetic stages, the patient underwent a gingival correction operation, for gingival zenith positioning of lateral teeth gaps since their alignment was below the existing anterior teeth's gingival margin lines. For maintenance of gingival positions after the operation, resin composite forming an ovoid pontic design upon the gingival parts of lateral teeth existing on the Hawley retainer was added. Considering interocclusal relationships, palatal surfaces of both maxillary canine teeth were used for cementation surfaces. After the gingival healing period, digital impressions were captured (CEREC AC Bluecam, Dentsply Sirona) and prepared for computer aided design. The substructure of the restorations were designed digitally (Figure 2 and 3); the data were transferred to a software (CEREC SW 4.2.3 Dentsply Sirona), and fabricated in the milling device (CEREC MC XL, Dentsply Sirona) using lithium disilicate based glass-ceramic blocks (IPS e.max CAD C14, Ivoclar Vivadent).

After the milling process was completed, adaptation of the substructure with canine teeth and interocclusal relationships with antagonist teeth were controlled intraorally.

Corrections of the substructures were made where necessary followed by crystallization procedures. Palatal enamel surfaces of canines were etched for 30 seconds with %37 phosphoric acid (Total Etch, Ivoclar Vivadent), then rinsed for 20 seconds with water spray. Simultaneously ceramic surfaces were etched with 9.5% hydrofluoric acid (HF) gel (Ultradent Porcelain Etch) for 20 seconds and silanated (Monobond Plus, Ivoclar Vivadent) for 60 seconds and then air dried. Primer (Syntac Primer, Ivoclar Vivadent) and adhesive (Syntac Adhesive, Ivoclar Vivadent) were applied on etched enamel surfaces followed by bonding agent (Heliobond, Ivoclar Vivadent) application on both enamel and ceramic surfaces. Ceramic surface was lined with a dual curing resin cement (Variolink II, Ivoclar Vivadent), placed on abutment teeth and excess of the material was removed with a pellet carefully before light polymerization for 40 seconds (Bluephase, Ivoclar Vivadent). For the suprastructures, designs were made in laminate veneer restoration forms (Figure 4 and 5) and milled using leucite based glass-ceramic polychromatic-multi blocks (IPS Empress CAD

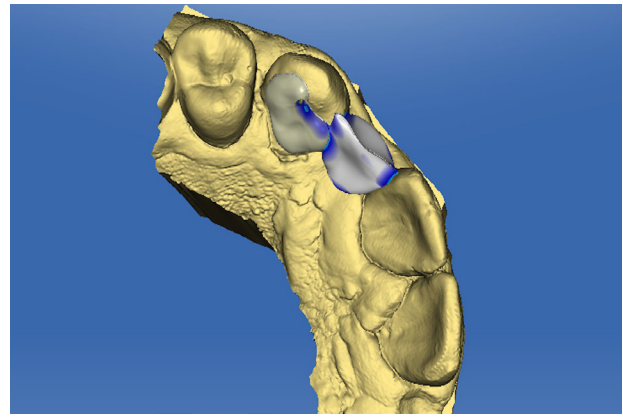


Figure 2 - Computer-aided design of the substructure.

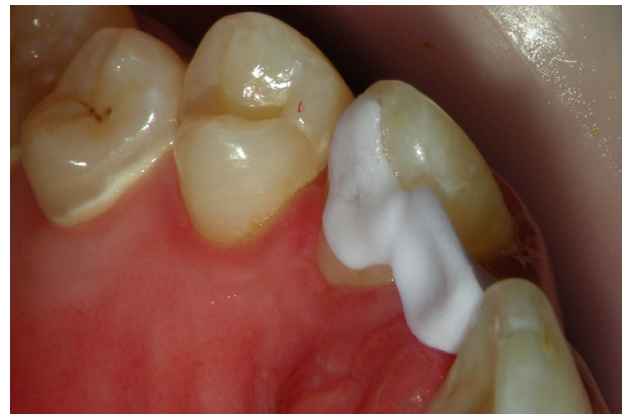

Figure 3 - Try-in of the lithium disilicate substructure before crystallization.

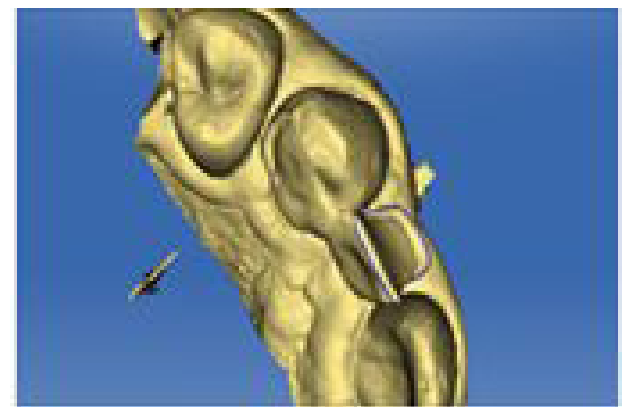

Figure 4 - Digital marginal drawing of the suprastructure.

Multi, Ivoclar Vivadent) to imitate the color gradient between the cervical and incisal edge of natural teeth.

Adaptation with adjacent teeth and substructure was controlled and subsequently glazed. Lithium disilicate based ceramic substructures were etched with 9.5% HF gel for 20 seconds, washed and dried while protecting the oral mucosa with cotton rolls and suctioning.

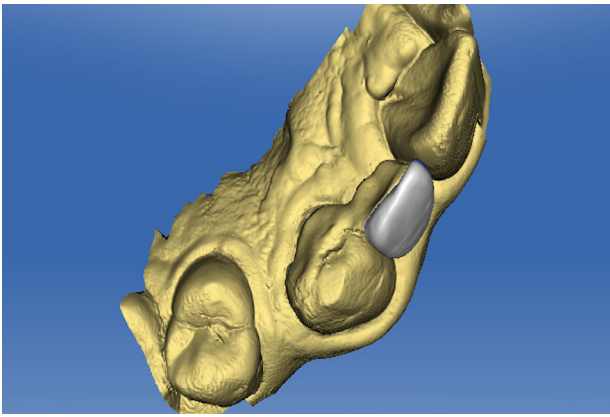


Figure 5 - Computer-aided design of the suprastructure.

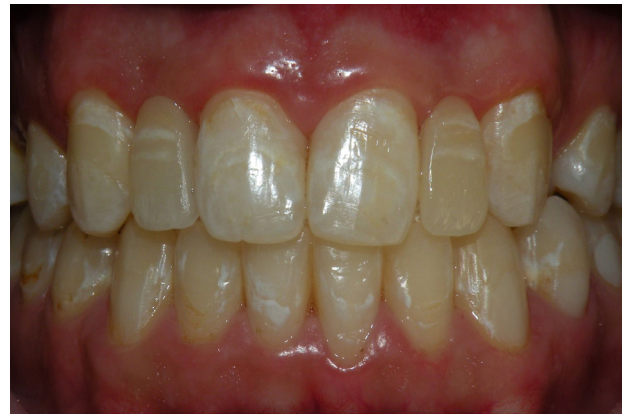

Figure 7 - Anterior view of the final restorations.

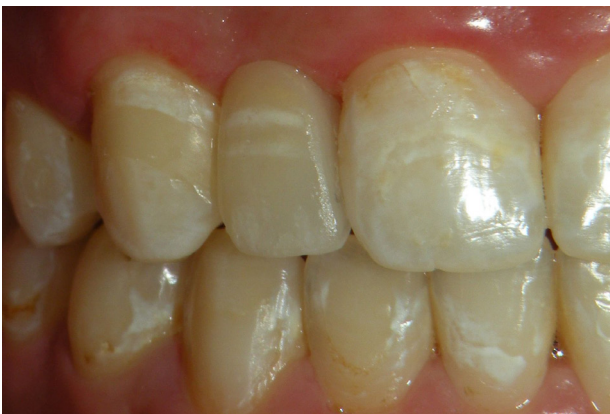

Figure 6 - Right RBFDP after adhesive cementation.

Leucite based glass-ceramic suprastructures were etched with 9.5% HF for 40 seconds, simultaneously. Both surfaces were silanated for 60 seconds (Monobond Plus, Ivoclar Vivadent) and air dried. Bonding agent (Heliobond, Ivoclar Vivadent) was applied, air-thinned and pieces were cemented to each other with dual curing resin cement (Variolink II, Ivoclar Vivadent). Excess cement was removed with an applicator and light polymerization was made for 40 seconds from all aspects of the restorations. Final views of the restorations are shown in Figure 6 and 7.

As lithium disilicate reinforced glass-ceramics are not yet indicated for the fabrication of RBFDPs by the manufacturers, the patient was informed about the treatment procedures and failure possibilities in the long term and alternative treatment modalities were guaranteed in case of any failure requiring remaking of the restorations. Informed consent form was obtained from the patient. The patient was recalled after 1 week, 6 and 12 months for controls or any complaints, and the patient reported to be comfortable.

DISCUSSION

The case in this clinical report revealed successful outcome after 1 year and used the advantages of both minimally or noninvasive RBFDPs and digital restoration fabrication procedures, simultaneously. Previously, the success of RBFDPs and CAD/CAM restorations were all reported [1, 5, 6, 16, 17, 25]; however combined chairside use of these methods and materials with modified framework and suprastructure design was rarely, otherwise not reported.

Anterior missing teeth are mainly due to congenital agenesis [26]. Initial orthodontic treatment is usually needed for agenesis patients to adjust the proportions of each tooth space. Space opening or enclosure can be considered according to patients' needs and demands. For both options; surgical, prosthodontics, restorative or combined treatments are needed afterwards to achieve desired esthetic results. Enclosure of the gap may lead to anesthetic appearance especially in maxillary lateral agenesis patients due to prominence and irregular gingival margins of the canines [13]. When orthodontic space opening is indicated for replacement of the missing teeth, treatment options like implant supported restorations, removable restorations, conventional FDP, or RBFDP are present.

Single-tooth implants are commonly used for replacement of congenitally missing teeth. However, anterior region implant approaches generally require additional surgical interventions such as hard and soft tissue augmentations to achieve ideal functional and esthetic results [11,12]. If such surgical operations are not indicated for medical or economic reasons, other conservative treatment options should be

taken into consideration. RBFDPs have been used for the replacement of missing incisors for a long time [27].

In a clinical study comparing ≥ 5 year success rate of implant supported single crown restorations and 2-unit RBFDPs, resin bonded FDP had higher survival rates considering biological or mechanical complications observed in 5-10 years [15].

A 10-year clinical study of FDP cemented on no-prep teeth surfaces with adhesive resin cements exhibited clinically acceptable results including high patient satisfaction with no caries or hypersensitivity. With the advances in adhesive dentistry and choosing the right indication, it is possible to perform long term esthetic and functional restorations without any tooth reduction [28]. In this case report, no-prep 2-unit cantilevered restorations were fabricated and a patient with anterior region agenesis was chosen to limit occlusal forces.

Several studies revealed RBFDPs with two adjacent teeth retainers had a high percentage of fracture or debonding compared to single tooth retainer containing RBFDPs [2-5, 21, 29]. A study of 3D finite element analysis demonstrated that two-retainer RBFDP showed less stress accumulation than 2-unit (cantilevered) RBFDP since two retainers make the restoration and teeth integrity more rigid. During occlusal forces, a rigid system leads to more stress accumulation on retainer and abutment connection area. [29]. Similar to our material choice, lithium disilicate reinforced glass-ceramic RBFDPs were taken into consideration in the study mentioned previously.

Metal-framed adhesive FDP, fiber-reinforced composite FDP, zirconia-framed adhesive FDP or all-ceramic FDP have been used for anterior region single missing teeth replacements. Although metal-framed RBFDPs have been used for more than 30 years; debonding, veneering ceramic failures or poor esthetics have been reported [2-4, 6, 19, 30]. Fiber-reinforced composite (FRC) FDP, thus have been an option where such disadvantages as well as greyish color reflection from the metal substructure exist. On the other hand, FRCFDP, in the long-term, have been shown to present mechanical failures such as wear, fractures and color changes affecting the esthetic outcome [19, 30]. The findings of a 5-year clinical study of 3-unit FRCFDP in the posterior region showed a success rate of

71% [31], while another 5-year clinical study for anterior region 3-unit FRCFDP showed a success rate of %45 [32]. These contradictory results point out that FRCFDP may be a good alternative for temporary restorations but need more studies to support their long-term use.

There are also studies supporting zirconia use for adhesive FDP framework due to its enhanced optical and mechanical properties [3, 33, 34]. In a clinical study evaluating 10-year outcome of 2-unit, cantilevered RBFDPs made of zirconia reported a high rate of success (92.0%) [10] that is similar to another 15-year clinical study evaluating 2-unit, cantilevered RBFDPs made of glass-infiltrated alumina ceramic. The 10-year survival rates of RBFDPs made of glass-infiltrated alumina ceramic were 95.4% [4]. Considering the long-term success of clinical studies, RBFDPs made of zirconia need tooth preparation to avoid adhesive failures [6, 10, 33, 34]. In this case series, unlike other studies mentioned previously, RBFDPs were planned to be implemented on no-prep tooth surfaces which was important to achieve a proper adhesive bonding making use of enamel presence. As adhesive cementation of silica based ceramics with the application of hydrofluoric acid etching and silanization is well established; [35-38] in this study, lithium disilicate reinforced glass ceramic was chosen for the framework material of RBFDPs. In an *in-vitro* study that compares the fracture resistance of cantilevered RBFDPs fabricated with different materials (lithium disilicate, zirconium oxide and metal ceramic) and designs, reported that most of the RBFDPs fabricated with zirconium oxide failed even at the phase of thermocycling aging. According to the study, lithium disilicate group showed significantly higher fracture strength than zirconium oxide group and showed no difference with the results of metal ceramic group [39].

A systematic review about survival and complication rates of RBFDPs made of different frameworks reported that no debonding was seen in RBFDPs with glass-infiltrated or glass-reinforced ceramic framework [40].

In another systematic review, 5-year success of RBFDPs with different framework materials as metals, zirconia, ceramics and fiber-reinforced composites (FRCs) were investigated. For the metal framework, the success rate was found 88.18%; and for the nonmetal framework as 84.41%. According to the results, five year

successes of RBFDPs were similar to conventional fixed dental prosthesis or implant supported restorations [9].

In a case series study, 35 patients with single-tooth loss in the anterior region were treated with cantilevered veneer retained fixed partial dentures fabricated with lithium disilicate reinforced glass ceramic (IPS e.max Press). The survival rate was 100% at the final follow-up with a mean observation time of 46.57 months. No post-operative sensitivity, dental caries or periodontal disease were recorded in any abutment or adjacent teeth. And the patients' satisfaction degree were high according to visual analog scale recordings with the value of 87,5 [41].

In a retrospective study, 2-unit (cantilevered) posterior and anterior RBFDPs, made from glass ceramic frameworks (%93.3 lithium disilicate reinforced and %6.1 leucite reinforced) were examined. 6-year survival rates of 49 single teeth retained glass ceramic RBFDPs was %100 [21].

Although lithium disilicate glass ceramics' mechanical properties are not superior to zirconia or framework metals, the reported flexural strength of this material is sufficient for anterior RBFDPs [22].

Considering the advantages and disadvantages of above mentioned alternative treatment options, lithium disilicate glass-ceramic blocks were used as a framework material in our clinical report, with their adhesive bonding superiority and esthetic outcomes. High translucent leucite based glass-ceramic block materials were used as a veneering material for optimal esthetic results by an individualized design.

Combining the two glass-ceramic systems with the advantages of CAD/CAM technology; non-invasive, single-visit and esthetic restorations with a low risk of biological complications were achieved in the present report.

CONCLUSIONS

Several treatment options for replacement of anterior missing teeth exist, varying from no-prep adhesive restorations to implants. Patients' biological, psychological, economic conditions or age have an effect on the treatment choice. It is important to perform the most conservative and beneficial treatment option

considering the patient based factors. CAD/CAM manufactured 2-unit RBFDPs are an alternative treatment option for anterior teeth agenesis or trauma patients ended up with single tooth loss, where implant applications are not indicated or preferred.

Author Contributions

Bahar Elter: wrote the paper and performed the clinical procedures.

Akın Aladağ: contributed to the clinical process of the case.

M. Erhan Çömlekoğlu: conceived the ideas of the technique.

Mine Dündar Çömlekoğlu: edited the manuscript according to scientific content.

Conflict of Interest

The authors declare that there is no conflict of interests.

Funding

The authors received no financial support for the research.

Regulatory Statement

The materials used in the study comply with regulatory statement of medical devices in Türkiye.

REFERENCES

1. Botelho MG, Ma X, Cheung GJ, Law RK, Tai MT, Lam WY. Long-term clinical evaluation of 211 two-unit cantilevered resin-bonded fixed partial dentures. *J Dent.* 2014;42(7):778-84. <http://dx.doi.org/10.1016/j.jdent.2014.02.004>. PMID:24685984.
2. Kern M, Sasse M. Ten-year survival of anterior all-ceramic resin-bonded fixed dental prostheses. *J Adhes Dent.* 2011;13(5):407-10. PMID:21935512.
3. Sasse M, Kern M. Survival of anterior cantilevered all-ceramic resin-bonded fixed dental prostheses made from zirconia ceramic. *J Dent.* 2014;42(6):660-3. <http://dx.doi.org/10.1016/j.jdent.2014.02.021>. PMID:24613605.
4. Kern M. Fifteen-year survival of anterior all-ceramic cantilever resin-bonded fixed dental prostheses. *J Dent.* 2017;56:133-5. <http://dx.doi.org/10.1016/j.jdent.2016.11.003>. PMID:27832968.
5. Kern M. Clinical long-term survival of two-retainer and single-retainer all-ceramic resin-bonded fixed partial dentures. *Quintessence Int.* 2005;36(2):141-7. PMID:15732550.
6. Sasse M, Kern M. CAD/CAM single retainer zirconia-ceramic resin-bonded fixed dental prostheses: clinical outcome after 5 years. *Int J Comput Dent.* 2013;16(2):109-18. PMID:23930573.

7. Livaditis GJ, Thompson VP. Etched castings: an improved retentive mechanism for resin-bonded retainers. *J Prosthet Dent.* 1982;47(1):52-8. [http://dx.doi.org/10.1016/0022-3913\(82\)90242-6](http://dx.doi.org/10.1016/0022-3913(82)90242-6). PMID:7033515.
8. Howe DF, Denehy GE. Anterior fixed partial dentures utilizing the acid-etch technique and a cast metal framework. *J Prosthet Dent.* 1977;37(1):28-31. [http://dx.doi.org/10.1016/0022-3913\(77\)90187-1](http://dx.doi.org/10.1016/0022-3913(77)90187-1). PMID:318693.
9. Alraheam IA, Ngoc CN, Wiesen CA, Donovan TE. Five-year success rate of resin-bonded fixed partial dentures: a systematic review. *J Esthet Restor Dent.* 2019;31(1):40-50. <http://dx.doi.org/10.1111/jerd.12431>. PMID:30302909.
10. Kern M, Passia N, Sasse M, Yazigi C. Ten-year outcome of zirconia ceramic cantilever resin-bonded fixed dental prostheses and the influence of the reasons for missing incisors. *J Dent.* 2017;65:51-5. <http://dx.doi.org/10.1016/j.jdent.2017.07.003>. PMID:28688950.
11. Avila ED, Molon RS, Mollo FA Jr, Barros LA, Capelozza L Fo, Cardoso MA, et al. Multidisciplinary approach for the aesthetic treatment of maxillary lateral incisors agenesis: thinking about implants? *Oral Surg Oral Med Oral Pathol Oral Radiol.* 2012;114(5):e22-8. <http://dx.doi.org/10.1016/j.oooo.2011.09.023>. PMID:23083483.
12. Kinzer GA, Kokich VO Jr. Managing congenitally missing lateral incisors. Part III: single-tooth implants. *J Esthet Restor Dent.* 2005;17(4):202-10. <http://dx.doi.org/10.1111/j.1708-8240.2005.tb00116.x>. PMID:16231491.
13. Rosa M, Zachrisson BU. Integrating esthetic dentistry and space closure in patients with missing maxillary lateral incisors. *JCO.* 2001;35(4):221-34. PMID:11345569.
14. Djemal S, Setchell D, King P, Wickens J. Long-term survival characteristics of 832 resin-retained bridges and splints provided in a post-graduate teaching hospital between 1978 and 1993. *J Oral Rehabil.* 1999;26(4):302-20. <http://dx.doi.org/10.1046/j.1365-2842.1999.00374.x>. PMID:10232858.
15. Lam WY, Botelho MG, McGrath CP. Longevity of implant crowns and 2-unit cantilevered resin-bonded bridges. *Clin Oral Implants Res.* 2013;24(12):1369-74. <http://dx.doi.org/10.1111/clr.12034>. PMID:23025467.
16. Duarte S Jr, Phark JH, Tada T, Sadan A. Resin-bonded fixed partial dentures with a new modified zirconia surface: a clinical report. *J Prosthet Dent.* 2009;102(2):68-73. [http://dx.doi.org/10.1016/S0022-3913\(09\)00086-9](http://dx.doi.org/10.1016/S0022-3913(09)00086-9). PMID:19643219.
17. Durey KA, Nixon PJ, Robinson S, Chan MF. Resin bonded bridges: techniques for success. *Br Dent J.* 2011;211(3):113-8. <http://dx.doi.org/10.1038/sj.bdj.2011.619>. PMID:21836574.
18. Pihlaja J, Napankangas R, Raustia A. Early complications and short-term failures of zirconia single crowns and partial fixed dental prostheses. *J Prosthet Dent.* 2014;112(4):778-83. <http://dx.doi.org/10.1016/j.prosdent.2014.03.008>. PMID:24840907.
19. Behr M, Rosentritt M, Handel G. Fiber-reinforced composite crowns and FPDs: a clinical report. *Int J Prosthodont.* 2003;16(3):239-43. PMID:12854785.
20. Kern M. Bonding to oxide ceramics-laboratory testing versus clinical outcome. *Dent Mater.* 2015;31(1):8-14. <http://dx.doi.org/10.1016/j.dental.2014.06.007>. PMID:25059831.
21. Sailer I, Bonani T, Brodbeck U, Hammerle CH. Retrospective clinical study of single-retainer cantilever anterior and posterior glass-ceramic resin-bonded fixed dental prostheses at a mean follow-up of 6 years. *Int J Prosthodont.* 2013;26(5):443-50. <http://dx.doi.org/10.11607/ijp.3368>. PMID:23998142.
22. Penteado MM, Tribst JPM, Jurema ALB, Saavedra G, Borges ALS. Influence of resin cement rigidity on the stress distribution of resin-bonded fixed partial dentures. *Comput Methods Biomech Biomed Engin.* 2019;22(10):953-60. <http://dx.doi.org/10.1080/10255842.2019.1609456>. PMID:31045456.
23. Ma L, Guess PC, Zhang Y. Load-bearing properties of minimal-invasive monolithic lithium disilicate and zirconia occlusal onlays: finite element and theoretical analyses. *Dent Mater.* 2013;29(7):742-51. <http://dx.doi.org/10.1016/j.dental.2013.04.004>. PMID:23683531.
24. Heck K, Paterno H, Lederer A, Litzenburger F, Hickel R, Kunzelmann K-H. Fatigue resistance of ultrathin CAD/CAM ceramic and nanoceramic composite occlusal veneers. *Dent Mater.* 2019;35(10):1370-7. <http://dx.doi.org/10.1016/j.dental.2019.07.006>. PMID:31351578.
25. Blatz MB, Vonderheide M, Conejo J. The effect of resin bonding on long-term success of high-strength ceramics. *J Dent Res.* 2018;97(2):132-9. <http://dx.doi.org/10.1177/0022034517729134>. PMID:28876966.
26. Coster PJ, Marks LA, Martens LC, Huysseune A. Dental agenesis: genetic and clinical perspectives. *J Oral Pathol Med.* 2009;38(1):1-17. <http://dx.doi.org/10.1111/j.1600-0714.2008.00699.x>. PMID:18771513.
27. Kern M, Knode H, Strubb JR. The all-porcelain, resin-bonded bridge. *Quintessence Int.* 1991;22(4):257-62. PMID:1891598.
28. Piemjai M, Ozcan M, Garcia-Godoy F, Nakabayashi NA. 10-year clinical evaluation of resin-bonded fixed dental prostheses on no-prepared teeth. *Eur J Prosthodont Restor Dent.* 2016;24(2):63-70. PMID:27424337.
29. Dal Piva AMO, Tribst JPM, Saavedra G, Souza ROA, Melo RM, Borges ALS, et al. Short communication: influence of retainer configuration and loading direction on the stress distribution of lithium disilicate resin-bonded fixed dental prostheses: 3D finite element analysis. *J Mech Behav Biomed Mater.* 2019;100:103389. <http://dx.doi.org/10.1016/j.jmbbm.2019.103389>. PMID:31398693.
30. Bohlsen F, Kern M. Clinical outcome of glass-fiber-reinforced crowns and fixed partial dentures: a three-year retrospective study. *Quintessence Int.* 2003;34(7):493-6. PMID:12946066.
31. Van Heumen CC, Tanner J, Van Dijken JW, Pikaar R, Lassila LV, Creugers NH, et al. Five-year survival of 3-unit fiber-reinforced composite fixed partial dentures in the posterior area. *Dent Mater.* 2010;26(10):954-60. <http://dx.doi.org/10.1016/j.dental.2010.05.010>. PMID:20638712.
32. Van Heumen CC, Van Dijken JW, Tanner J, Pikaar R, Lassila LV, Creugers NH, et al. Five-year survival of 3-unit fiber-reinforced composite fixed partial dentures in the anterior area. *Dent Mater.* 2009;25(6):820-7. <http://dx.doi.org/10.1016/j.dental.2009.01.103>. PMID:19339043.
33. Klink A, Huttig F. Zirconia-based anterior resin-bonded single-retainer cantilever fixed dental prostheses: a 15- to 61-month follow-up. *Int J Prosthodont.* 2016;29(3):284-6. <http://dx.doi.org/10.11607/ijp.4220>. PMID:27148991.
34. Sailer I, Hammerle CH. Zirconia ceramic single-retainer resin-bonded fixed dental prostheses (RBFDPs) after 4 years of clinical service: a retrospective clinical and volumetric study. *Int J Periodontics Restorative Dent.* 2014;34(3):333-43. <http://dx.doi.org/10.11607/prd.1842>. PMID:24804284.
35. Della Bona A, Van Noort R. Ceramic surface preparations for resin bonding. *Am J Dent.* 1998;11(6):276-80. PMID:10477978.
36. Sudré JP, Salvio LA, Baroudi K, Sotto-Maior BS, Melo-Silva CL, Assis NMSP. Influence of surface treatment of lithium disilicate on roughness and bond strength. *Int J Prosthodont.* 2020;33(2):212-6. <http://dx.doi.org/10.11607/ijp.6453>. PMID:32069346.
37. Maier E, Bordihn V, Belli R, Taschner M, Petschelt A, Lohbauer U, et al. New approaches in bonding to glass-ceramic: self-etch glass-ceramic primer and universal adhesives. *J Adhes Dent.* 2019;21(3):209-17. PMID:31165103.
38. Lee H-Y, Han G-J, Chang J, Son H-H. Bonding of the silane containing multi-mode universal adhesive for lithium disilicate

- ceramics. *Restor Dent Endod.* 2017;42(2):95-104. <http://dx.doi.org/10.5395/rde.2017.42.2.95>. PMID:28503474.
39. Gresnigt MMM, Tirlet G, Bosnjak M, Van Der Made S, Attal JP. Fracture strength of lithium disilicate cantilever resin bonded fixed dental prosthesis. *J Mech Behav Biomed Mater.* 2020;103:103615. <http://dx.doi.org/10.1016/j.jmbbm.2019.103615>. PMID:32090939.
40. Thoma DS, Sailer I, Ioannidis A, Zwahlen M, Makarov N, Pjetursson BE. A systematic review of the survival and complication rates of resin-bonded fixed dental prostheses after a mean observation period of at least 5 years. *Clin Oral Implants Res.* 2017;28(11):1421-32. <http://dx.doi.org/10.1111/clr.13007>. PMID:28191679.
41. Sun Q, Chen L, Tian L, Xu B. Single-tooth replacement in the anterior arch by means of a cantilevered IPS e.max Press veneer-retained fixed partial denture: case series of 35 patients. *Int J Prosthodont.* 2013;26(2):181-7. <http://dx.doi.org/10.11607/ijp.3102>. PMID:23476915.

Bahar Elter
(Corresponding address)

Istanbul Okan University, Faculty of Dentistry, Department of Prosthodontics Tuzla,
Istanbul, Turkey
E-mail: baharelter@gmail.com

Date submitted: 2021 Mar 08
Accept submission: 2021 May 31