



Recurring oral erythema multiforme-like lesions elicited by COVID-19 infection: a case report

Lesões semelhantes a eritema multiforme oral recorrente induzidas por infecção por COVID-19: relato de caso

Mohammed Sultan AL-AK'HALI^{1,2} , Esam HALBOUB³ , Wael IBRAHEEM⁴ , Hamza Khalid KHAN⁵,
Abdulkreem Mohammed HUMMADI⁵

1 - Jazan University, College of Dentistry, Department of Preventive Dentistry. Jazan, Saudi Arabia.

2 - Sana'a University, Faculty of Dentistry, Department of Periodontology. Sana'a, Yemen.

3 - Jazan University, College of Dentistry, Department of Maxillofacial Surgery and Diagnostic Sciences. Jazan, Saudi Arabia.

4 - Jazan University, College of Dentistry, Department of Preventive Dental Sciences. Jazan, Saudi Arabia.

5 - Jazan University, College of Dentistry. Jazan, Saudi Arabia.

ABSTRACT

Oral mucosa could be the first site infected with severe acute respiratory syndrome coronavirus 2 (SARS-CoV-2) –the causative agent of coronavirus disease 2019 (COVID-19). Indeed, different oral and paraoral lesions, conditions and symptoms have been reported in patients with COVID-19. Experts thought that such oral lesions could be secondary to the COVID-19-associated deterioration of systemic health or due to treatments of COVID-19. We present here a case of a 24-year-old male presented with painful multiple ulcers involving the labial and buccal mucosae bilaterally after a while of feeling very mild symptoms that laboratory-confirmed by reverse-transcription polymerase chain reaction to be COVID-19. Involvement of eyes was also reported. The above clinical presentation was consistent with minor erythema multiform. Many topical preparations were prescribed but with limited improvement. Hence, oral prednisolone was prescribed with a 40-mg loading dose that was tapered by 10 mg every 3 days. Complete healing of oral mucosa was observed on the 10 day. Strikingly, the patient got affected with the second episode of similar oral lesions 5 months later without any apparent triggering factors, suggestive a long term effects of COVID-19 in a subset of patients. The present case report provides dentists with useful information and increases their awareness regarding possible involvement of oral cavity with multiple ulcerative lesions associated with COVID-19.

KEYWORDS

Oral erythema multiforme; Oral manifestations; COVID-19; Case report.

RESUMO

A mucosa oral pode ser o primeiro local infectado com a síndrome respiratória aguda grave coronavírus 2 (SARS-CoV-2) – o agente causador da doença por coronavírus 2019 (COVID-19). De fato, diferentes lesões, condições e sintomas orais e paraorais foram relatados em pacientes com COVID-19. Os especialistas pensavam que essas lesões orais poderiam ser secundárias à deterioração da saúde sistêmica associada ao COVID-19 ou devido a tratamentos do COVID-19. Apresentamos aqui um caso de um homem de 24 anos que apresentou múltiplas úlceras dolorosas envolvendo bilateralmente as mucosas labial e bucal após um tempo sentindo sintomas muito leves que foram confirmados laboratorialmente pela reação em cadeia da polimerase de transcrição reversa como COVID-19. O envolvimento dos olhos também foi relatado. A apresentação clínica acima foi compatível com eritema multiforme menor. Muitas preparações tópicas foram prescritas, mas com melhora limitada. Assim, foi prescrito prednisolona oral com uma dose inicial de 40 mg que foi reduzida em 10 mg a cada 3 dias. A cicatrização completa da mucosa oral foi observada no 10º dia. Surpreendentemente, o paciente foi afetado com o segundo episódio de lesões orais semelhantes 5 meses depois, sem nenhum fator desencadeante aparente, sugerindo

efeitos de longo prazo do COVID-19 em um subconjunto de pacientes. O presente relato de caso fornece aos dentistas informações úteis e aumenta sua conscientização sobre o possível envolvimento da cavidade oral com múltiplas lesões ulcerativas associadas ao COVID-19.

PALAVRAS-CHAVE

Eritema multiforme; Manifestações bucais; COVID-19; Relatos de casos.

INTRODUCTION

Since the first case, coronavirus disease 2019 (COVID-19) has been a great affliction worldwide. Apart from the classical symptoms of COVID-19 [1], several cutaneous findings have been reported including maculopapular, rash, erythema multiforme (EM)-like, urticarial, varicella-like, purpuric, and lichenoid lesions[2-4]. With regard to oral and paraoral manifestations, ageusia and anosmia (gustatory and olfactory disorders) are repeatedly reported by COVID-19 patients [5], while other oral manifestations were seldom reported, despite the fact that many suspect that oral mucosa lesions could be the first signs of COVID-19 to arise [6]. Oral lesions like aphthous, herpes, erythema multiform may develop in difficult situations like hard life style, work pressure, and social life restrictions as during COVID-19 pandemic lockdown[7-9]. EM-like lesions may result from drugs administered to treat COVID-19 such as hydroxychloroquine [10] or corticosteroids [11]. EM is a rare acute mucocutaneous condition which considered a delayed-type hypersensitivity response [12] activated in 90% of cases by infectious agents [13]. Approximately 70% of patients with EM have mucosal manifestations, mostly affecting buccal mucosa, lips and/or the tongue, and may include the conjunctiva and/or genitalia [14]. EM lesions usually resolve spontaneously in one to four weeks [14]. Although oral signs and symptoms in COVID-19 patients are, as yet, just a possibility, it seems possible that SARSCoV-2 may irritate oral mucosa causing lesions which are commonly missed due to a lack of intraoral examination in these patients. A few reports on EM-like lesions among COVID-19 patients were published [2,11,15]. Thus accurate examination and documentation of the related oral lesions may play a significant role in the early diagnosis and appropriate management of the disease. We present here a case for COVID-19 patient who suffered two episodes of EM-like lesions with a five-month, lesions-free interval in between.

CASE REPORT

A 24-year-old non-smoker male patient was diagnosed with COVID-19 on 16 August 2020. Upon confirming his status as positive using reverse-transcription polymerase chain reaction, he was instructed to isolate himself at home for two weeks. His past medical history revealed the he has asthma. The COVID-19-associated symptoms of fever and weakness started on 8 August 2020. First, his temperature started rising at 7 o'clock in the morning, and improved in the afternoon. The weakness started later on. These symptoms lasted for 3 days and rapidly respond to two tablets paracetamol 500 mg orally every 4 to 6 hours for three days. He didn't use any other medications. The patient reported development of erythematous eye lesions with blurry vision one week after the self-isolation; these lesions lasted for 5-6 days. Although he was advised to consult an ophthalmologist, he ignored that, and hence he did not receive any medication for eye lesions in the first episode. By the end of the self-isolation period and recovery of the eye lesions, many oral ulcers developed without any apparent mechanical trauma or alike. He reported that the lesions appeared first as redness on the buccal mucosa and as vesicles on the vermillion borders of the lips which later on ulcerated to form irregular and superficial ulcers (Figure 1A, B), with crusting and bloody vermillion borders. These lesions were painful and caused difficulties on eating, swallowing and tooth brushing. The patient sought treatment in public health centre where his complete blood count test was within normal limits, and the physician suggested referral to ophthalmologist and dentist. On 7th September 2020 he came to the College of Dentistry, Jazan University. Upon clinical examination, many irregular superficial ulcerative lesions were observed on the buccal and labial mucosa bilaterally (Figure 1C, D). Upon questioning the patient and manipulating these mucosae, he reported mild pain. Mild dysarthria was also observed. The patient didn't report previous similar lesions, and there was

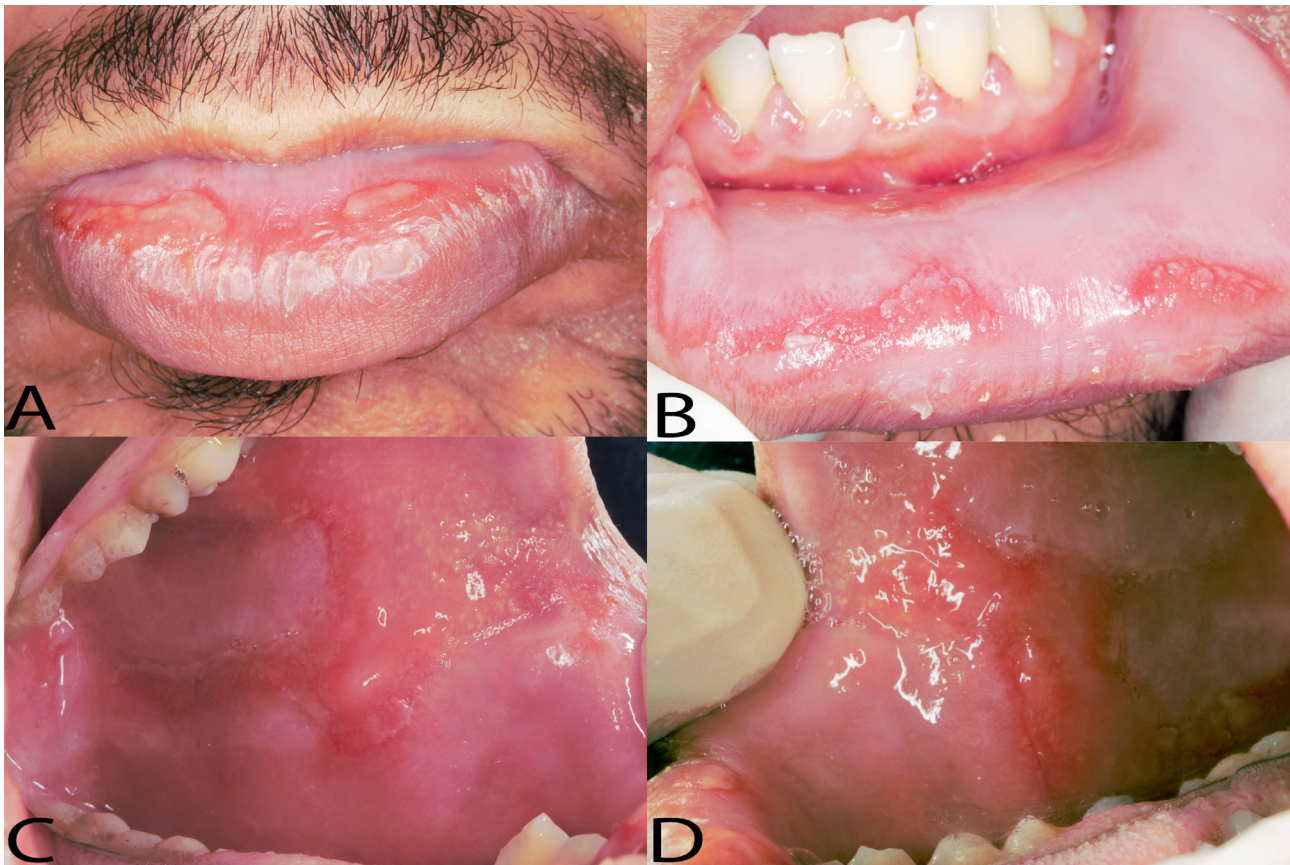


Figure 1 - The oral lesions on the lips (A and B), and on buccal and labial mucosa bilaterally (C and D).

no clear history of herpetic infection. Based on the history and clinical features of the lesions, a provisional diagnosis of “minor EM” or “EM-like lesions” was proposed. For treatment of the oral lesions, antiseptic mouthwashes, antifungal and topical anesthetic were applied for two weeks. As no improvement was seen, Kenalog 0.1% (Triamcinolone) in orabase was prescribed. Partial improvement was observed after two weeks from using Kenalog, but the lesion not completely resolved. On 7th October 2020, 5 mg oral prednisolone tablets were prescribed over a 10-day period where the loading dose was 40 mg tapered by 10 mg every 3 days. Within the first 3 days of treatment, considerable improvement was observed; complete healing of oral mucosa was seen 10 days after treatment (Figure 2A-D).

The patient stayed symptoms and lesions-free for nearly five months until a second episode of EM noticeably developed. Obvious redness of the eyes started on 24 February 2021 (Figure 3A). Later on 7 March 2021 bleeding and crusting of the lips and ulcerations of the oral mucosa developed (Figure 3B, C). By that time, the patient was referred for further hematological (cardiac, iron, liver, lipid and renal panels),

viral (HBsAg) and immunological (CMV IgG, CMV IgM, and HSV 1,2 IgG) examinations which revealed that positive results for HSV1 IgG but negative results for HSV2, CMV (IgM and IgG) and normal values for cardiac, iron, liver, lipid and renal panels. For the eye lesions, the patient had consulted ophthalmologist who prescribed Maxitrol drops (neomycin and polymyxin B sulfates and dexamethasone); improvement of the eyes was noticed a few days of the treatment. For labial and oral lesions, the same course of oral prednisolone that was prescribed in the first episode was repeated. Improvement of lesions was noticed a few days after the treatment. Figure 4 summarizes and demonstrates the timeline of the events of progression and regression of both episodes.

Written consent was obtained from the patient indicating his consent to the publication of images of the lesion in his eyes and oral tissues.

DISCUSSION

In point of fact, with COVID-19 everything is anticipated. Few studies highlighted the possible association between COVID-19 and oral

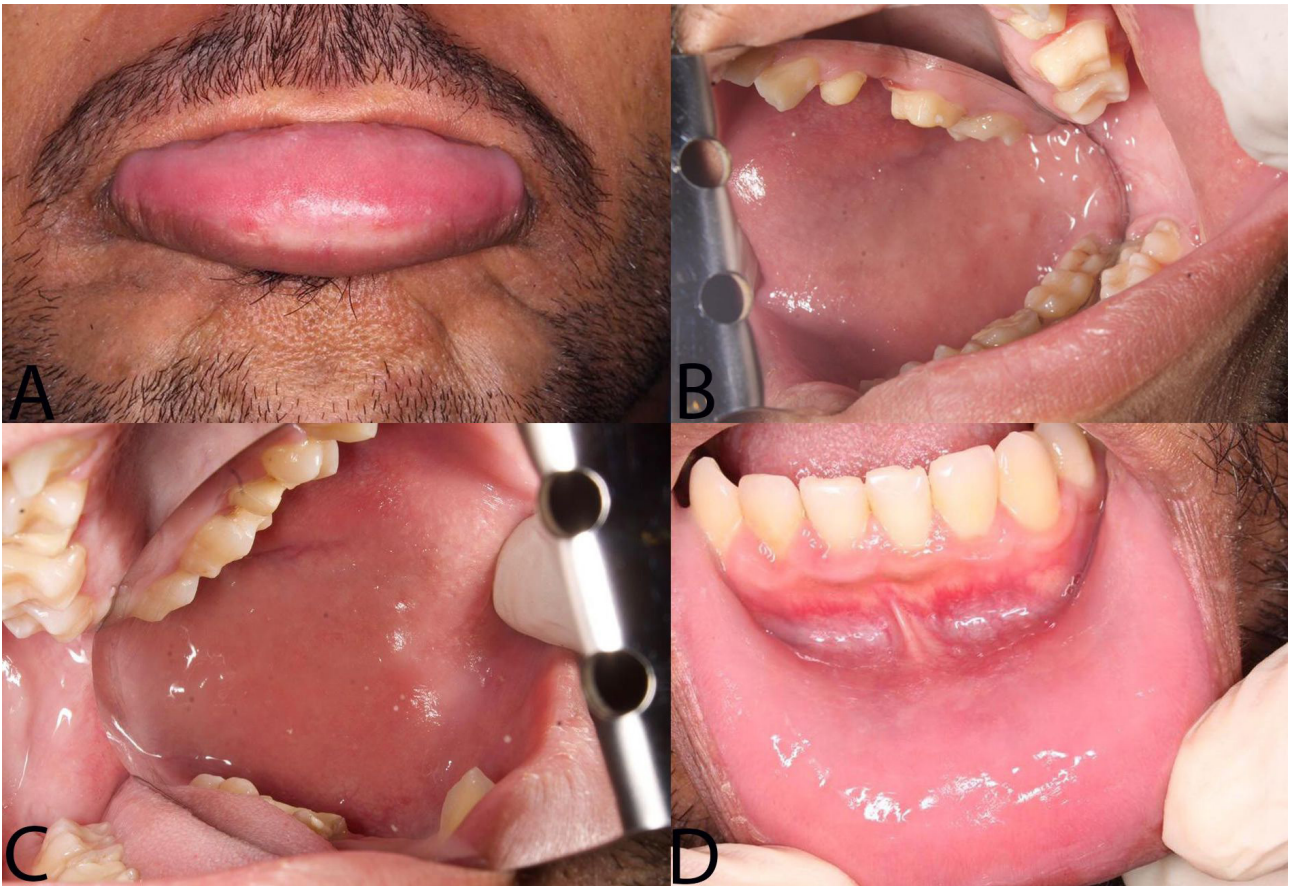

Figure 2 - Healing of lips and oral mucosa after 10 days from treatment.

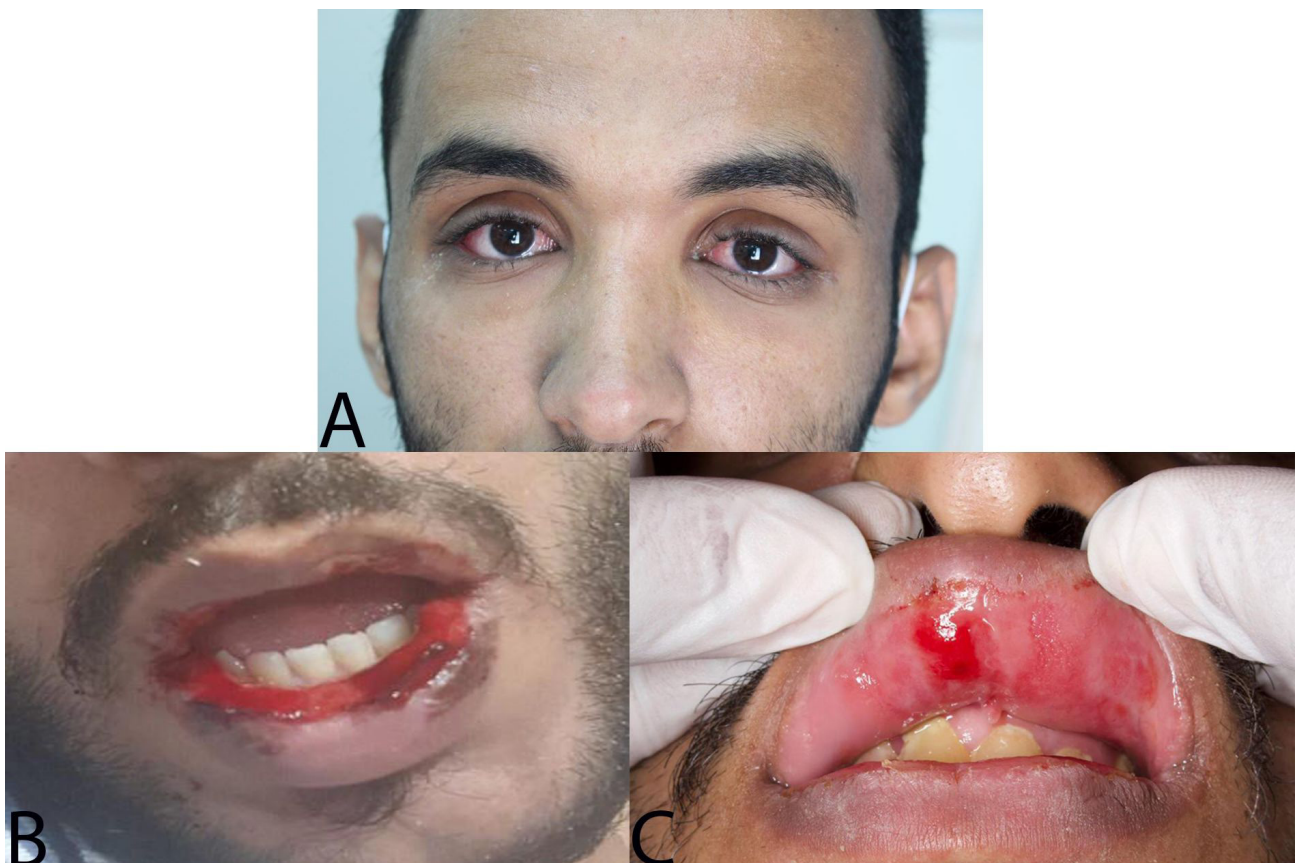

Figure 3 - Recurrence of lesions on the eye (A) and on the lips (B and C).

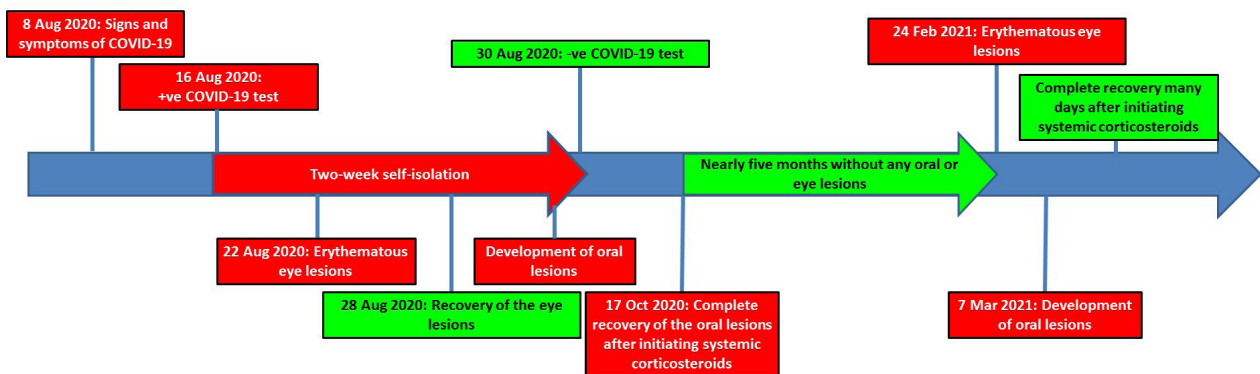


Figure 4 - The timeline of events during the first and second episodes.

ulcerative lesions [9,11,12,16]. Halboub et al. have reviewed the published cases on orofacial manifestations of COVID-19 [17]. EM-like lesions were among these ulcerative lesions which reported in the literature. A recent study conducted in the nidus of the disease (Wuhan, China) on a large sample of COVID-19 positive patients and negative controls has revealed that oral ulceration is one of most common oral problems amid the epidemic [13]. Most frequently EM affects young adults (20–40 years of age) and there is a male predominance [18]. The patient in this case was a male aged 24 years. The mechanism behind these EM-like lesions is unclear. Whether it is a direct effect of the SARSCoV-2; that said the oral cavity is considered one main entrance of the virus transmission and its mucosa is rich in ACE receptors that are used by SARSCoV-2 to get inside the cells in its course of infection [7]. Or these EM-like lesions were developed secondarily to the stress associated with COVID-19 disease or the drugs used to treat it [11,14]. Petrescu et al. claimed that oral mucosa lesions could be the first signs of COVID-19 because the oral mucosa could be the first area infected with COVID-19 [6]. However, in the present case the oral ulcers started later on when the COVID-19-associated symptoms actually faded away. This supports the hypothesis that EM-like lesions were not a direct effect of SARSCoV-2, rather these lesions developed due to the body responses to the COVID-19-induced stress [19,20]. Sinadinos and Shelswell [16] supported the assumption that these lesions are secondarily resulting from the fall of systemic health.

Although a few case reports documented the presence of oral mucosal lesions in patients with COVID-19 infection [21–23], this is the first case that reported development of recurring (two episodes) EM-like lesions elicited by a mild infection with COVID-19. Nevertheless, this case report provides dentists with useful information regarding possible oral symptoms of COVID-19. This in turn will increase awareness among dentists about the importance of oral examination ahead of starting dental therapy. It has been argued that the dentists might be the first to identify suspect SARS-CoV2-positive patients, and hence they could send them to get evaluated and treated properly [6]. So it is important to include the dentists as part of the multi-disciplinary team in treating and supporting patients with COVID-19.

Many limitations have to be mentioned: no histological analysis was performed to confirm the diagnosis EM. No documentation (images or professional examinations) of the lesions of the eyes in the first episode other than what the patient reported. In addition, most of the case history was reported retrospectively regarding the first episode. However, we confirm that we followed-up the patient very closely in the second episode. Further well-designed, large-scaled studies are needed to understand the connection between COVID-19 and oral mucosal lesions and to evaluate if the oral mucosa lesions are considered the first COVID-19 signs, also to evaluate whether these lesions are associated with the virus, the medications, or any other systemic disease.

Acknowledgements

The authors would like to thank the patient for his help and willingness to participate and also for signing the consent.

Author Contributions

MSA: closely followed-up the patient, write the first draft of the manuscript. EH: contributed in treatment, follow up and referral of the patient, and revised the first draft of the manuscript. WI, HKK and AMH: participated in patient follow up and manuscript writing. All authors critically revised the manuscript and approved it.

Conflict of interests

The authors declare that they have no conflict of interests.

Funding

The authors declare that no financial support was received.

Regulatory Statement

This study was conducted in accordance with all the provisions of the local human subjects.

Ethical approval

A prior permission from the Institutional Review Board at College of Dentistry, Jazan University, and a signed consent from the patient had preceded the collection of information and interview for the current case report.

References:

1. Lake MA. What we know so far: COVID-19 current clinical knowledge and research. *Clin Med*. 2020;20(2):124-7. <http://dx.doi.org/10.7861/clinmed.2019-coron>.
2. Janah H, Zinebi A, Elbenay J. Atypical erythema multiforme palmar plaques lesions due to Sars-Cov-2. *J Eur Acad Dermatol Venereol*. 2020;34(8):e373-5. <http://dx.doi.org/10.1111/jdv.16623>.
3. Casas CG, Catala A, Hernández GC, Rodríguez-Jiménez P, Fernández-Nieto D, Rodríguez-Villa Lario A, et al. Classification of the cutaneous manifestations of COVID-19: a rapid prospective nationwide consensus study in Spain with 375 cases. *Br J Dermatol*. 2020;183(1):71-7. <http://dx.doi.org/10.1111/bjd.19163>.
4. Jimenez-Cauhe J, Ortega-Quijano D, Carretero-Barrio I, Suarez-Valle A, Saceda-Corralo D, Moreno-Garcia del Real C, et al. Erythema multiforme-like eruption in patients with COVID-19 infection: clinical and histological findings. *Clin Exp Dermatol*. 2020;45(7):892-5. <http://dx.doi.org/10.1111/ced.14281>.
5. Lechien JR, Chiesa-Estomba CM, Siaty DR, Horoi M, Bon SD, Rodriguez A, et al. Olfactory and gustatory dysfunctions as a clinical presentation of mild-to-moderate forms of the coronavirus disease (COVID-19): a multicenter European study. *Eur Arch Otorhinolaryngol*. 2020;277:2251-2261. <http://dx.doi.org/10.1007/s00405-020-05965-1>.
6. Petrescu N, Lucaciu O, Roman A. Oral mucosa lesions in COVID-19. *Oral Dis*. 2020;00:1-2. <http://dx.doi.org/10.1111/odi.13499>.
7. Guo Y, Yuan C, Wei C. Emergency measures for acute oral mucosa diseases during the outbreak of COVID-19. *Oral Dis*. 2020;27(suppl. 3):737-739.
8. Carreras-Presas CM, Sánchez JA, López-Sánchez AF, Jané-Salas E, Pérez MLS. SARS-CoV-2 oral-associated lesions: discussion of elicited response. *Oral Dis*. 2020;0:1-3. <http://dx.doi.org/10.1111/odi.13532>.
9. Demirbaş A, Elmas ÖF, Atasoy M, Türsen Ü, Lotti T. A case of erythema multiforme major in a patient with COVID 19: the role of corticosteroid treatment. *Dermatol Ther*. 2020;33(6):e13899. <http://dx.doi.org/10.1111/dth.13899>.
10. Robustelli Test E, Vezzoli P, Carugno A, Raponi F, Gianatti A, Rongioletti F, et al. Acute generalized exanthematous pustulosis with erythema multiforme-like lesions induced by Hydroxychloroquine in a woman with coronavirus disease 2019 (COVID-19). *J Eur Acad Dermatol Venereol*. 2020;34(9):e457-9. <http://dx.doi.org/10.1111/jdv.16613>. PMID:32386448.
11. Jimenez-Cauhe J, Ortega-Quijano D, Carretero-Barrio I, Suarez-Valle A, Saceda-Corralo D, Moreno-Garcia del Real C, et al. Erythema multiforme-like eruption in patients with COVID-19 infection: clinical and histological findings. *Clin Exp Dermatol*. 2020;45(7):892-5. <http://dx.doi.org/10.1111/ced.14281>.
12. Jimenez-Cauhe J, Ortega-Quijano D, Perosanz-Lobo D, Burgos-Blasco P, Vañó-Galván S, Fernandez-Guarino M, et al. Enanthem in Patients With COVID-19 and Skin Rash. *JAMA Dermatol*. 2020;156(10):1134. <http://dx.doi.org/10.1001/jamadermatol.2020.2550>.
13. Zhang S, Liu C, Zhang C, Jiang H, Tai B, Du M. Impact of COVID-19 on the oral health of adults in Wuhan and China: results of a nationwide online cross-sectional questionnaire survey. *BMC Oral Health*. 2021;21(1):162. <http://dx.doi.org/10.1186/s12903-021-01533-z>.
14. Thomas P. *Clinical dermatology: a color guide to diagnosis and therapy*. Edinburgh: Elsevier; 2004.
15. Cazzato G, Bosco A, Addante F. Erythema multiforme like lesions covid 19 a case report. *Journal of Medical and Biomedical Discoveries*. 2020;4(1):1-3.
16. Sinadinos A, Shelswell J. Oral ulceration and blistering in patients with COVID-19. *Evid Based Dent*. 2020;21(2):49. <http://dx.doi.org/10.1038/s41432-020-0100-z>.
17. Halboub E, Al-Maweri SA, Alanazi RH, Qaid NM, Abdulrab S. Orofacial manifestations of COVID-19: a brief review of the published literature. *Braz Oral Res*. 2020;34:e124. <http://dx.doi.org/10.1590/1807-3107bor-2020.vol34.0124>.
18. Plaza JA, Prieto V, James W [Internet]. Erythema multiforme. New York: WebMD; 2013 [cited 2021 April 18]. Available from: <https://emedicine.medscape.com/article/1122915-overview>.
19. Chang Y-S, Huang F-C, Tseng S-H, Hsu C-K, Ho C-L, Sheu H-M. Erythema multiforme, Stevens-Johnson syndrome, and toxic epidermal necrolysis: acute ocular manifestations, causes, and management. *Cornea*. 2007;26(2):123-9. <http://dx.doi.org/10.1097/ICO.0b013e31802eb264>.

20. Power WJ, Ghoraihi M, Merayo-Llves J, Neves RA, Foster CS. Analysis of the acute ophthalmic manifestations of the erythema multiforme/Stevens-Johnson syndrome/toxic epidermal necrolysis disease spectrum. *Ophthalmology*. 1995;102(11):1669-76. [http://dx.doi.org/10.1016/S0161-6420\(95\)30811-1](http://dx.doi.org/10.1016/S0161-6420(95)30811-1).
21. Santos JA, Normando AGC, Silva RLC, Paula RM, Cembranel AC, Santos-Silva AR, et al. Oral mucosal lesions in a COVID-19 patient: new signs or secondary manifestations? *Int J Infect Dis*. 2020;97:326-8. <http://dx.doi.org/10.1016/j.ijid.2020.06.012>.
22. Tapia ROC, Labrador AJP, Guimaraes DM, Valdez LHM. Oral mucosal lesions in patients with SARS-CoV-2 infection. Report of four cases. Are they a true sign of COVID-19 disease? *Spec Care Dentist*. 2020;40(6):555-60. <http://dx.doi.org/10.1111/scd.12520>.
23. Nejabi MB, Noor NAS, Raufi N, Essar MY, Ehsan E, Shah J, et al. Tongue ulcer in a patient with COVID-19: a case presentation. *BMC Oral Health*. 2021;21(1):273. <http://dx.doi.org/10.1186/s12903-021-01635-8>.

**Mohammed Sultan Al-Ak'hali
(Corresponding address)**

Jazan University, College of Dentistry, Department of Preventive Dentistry, Jazan,
Saudi Arabia.

Email address: sultanperiodontics@gmail.com

Date submitted: 2021 Apr 18
Accept submission: 2021 Jul 07