Brazilian Dental Science

unesp
UNIVERSIDADE ESTADUAL PAULISTA
"JÚLIO DE MESQUITA FILHO"
Instituto de Ciência e Tecnologia
Campus de São José dos Campos

CC BY

ORIGINAL ARTICLE

DOI: https://doi.org/10.4322/bds.2021.e3039

Survival rate of pulpectomy in primary teeth using Feapex® paste: a clinical study in infants

Sobrevida de pulpectomia em dentes decíduos utilizando pasta Feapex®: um estudo clínico em bebês

Jenny ABANTO[1,2], Isabel Cristina OLEGÁRIO[3], Fausto Medeiros MENDES[4], Marcelo José Strazzeri BÖNECKER[4], Maria Salete Nahás Pires CORRÊA[4]

1 - Universitat Internacional de Catalunya, Departamento de Odontopediatría, Facultad de Odontología, Barcelona, España.
2 - Faculdade de Odontologia da Associação Paulista de Cirurgiões Dentistas (FAOA), Faculdade de Odontologia, São Paulo, Brasil.
3 - Dublin Dental University Hospital, Department of Child & Public Dental Health, Trinity College Dublin, Dublin, Ireland.
4 - Universidade de São Paulo, Departamento de Odontopediatria, Faculdade de Odontologia, São Paulo, Brasil.

ABSTRACT

Objective: The aim of this clinical study was to evaluate the survival rate of a new pulpectomy protocol using 2% chlorhexidine digluconate gel and Feapex® paste for endodontic treatment in primary teeth. **Material and Methods:** A total of 105 pulpectomies were performed in anterior and posterior teeth of 48 infants (1-3 years old) with high caries experience with irreversible pulpitis or pulp necrosis. All treatments were performed by dental surgeons with no specialization in Pediatric Dentistry, under local anesthesia and rubberdam isolation. Manual files were used in conjunction with 2% chlorherixidine gel for root canal instrumentation, and Feapex® paste was used as a obturation material. The clinical and radiographic outcomes were collected by one trained independent evaluator with a follow-up period of 24months. Success was determined by the absence of pain, pathological mobility, pathologic bone rarefaction, pathological root resorption and soft tissue pathology around the affected tooth Survival of the endodontic treatment was evaluated by estimating survival rates through Kaplan-Meier curves. Cox Regression analysis with shared fragility were performed to evaluate the association between the independent variables to endodontic treatment failure (α=5%). **Results:** After 24 months, the treatment survival was 86% (SE=0.03). Root resorption at baseline was associated with a higher risk of failure (HR=2.81; CI=1.12-7.08; p=0.027). The survival rate of the endodontic treated teeth due to dental trauma was 100%, while teeth with dental caries had lower survival rate (85.05%; $p<0.001$*). Other variables analyzed included gender, age of the child, tooth position (incisor/molar), restoration type, obturation quality, and caries experience were not associated with treatment failure ($p>0.05$). **Conclusion:** The new protocol using 2% chlorhexidine digluconate and Feapex® presented a high survival rate and can be considered as a suitable protocol for pulpectomy in primary teeth.Trial Registration: REBEC (RBR-282s2f).

KEYWORDS

Root canal treatment; Primary teeth; Infants; Pulpectomy.

RESUMO

Objetivo: Avaliar a sobrevida de um novo protocolo para tratamento endodôntico (pulpectomia) em dentes decíduos utilizando gel de digluconato de clorexidina 2% e pasta Feapex®. **Material e Métodos:** Um total de 105 pulpectomias foram realizadas em dentes anteriores e posteriores diagnosticados com pulpite irreversível ou necrose pulpar em 48 crianças (1-3 anos de idade) com alta experiência de cárie. Todos os tratamentos foram realizados por cirurgiões-dentistas clínicos gerais, sob anestesia local e isolamento absoluto. Limas manuais foram utilizadas em conjunto com cloroherixidina 2% gel para instrumentação dos canais radiculares e pasta Feapex® foi utilizada como material de obturação. Os resultados clínicos e radiográficos foram coletados por um avaliador independente treinado com um período de acompanhamento de 24 meses. O sucesso foi

determinado pela ausência de dor, mobilidade patológica, rarefação óssea patológica, reabsorção radicular patológica e ausência de fístula/abscesso ao redor do dente tratado. A sobrevida do tratamento endodôntico foi estimativa utilizando curvas de Kaplan-Meier. Análise de regressão de Cox com fragilidade compartilhada foi realizada para avaliar a associação entre as variáveis independentes com a falha do tratamento endodôntico (α = 5%). **Resultados:** Após 24 meses, a sobrevida do tratamento foi de 86% (EP = 0,03). A reabsorção radicular no início do estudo foi associada a um maior risco de falha (HR= 2,81; IC= 1,12-7,08; *p*= 0,027). Dentes tratados endodonticamente devido ao traumatismo dentário na dentição decídua apresentaram taxa de sobrevida de 100%, enquanto dentes com comprometimento pulpar devido à cárie dentária tiveram menor sobrevida (85,05%; *p*<0,001 *). Todas as outras variáveis analisadas como sexo, idade da criança, dente (incisivo/molar), tipo de restauração, qualidade da obturação e experiência de cárie não foram associadas à falha do tratamento (p> 0,05). **Conclusão**: O novo protocolo utilizando digluconato de clorexidina 2% e Feapex® apresentou alta sobrevida e pode ser considerado um protocolo adequado para pulpectomia em dentes decíduos.Registro do estudo clínico: REBEC (RBR-282s2f).

PALAVRAS-CHAVE

Tratamento endodôntico; Dentes decíduos; Bebês; Pulpectomia.

INTRODUCTION

In Brazil, irreversible pulpities and pulp necrosis caused by dental caries and trauma to primary teeth is still very common [1,2]. The last national epidemiological survey indicated that the prevalence of dental caries in the primary dentition is 53.4%, and more than 80% of caries lesions have not been treated at 5 years of age [3]. Untreated dental caries in children can lead to infections involving pulp, abscesses or fistulae [4]. In addition, studies have shown that untreated tooth decay has a negative impact on oral health-related quality of life (OHRQoL) of preschoolers and their parents, compared to caries-free children [5-7].

With regard to the treatment of severe dental caries with pulpal involvement, a systematic review concluded that there is insufficient evidence to support the superiority of one type of treatment for primary molars due to the lack of reliable evidence [8]. At present, there are two clinical approaches for managing infected or necrotic molars: endodontic treatment (pulpectomy in primary teeth) and non-conservative treatment (dental extractions) [8,9]. Both approaches are used around the world in the primary dentition, and the treatment decision is based on different philosophies and socio-cultural contexts due to the lack of evidence on the best approach to treat these teeth between professionals and countries [10,11]. In permanent teeth, a recent systematic review found improval of patients OHRQoL after endodontic treatment [12]. In primary dentition, pulpectomy has gained strength since one of the main purposes of Pediatric Dentistry is the maintenance of the deciduous teeth in the arch under anatomical-functional conditions until the time of its physiological exfoliation [13].

Pulpectomy is recommended for primary teeth with evidence of irreversible chronic pulpal inflammation or in cases of pulpal necrosis, with or without the presence of periapical bone rarefaction in the furcation region. The technique is challenging in primary molars due to anatomical peculiarities such as molar root curvature and a larger number of collateral root canals [14,15]. Due to these difficulties, the chemomechanical preparation is complex, which requires the need to reduce or eliminate the bacteria present mainly with an antimicrobial sealing material that shows good diffusion.

Sodium hypochlorite (NaOCl) is a widely used irrigant solution for root canal disinfection in permanent molars. However, some studies have shown that NaOCl is a potential irritant for periapical tissues, specially in open apex teeth or when used in higher concentration. Another alternative is the use of chlorhexidine digluconate that presents good antiseptic properties, and recommended in case of root resorption and open apex teeth. A recent systematic review [16] that investigated those two irrigant solutions for root canal disinfection could not conclude superiority between groups, since few clinical trials have been reported.

In addition to the irrigant solution, the obturation material play an important role in the survival of endodontic treatment in primary teeth. Ideally this material should be resorbable, not cause damage to the periapical tissues and the permanent germ, have antimicrobial properties, promote adequate padding and adherence to the root canal walls, be easily removed if necessary, have radiopacity and not cause tooth staining [13,17-19]. Zinc Oxide and Eugenol (ZOE) cement has been widely used as a filling material for primary teeth and is the gold standard for comparison [20]. Although ZOE presents high survival rate [21], it has limited antimicrobial action [22] and a tendency to resorb at a slower rate compared to the roots of primary teeth [23,24]. On the other hand, iodoform presents better resorption and disinfectant properties [24,25], whereas calcium hydroxide based pastes exhibit some antimicrobial action and are easily resorbed when inadvertently extruded beyond the apex of the tooth [24,26,27].

A systematic review that evaluated alternatives to ZOE for root canal filling of deciduous teeth concluded that, for pulpectomies, Vitapex® paste (calcium hydroxide and iodoform) can produce better results than ZOE [28]. The Vitapex® paste seems to be currently used as the main material for primary teeth obturation. However, it is not registered in ANVISA (National Health Surveillance Agency) for sale in the Brazilian market. According to the last Cochrane systematic review [29], there is no conclusive evidence that one medicament or technique is superior to another; the choice of medicament remains at the clinician's discretion.

Recently, a new calcium hydroxide and iodoform based paste was developed in Brazil (Feapex®, Formula & Ação, São Paulo, Brazil), presenting similar characteristics to Vitapex® [30]. Feapex® is registered in ANVISA and is available for sale, however, its clinical effectiveness has not yet been proven within longitudinal clinical studies.

Thus, the aim of this study was to evaluate the survival rate of endodontic treatment following a new treatment protocol: 2% chlorhexidine digluconate and Feapex® paste for root filling of primary teeth with pulpal necrosis or irreversible pulpitis in infants.

MATERIALS AND METHODS

Study design and ethical precepts

This is a single-arm controlled clinical trial. This manuscript was written following the guidelines recommended by the Consolidated Standards of Reporting Trials (CONSORT). The study was previously approved by the local Ethics Committee under registration number 1.484.312. The trial protocol was retrospectively registered on the REBEC (*Registro Brasileiro de Ensaios Clínicos*) platform (RBR-282s2f). After clarifying the objectives of the research, only children whose parents agreed to the research and signed the Informed Consent Form were enrolled in the study.

Sample overview and selection

A convenience sample of infants whose parents sought dental care in the Paediatric Dentistry Course at the Fundecto, Dental School, University of São Paulo, between May 2016 and March 2017 participated in the research.

Only children aged 1 year to 3 years and 11 months of age, who presented with an anterior and/or posterior primary teeth diagnosed with pulp necrosis or with irreversible pulpitis were included.

Pulp necrosis was evaluated through the presence of fistula or abscess, bone rarefaction or visual diagnosis through the absence of vital tissue. Only children who completed at least 6 months of clinical and radiographic follow-up were included in the analyses.

The exclusion criteria were as follows: children with systemic and/or neurological diseases; teeth that had dental anomalies, periapical cyst, advanced internal/external resorption (more than 1/3 of the root length), involvement of the permanent successor crypt and presence of less than 2/3 of the root formed in the radiographic examination [24], and teeth that could not be appropriately isolated with a rubber dam. Children whose teeth were significantly broken down and could not be restored-were also excluded.

If the child had more than one tooth suitable for inclusion in the study, all were included, since the experimental sample unit was the tooth.

Endodontic treatment: pulpectomy

In the treatment session (baseline), the selected teeth were radiographed using a conventional device, standardized by using children's radiographic positioners (Jon, Brazil) in a Spectro 70X device (Dabi Atlante, Brazil), with 70 kV and 8 mA regulation, and exposure time of 0.8s. Radiographs were taken using 22x35 mm periapical films (Eastman Kodak, Rochester, USA). The radiographs were then manually processed and were standardized by the time-temperature method. Only radiographs showing all the roots and apices of the tooth in question were accepted.

Treatments were performed with the use of local anesthesia with prior topical anesthesia (Benzotop, Nova DFL, Brazil) in a single session [31,32].

The pulpectomy technique was performed according to the following protocol:

1. Radiography using radiographic positioners for children, whenever possible;

2. Work length determination was done using the baseline radiography, keeping the length 1mm short of the apices;

3. Mandatory use of absolute isolation with rubber dam and use of dental clamps;

4. Removal of the carious tissue and endodontic access with spherical drills of adequate size for access to the pulp chamber. For the determination of the shape of contour, a non-end-cutting bur was used (Endo Z bur);

5. Removal of remains of the coronary pulp with sharp dentin spoon excavator and location of root canals with a probe;

6. Irrigation of the root canal with a physiological saline solution using sterile syringes with Endo-EZE irrigation tips (Ultradent®, Brazil) and white Macs tips (Ultradent®, Brazil);

7. Manual instrumentation using 3 Kerr-type files (initial size + two successive sizes), the first of which is compatible in size with the root canal. All the files were introduced along with 2% chlorhexidine digluconate gel (Cleanform, Formula & Action®, Brazil);

8. Immediately after instrumentation with each of the first two files, the root canal was irrigated using 5 ml of sterile saline solution with the aid of sterile disposable syringe with Endo-Eze Irrigator Tip irrigation tip (Ultradent®, Brazil) and White Mac (Ultradent®, Brazil) thick aspiration tips;

9. Final irrigation was performed after instrumentation with the third file with 20 ml of 17% EDTA (Formula & Ação®, Brazil) for 3 minutes, followed by neutralization with 5 ml of sterile saline with the aid of sterile disposable syringe with Endo-Eze Irrigator Tip (Ultradent®, Brazil);

10. Initial drying was done with White Mac (Ultradent®, Brazil) suction tips, followed by drying of the root canals with Capillary Tips (Ultradent®, Brazil), keeping the length 1mm short of the apices. Subsequently, absorbent paper points were used to completely dry the canals;

11. Root canal filling up to the entrance of the canals was completed with the Feapex® paste (Formula & Ação®, Brazil), using endodontic tips for insertion of the material into the root canals;

12. Application of a thin layer of gutta-percha with the aid of endodontic intracanal condenser with a diameter compatible with the cavity-size;

13. Cleaning of the pulp chamber walls with sterile cotton balls and alcohol,

14. Post-operative radiography using children's radiographic positioners, whenever possible, to evaluate the quality of the obturation.

Restoration of the teeth was carried out in the same session of the endodontic treatment using composite resin or resin-based glass ionomer cement, depending on the operator's choice. No standardized protocol was used for the restorative procedure. In case the restorative treatment needed to be carried out at the next dental appointment, a high-viscosity glass ionomer cement (Riva Self cure, SDI, Australia) was used as a provisional restoration. For anterior teeth, in cases where more than 50% of the restorative crown was compromised, fiberglass-reinforced composite endodontic posts (Reforpost®, Angelus, Brazil) and composite strip crowns (TDV®, Brazil) was used.

If the patients had other dental treatment needs, the integral treatment was provided by the operators of this study.

Since the sample corresponds to an age group from 1 to 3 years old, all patients were treated

using active protective physical immobilization in the body-to-body or saddle position performed by the person responsible for the child to protect the baby from potential accidents, which can be produced by jerking movements of arms and legs.

If the person in charge was unable to perform a good active physical immobilization, passive immobilization was used with the use of a ped wrap, and the person responsible for the child lay down in the chair next to the child to offer emotional support. Non-pharmacological techniques of behavioral approach (talk-show-do, singing, positive reinforcement, non-verbal communication and distraction) were used during all treatments.

Training of operators

All the operators were dental surgeons, with no specialization in Pediatric Dentistry, participating in a continuing professional development course in infant oral healthcare provision.

A pediatric dentist with experience in the area of primary dentition pulp therapy (gold standard - JA) performed the theoretical and laboratory training of the operators. Training consisted of a theoretical class of 4 hours and a preclinical laboratory training session performing the pulpectomy technique, according to the presented protocol, in artificial primary incisor and primary molar teeth (Denarte®, Brazil). In this way, the pulpectomy technique was performed in a standardized way during the research.

Outcomes Assessment

The primary outcome of this trial is the endodontic treatment survival. In order to determine if the treatment would be classified into success or failure, clinical and radiographic criteria were considered. All evaluations were performed by one trained independent evaluator. Patients were reviewed up to 24 months after the treatment. Clinical and radiographic outcomes of the previously treated teeth were evaluated at each follow-up visit.

The clinical and radiographic evaluation criteria were used based on a systematic review (25), as follows:

- Pain: Pain symptoms/Spontaneous pain/ Thermal sensitivity/Pain initiated by stimuli/ Sensitivity to pressure/Tenderness to percussion/Chewing sensitivity/Sensitivity to sour/Sensitivity to sweet/Pain on palpation – palpation sensitivity;
- Pathological mobility: mobility not related to periodontal disease, trauma or natural exfoliation of the tooth;
- Pathological radiolucency: Pathologic radiolucency/Periapical radiolucency/ Lateral radiolucency/Apical radiolucency/ Involvement of the apical area/Radicular radiolucency/Periradicular radiolucency/ Furcal–bifurcation radiolucency/Intra-radicular radiolucency/Bone radiolucency/ Furcation involvement/Periapical bone destruction/Interradicular bone destruction/ Abnormal inter-radicular trabeculation – variation in radiodensity/ Periodontal ligament space widening/Integrity of lamina dura/Loss of trabecular bone/ Abnormalities in the structure of trabecular bone/Bone regeneration;
- Pathological root resorption: Pathologic root resorption/Root resorption in relation to contralateral tooth/Internal root resorption/ Internal root resorption-perforated form/ Internal dentine resorption/ External root resorption/Replacement resorption/Root resorption in relation to contralateral tooth with criteria established by Wright;
- Soft tissue pathology: Swelling/Edema/ Soft tissue pathology-swelling/Extraoral swelling/Intraoral swelling/ Infection in the adjacent tissues/Fistulation – fistula/ Parulis/Abscess/Sinus tract.

The clinical and radiographic criteria to determine success were the absence of all the conditions described previously until the end of the follow-up. As secondary outcomes, we investigated the possible association of the independent variables to the endodontic treatment failure, such as age of the child, gender, restoration material used (composite resin and glass ionomer direct restoration or composite strip crowns), tooth (incisor or molar), pain in the baseline (present or absent), tooth condition (infection caused by caries or dental trauma), type of pulp involvement (irreversible pulpities or tooth necrosis), obturation quality (adequate, sub-obturation or over-obturation), caries experience (dmft), root resorption at the baseline

(absent or present). If any restorative failure was observed during the follow-up period, a repair or replacement of the restoration has been made by the evaluator.

Data analysis

Statistical software STATA 13.0 (Stata Corp. College Station, TX, USA) was used. The experimental unit was the tooth. Descriptive analyses were initially performed to summarize the clinical and demographic characteristics of the sample at baseline. Survival of the endodontic treatment was evaluated by estimating survival rates through Kaplan-Meier curves. Cox Regression analysis with shared fragility were performed to evaluate the association between the independent variables to endodontic treatment failure.

As no sample size calculation was done prior to the beginning of this study, a power analysis was conducted (power>80%) based on Cox proportional hazard model, considering a two-tailed test and an alfa of 5%.

A significance level of 5% was adopted for all analyses.

RESULTS

The treatments were performed between May 2016 and March 2017. All children invited during the survey period agreed to participate. A total of 105 pulpectomies were performed in 48 high-caries-risk infants (dmft = 8.18 ± 3.57). The mean ± standard deviation of the age range of the sample was 2.22 ± 0.72, including 36 (75%) male infants and 12 (25%) female infants. In the sample 36 (75%) of the parents reported having 8 years or more of education. Table I shows the distribution of the pulpectomies according to the baseline demographic clinical characteristics of the sample.

The drop-out rate of the present study was 7.61%. The patients' flow since the enrolment and the losses to follow-up in each evaluation are presented in Figure 1. The mean follow-up time was 15.89 ± 3.04 months, with a minimum and maximum time of 12 and 24 months of follow-up, respectively. Failure occurred in 12 teeth (12.3%), due to pathological root resorption and pathologic bone rarefaction. Resorption of the intracanal filling paste was observed in 2 (1.9%) teeth.

After 24 months follow-up, the survival of the endodontic treatment was 86.06% (SE=0.03; CI=76.6%-91.9%). Kaplan-Meier survival analysis is presented in Figure 2. In the Cox regression analysis, root resorption at baseline was associated with a higher risk of failure (HR=2.81; CI=1.12-7.08; p=0.027). Power analysis for cox-regression was found to be higher than 80%. The survival of the endodontic treatment due to dental trauma was 100%, while teeth with dental caries had a survival of 85.05% (p<0.001*). All other variables analyzed such as gender, age, tooth position, restoration type, tooth condition, obturation quality and caries experience were not associated with pulp treatment failure (p>0.05), as presented in Table II.

Table I - Distribution of pulpectomies performed on deciduous teeth of according to the individual variables and at the tooth level in the baseline

Variable	N (%)
Tooth Position	
Anterior	92 (88.5)
Posterior	12 (11.5)
Jaw	
Superior	101 (97.1)
Inferior	3 (2.9)
Tooth	
Molar	12 (11.5)
Incisive	92 (88.5)
Dental Pain	
No	87 (83.7)
Yes	17 (16.3)
Tooth condition	
Caries	94 (90.4)
Dental trauma	10 (9.6)
Periapical lesion	
No	67 (64.4)
Yes	37 (35.6)
Pulp involvement	
Irreversible Pulpite	54 (51.9)
Pulp necrosis	50 (48.1)
Obturation quality	
Adequade	69 (66.3)
Sub-obturation	22 (21.2)
Over-obturation	13 (12.5)
Material used for restoration	
Composite resin	9 (8.7)
Glass ionomer cement resin-modified	33 (32.0)
Composite resin crown	61 (59.2)

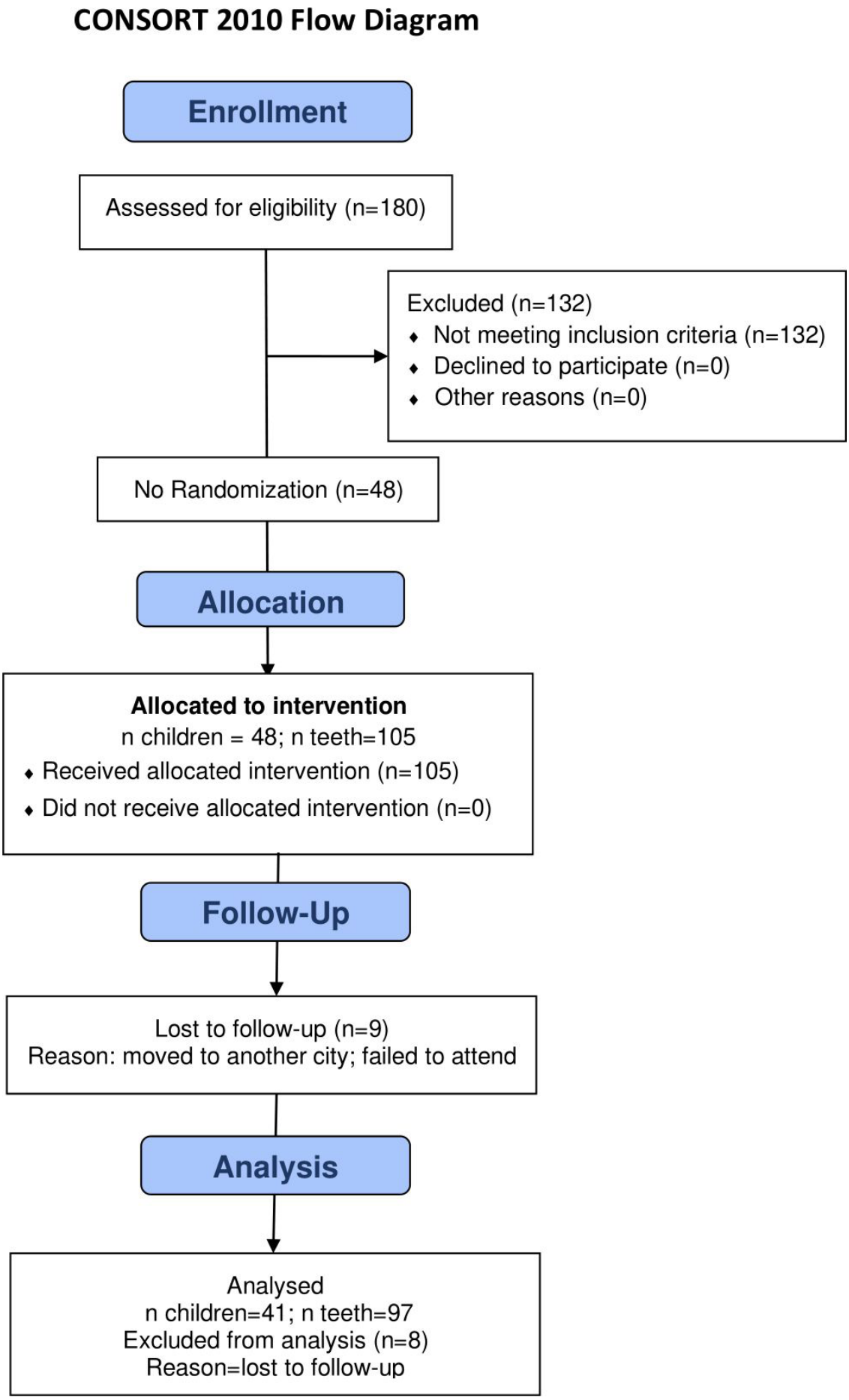

Figure 1 - CONSORT flow diagram.

Table II - Descriptive, univariated and adjusted Cox regression with shared fragility analysis between failures and associated factors

Variable	Success n (%)	Fail n (%)	Total (n)	HR Univariated† 95% CI ‡	*P*-value
Gender					
Male (ref)	68 (89.47)	8 (10.53)	76		
Female	17 (80.95)	4 (19.05)	21	1.80 (0.54-5.99)	0.335
Age (years)					
1 (ref)	8 (80)	2 (20)	10		
2	47 (90.38)	5 (9.62)	52	0.46 (0.11-1.91)	0.285
3	30 (85.71)	5 (14.29)	35	0.74 (0.17-3.21)	0.694
Degree of education (mother)					
<8 years (ref)	6 (85.71)	1 (14.29)	7		
≥ 8 years	72 (90)	8 (10)	80	0.66 (0.07-6.21)	0.724
Tooth Position					
Anterior (ref)	74 (87.06)	11 (12.94)	85		
Posterior	11 (91.67)	1 (8.33)	12	0.66 (0.11-3.96)	0.653
Restoration Material					
Composites/GICm (ref)	32 (88.89)	4 (11.11)	36		
Composite strip crowns	53 (86.89)	8 (13.11)	61	1.10 (0.34-3.56)	0.870
Tooth					
First molar (ref)	7 (87.50)	1 (12.50)	8		
Second molar	4 (66.67)	2 (33.33)	6	2.39 (0.28-20.42)	0.424
Incisive	74 (89.16)	9 (10.84)	83	0.74 (0.15-3.59)	0.718
Pain					
Present(ref)	71 (87.65)	10 (12.35)	81		
Absent	14 (87.50)	2 (12.50)	16	1.08 (0.26-4.41)	0.918
Tooth condition					
Caries (ref)	77 (86.52)	12 (13.48)	89		
Dental trauma	8 (100)	0 (0)	8	5.58 (2.03-1.53)	<0.001*
Pulp Envolvment					
Irreversible Pulpitie (ref)	45 (91.84)	4 (8.16)	49		
Necrosis	40 (83.33)	8 (16.67)	48	2.04 (0.58-7.19)	0.263
Obturation quality					
Adequade (ref)	59 (89.39)	7 (10.61)	66		
Sub-obturation	17 (94.44)	1 (5.56)	18	0.50 (0.06-3.82)	0.508
Over-obturation	9 (69.23)	4 (30.77)	13	3.07 (0.99-9.56)	0.052
Caries experience (dmft)					
Continuous (Mean-SD)	8.54 (3.42)	9.83 (2.32)	8.70 (3.32)	1.12 (0.99-1.25)	0.054
Root Resorption					
Absent (ref)	81 (89.01)	10 (10.99)	91		
Present	4 (66.67)	2 (33.33)	6	2.81 (1.12-7.08)	0.027*
Total	**85 (87.63)**	**12 (12.37)**	**97**		

† HR = Hazard ratio; ‡ CI = Confidence interval; *($p < 0.05$)

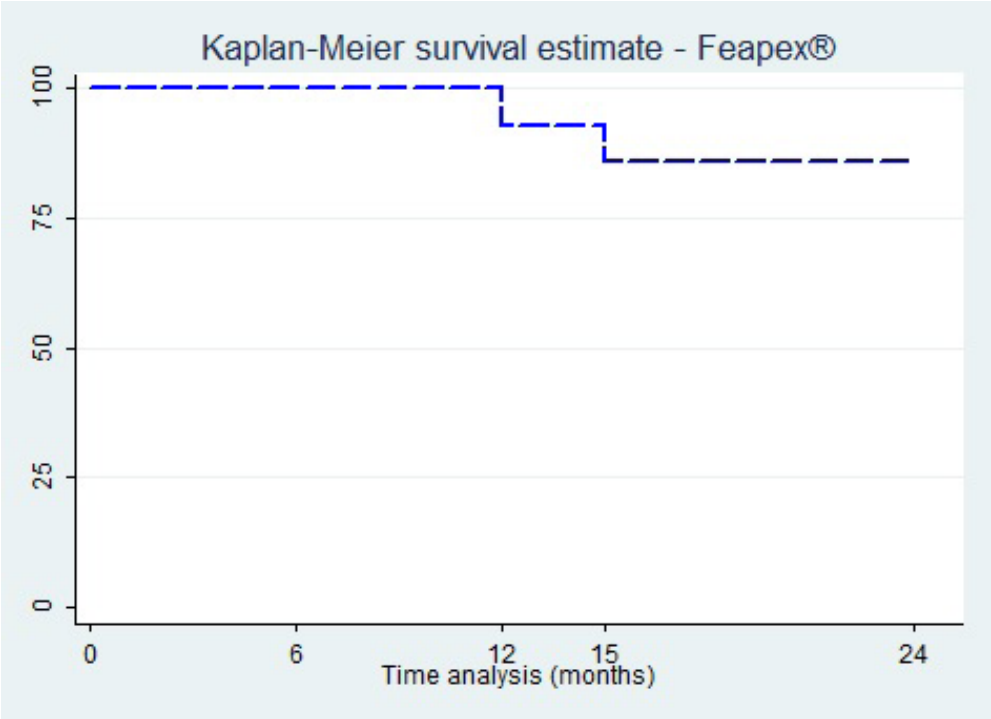

Figure 2 - Kaplan-Meier survival analysis for pulpectomy in deciduous teeth through a new protocol using 2% chlorhexidine digluconate and Feapex®.

DISCUSSION

Primary tooth pulpectomy aims to access, clean, model and obturate the root canals with a biocompatible and resorbable material [33,34]. Although the obturation materials are the main target of studies about endodontic treatment in primary teeth, it is still not possible to confirm that there is an ideal material encompassing all the desired properties [35]. In addition, different countries have different materials available to them with a variety of properties and characteristics, depending on the availability of the local market.

Vitapex is one of the most commonly-used materials worldwide, and has shown satisfactory performance and high success rate in previous clinical trials [23,31,36,37]. However, it is unavailable in the Brazilian market; therefore, other materials have been released in the market. These materials have not undergone previous longitudinal clinical investigation.

This clinical study evaluated the survival rate of pulpectomy in primary teeth through a new protocol using 2% chlorhexidine digluconate and Feapex® paste, materials available in the Brazilian market and approved by the National Health Surveillance Agency (ANVISA). The application of the present results can be difficult in countries where the Feapex® paste is not available, reducing the external validity of the present findings.

The success of endodontics in primary teeth is related to the set of treatment stages, from anesthesia, absolute isolation, obturation until crown restoration. The present study included both anterior and posterior teeth, with pulp necrosis or teeth with irreversible pulpitis. The literature indicates some initial characteristics as factors predisposing to treatment failure, such as root canal external resorption degree greater than 1 mm, presence of fistula, abscess, alteration of the gingival contour and type of restoration performed [25,35,36,38,39]. However, in the present study, none of these factors influenced the longevity of endodontic treatment.

The literature shows that the pulpal status of the included teeth (pulp necrosis or irreversible pulpitis) may influence endodontic success [40]. In the present study there were no differences in relation to this variable. In teeth with pulpal necrosis, there is a greater number of anaerobic microorganisms that are located within the root canals, dentinal tubules, furcal region (in posterior teeth) and apical region (anterior teeth), where the radiographic lesion is. The success of endodontic treatment in these cases depends on

the antimicrobial characteristics of the obturation material, especially in cases of single-session pulpectomy. The success of Feapex® presented in this study could be explained by its similarity of composition to Vitapex, with both pastes based on calcium hydroxide and iodoform.

It is important to note that in most pulp therapy studies, the operators were experts in pediatric dentistry, with previous child management skills and experience, which would generally be considered incomparable with their primary dental care colleagues (dental surgeons without specialization). Longitudinal studies of effectiveness are increasing nowadays, since they can evaluate the performance of treatments closer to reality than when compared with efficacy studies, which are usually controlled and carried out with experienced operators [41]. Thus, the choice of the operator in research could directly influence the success rates of pulp techniques, overestimating the results of the techniques in those with specialization, even though no study evaluated the operator effect on pulpectomy until the moment.

There is currently no scientific consensus concerning the best intracanal irrigant solution for use in primary teeth with pulp necrosis or irreversible pulpitis. A recent systematic review aimed to evaluate the best irrigant to be used in primary teeth pulpectomy[37]. However, it was not possible to reach a conclusion on which substance should be recommended due to the heterogeneity of the studies and the lack of comparison of several irrigators in the studies. Overall, a large proportion of the studies included in the systematic review evaluated the efficacy of 2% chlorhexidine digluconate or 2.5% sodium hypochlorite; both were found to significantly reduce the microbial count[37]. However, in terms of toxicity, a previous study[38] observed that 2% chlorhexidine digluconate had less cytotoxic potential when compared to NaOCl in both concentrations (1% and 2.5%).

On the other hand, 2% chlorhexidine digluconate solution does not have the ability to dissolve and remove the smear layer, an important factor that influences the results of endodontic treatment[41]. In order to remove the smear layer, 17% EDTA was used as a chelating agent in this study [40].

One of the factors influencing pulp treatment survival in the present study was the tooth condition (dental trauma or caries). In the case of dental trauma, dental tissue is rarely compromised, which may influence the longevity of the restoration. It is known that if there is a restorative failure, pulp treatment may be compromised. In cases of caries lesions, pulp compromise occurs mainly in extensive lesions, which can lead to restorative failure [42], and thus to treatment failure as a whole. The present study used materials such as glass ionomer cement and composite resin for restorations of these teeth, and not a stainless steel crown [29]; the restorative material may therefore have been one of the reasons for failure. The association between restorative material/technique in the survival of endodontic treatment in primary teeth needs to be evaluated in further clinical trials.

A limitation of the design of the present study is the absence of a control group. Therefore, randomised clinical trials still need to be performed with the aim to compare the present protocol for pulpectomy in primary teeth with other materials and techniques available in the literature, including sample size calculation and stantardised restorative procedure.

This is the first study to evaluate the survival of a new endodontic protocol: 2% chlorhexidine digluconate and Feapex® paste for root filling of primary teeth with pulpal necrosis or irreversible pulpitis in infants. Although with long-term results of this present trial, further randomized clinical trials needs to be performed in order to increase the level of evidence for the present treatment protocol.

CONCLUSION

The new protocol using 2% chlorhexidine digluconate and Feapex® for primary teeth pulpectomy showed a survival rate after 24months of 86.06%. Therefore, this is a suitable protocol for pulpectomy in primary teeth, showing similar survival rates when compared to other studies that used Vitapex and ZOE pastes.

Acknowledgments

We would like to thank the children and their parents for taking part in this research and Fórmula & Ação for supplying necessary materials. A special thanks goes Elaine Shore for the careful English language review of our paper.

Conflict of Interest

The Author(s) declare(s) that there is no conflict of interest.

Funding

There is no financial support to the article.

Regulatory Statement

This study was conducted in accordance with all the provisions of the local human subjects oversight committee guidelines and policies of the School of Dentistry, University of São Paulo. The approval code for this study is: 1.484.312.

REFERENCES

1. Abanto J, Vidigal EA, Carvalho TS, Sá SN, Bönecker M. Factors for determining dental anxiety in preschool children with severe dental caries. Braz Oral Res. 2017;31(0):e13. http://dx.doi.org/10.1590/1807-3107bor-2017.vol31.0013. PMid:28099579.
2. Ferraz NKL, Nogueira LC, Pinheiro MLP, Marques LS, Ramos-Jorge ML, Ramos-Jorge J. Clinical consequences of untreated dental caries and toothache in preschool children. Pediatr Dent. 2014;36(5):389-92. PMid:25303505.
3. Brasil. Ministério da Saúde. Secretaria de Atenção à Saúde. Secretaria de Vigilância em Saúde. SD Brasil 2010: Pesquisa Nacional de Saúde Bucal: resultados principais. Brasília: MS; 2012.
4. Figueiredo MJ, de Amorim RG, Leal SC, Mulder J, Frencken JE. Prevalence and Severity of clinical consequences of untreated dentine carious lesions in children from a deprived area of Brazil. Caries Res. 2011;45(5):435-42. http://dx.doi.org/10.1159/000330531. PMid:21860241.
5. Abanto J, Carvalho TS, Mendes FM, Wanderley MT, Bönecker M, Raggio DP. Impact of oral diseases and disorders on oral health-related quality of life of preschool children. Community Dent Oral Epidemiol. 2011;39(2):105-14. http://dx.doi.org/10.1111/j.1600-0528.2010.00580.x. PMid:21029148.
6. Abanto J, Paiva SM, Raggio DP, Celiberti P, Aldrigui JM, Bönecker M. The impact of dental caries and trauma in children on family quality of life. Community Dent Oral Epidemiol. 2012;40(4):323-31. PMID: 22292606.
7. Bönecker M, Abanto J, Tello G, Oliveira LB. Impact of dental caries on preschool children's quality of life: an update. Braz Oral Res. 2012;26(spe1, Suppl Suppl 1):103-7. http://dx.doi.org/10.1590/S1806-83242012000700015. PMid:23318751.
8. Nadin G, Goel BR, Yeung A, Glenny A-M. Pulp treatment for extensive decay in primary teeth. Cochrane Database Syst Rev. 2003;1:CD003220. http://dx.doi.org/10.1002/14651858.CD003220.
9. Fayle SA, Welbury RR, Roberts JF, British Society of Paediatric Dentistry. BSPD. British Society of Paediatric Dentistry: a policy document on management of caries in the primary dentition. Int J Paediatr Dent. 2001;11(2):153-7. PMid:11310141.
10. Threlfall AG, Pilkington L, Milsom KM, Blinkhorn AS, Tickle M. General dental practitioners' views on the use of stainless steel crowns to restore primary molars. Br Dent J. 2005;199(7):453-5. http://dx.doi.org/10.1038/sj.bdj.4812746.
11. Fukai K, Ohno H, Blinkhorn AS. A cross-sectional survey investigating the care of the primary dentition by general dental practitioners working in Japan and England. Int Dent J. 2010;60(6):389-94. PMid:21302736.
12. Neelakantan P, Liu P, Dummer PMH, McGrath C. Oral health-related quality of life (OHRQoL) before and after endodontic treatment: a systematic review. Clin Oral Investig. 2020;24(1):25-36. http://dx.doi.org/10.1007/s00784-019-03076-8. PMid:31712982.
13. Kopel HM. Root canal therapy for primary teeth. J Mich State Dent Assoc. 1970;52(2):28-33, passim. PMid:5263926.
14. Bonow MLM, Guedes-Pinto ACBL. Antimicrobial activity of drugs used in pulp therapy of deciduous teeth. J EndodBraz. 1996;1:44-8.
15. Guedes-Pinto AC, Paiva J, Bozzola J. Tratamento endodôntico de dentes decíduos com polpa mortificada. Assoc Paul Cir Dent. 1981;35:240-5.
16. Gonçalves LS, Rodrigues RC, Andrade CV Jr, Soares RG, Vettore MV. The effect of sodium hypochlorite and chlorhexidine as irrigant solutions for root canal disinfection: a systematic review of clinical trials. J Endod J Endod. 2016;42(4):527-32. http://dx.doi.org/10.1016/j.joen.2015.12.021. PMid:26852149.
17. Fuks AB. Pulp therapy for the primary and young permanent dentitions. Dent Clin North Am. 2000;44(3):571-96, vii. [vii.] PMid:10925773.
18. Kubota K, Golden BE, Penugonda B. Root canal filling materials for primary teeth: a review of the literature. ASDC J Dent Child. 1992;59(3):225-7. PMid:1629445.
19. Nurko C, Garcia-Godoy F. Evaluation of a calcium hydroxide/iodoform paste (Vitapex) in root canal therapy for primary teeth. J Clin Pediatr Dent. 1999;23(4):289-94. PMid:10551129.
20. Barja-Fidalgo F, Moutinho-Ribeiro M, Oliveira MAA, Oliveira BH. A systematic review of root canal filling materials for deciduous teeth: is there an alternative for zinc oxide-eugenol? ISRN Dent. 2011;2011: 367318. http://dx.doi.org/10.5402/2011/367318. PMid:21991471.
21. Najjar RS, Alamoudi NM, El-Housseiny AA, Al Tuwirqi AA, Sabbagh HJ. A comparison of calcium hydroxide/iodoform paste and zinc oxide eugenol as root filling materials for pulpectomy in primary teeth: A systematic review and meta-analysis. Clin Exp Dent Res. 2019;5(3):294-310. http://dx.doi.org/10.1002/cre2.173. PMid:31249711.
22. Tchaou WS, Turng BF, Minah GE, Coll JA. Inhibition of pure cultures of oral bacteria by root canal filling materials. Pediatr Dent. 1996;18(7):444-9. PMid:8970206.
23. Ozalp N, Saroğlu I, Sönmez H. Evaluation of various root canal filling materials in primary molar pulpectomies: an in vivo study. Am J Dent. 2005;18(6):347-50. PMid:16433405.
24. Mortazavi M, Mesbahi M. Comparison of zinc oxide and eugenol, and Vitapex for root canal treatment of necrotic primary teeth. Int J Paediatr Dent. 2004;14(6):417-24. http://dx.doi.org/10.1111/j.1365-263X.2004.00544.x. PMid:15525310.
25. Mendoza AM, Reina JE, Garcia-Godoy F. Evolution and prognosis of necrotic primary teeth after pulpectomy. Am J Dent. 2010;23(5):265-8. PMid:21207793.
26. Fava LR, Saunders WP. Calcium hydroxide pastes: classification and clinical indications. Int Endod J. 1999;32(4):257-82. http://dx.doi.org/10.1046/j.1365-2591.1999.00232.x. PMid:10551118.
27. Mani SA, Chawla HS, Tewari A, Goyal A. Evaluation of calcium hydroxide and zinc oxide eugenol as root canal filling materials in primary teeth. ASDC J Dent Child. 67(2):142-7. PMID: 10826052.
28. Smaïl-Faugeron V, Fron Chabouis H, Durieux P, Attal J-P, Muller-Bolla M, Courson F. Development of a core set of outcomes for randomized controlled trials with multiple outcomes – example

of pulp treatments of primary teeth for extensive decay in children. PLoS One. 2013;8(1):e51908.

29. Smaïl-Faugeron V, Glenny A-M, Courson F, Durieux P, Muller-Bolla M, Fron Chabouis H. Pulp treatment for extensive decay in primary teeth. Cochrane Database Syst Rev. 2018;5(5):CD003220. http://dx.doi.org/10.1002/14651858.CD003220.pub3. PMid:29852056.

30. Aragão AC, Pintor AVB, Marceliano-Alves M, Primo LG, Silva ASS, Lopes RT, et al. Root canal obturation materials and filling techniques for primary teeth: in vitro evaluation in polymer-based prototyped incisors. Int J Paediatr Dent. 2020;30(3):381-9. http://dx.doi.org/10.1111/ipd.12604. PMid:31811738.

31. Trairatvorakul C, Chunlasikaiwan S. Success of pulpectomy with zinc oxide-eugenol vs calcium hydroxide/iodoform paste in primary molars: a clinical study. Pediatr Dent. 2008;30(4):303-8. PMid:18767509.

32. Moskovitz M, Sammara E, Holan G. Success rate of root canal treatment in primary molars. J Dent. 2005;33(1):41-7. http://dx.doi.org/10.1016/j.jdent.2004.07.009. PMid:15652167.

33. Yanko N, Khmil O, Kaskova L, Vashchenko I. Advanced endodontic developments in pulpectomy of primary teeth. Wiad Lek. 2016;69(2 Pt 2):223-7. PMid:27487538.

34. Bergenholtz G, Axelsson S, Davidson T, Frisk F, Hakeberg M, Kvist T, et al. Treatment of pulps in teeth affected by deep caries – A systematic review of the literature. Singapore Dent J. 2013;34(1):1-12. http://dx.doi.org/10.1016/j.sdj.2013.11.001. PMid:24360260.

35. Smaïl-Faugeron V, Courson F, Durieux P, Muller-Bolla M, Glenny A-M, Fron Chabouis H. Pulp treatment for extensive decay in primary teeth. Cochrane Database Syst Rev. 2014;(8):CD003220. http://dx.doi.org/10.1002/14651858.CD003220.pub2. PMid:25099759.

36. Chen X, Liu X, Zhong J. Clinical and radiographic evaluation of pulpectomy in primary teeth: a 18-months clinical randomized controlled trial. Head Face Med. 2017;13(1):12. http://dx.doi.org/10.1186/s13005-017-0145-1. PMid:29073902.

37. Nedley MP. The pulpectomy in primary teeth. J Mich Dent Assoc. 2002;84(8):38-42. PMid:12192915.

38. el-Kalla IH, García-Godoy F. Fracture strength of adhesively restored pulpotomized primary molars. ASDC J Dent Child. 66(4):238-42. PMID: 10529865.

39. Guelmann M, McIlwain MF, Primosch RE. Radiographic assessment of primary molar pulpotomies restored with resin-based materials. Pediatr Dent. 2005;27(1):24-7. PMid:15839391.

40. Smaïl-Faugeron V, Glenny AM, Courson F, Durieux P, Muller-Bolla M, Fron Chabouis H. Pulp treatment for extensive decay in primary teeth. Cochrane Database Syst Rev. 2014;(8):CD003220.

41. Thorpe KE, Zwarenstein M, Oxman AD, Treweek S, Furberg CD, Altman DG, et al. A pragmatic–explanatory continuum indicator summary (PRECIS): a tool to help trial designers. J Clin Epidemiol. 2009;62(5):464-75. http://dx.doi.org/10.1016/j.jclinepi.2008.12.011. PMid:19348971.

42. Tedesco TK, Gimenez T, Floriano I, Montagner AF, Camargo LB, Calvo AFB, et al. Scientific evidence for the management of dentin caries lesions in pediatric dentistry: a systematic review and network meta-analysis. PLoS One. 2018;13(11):e0206296. http://dx.doi.org/10.1371/journal.pone.0206296. PMid:30462676.

Jenny Abanto
(Corresponding address)
Paulista Association of Dental Surgeons, Department of Paediatric Dentistry, School of Dentistry, São Paulo, SP, Brazil.
Email: jennyabantousp@gmail.com

Date submitted: 2021 May 17
Accepted submission: 2021 July 27