



# Is enucleation followed by peripheral ostectomy and Carnoy's solution application an adequate treatment for Odontogenic keratocyst? A case series with up to five years of follow up

A enucleação seguida da osteotomia periférica e a aplicação de solução de Carnoy é um tratamento adequado para o ceratocisto odontogênico? Uma série de casos com acompanhamento de até cinco anos

Varun ARYA<sup>1</sup> , Minerva SINGH<sup>1</sup> , Rajeev PANDEY<sup>2</sup> , Sanjeev KUMAR<sup>1</sup> , Jingade Krishnajirao Dayashankara RAO<sup>3</sup> , Santosh MISHRA<sup>4</sup> 

1 - SGT University, Faculty of Dental Sciences, Department of Oral and Maxillofacial Surgery, Gurugram, Haryana, India.

2 - CHC Shivpur, Gorakhpur, Uttar Pradesh, India.

3 - Qassim University, College of Dentistry, Buraydah, Al Qassim, Saudi Arabia.

4 - Govt. S.S. Medical College, Rewa, Madhya Pradesh, India.

## ABSTRACT

**Objective:** To evaluate the treatment outcome of enucleation and peripheral ostectomy with the use of Carnoy's solution for management of Odontogenic keratocyst. **Material and Methods:** 17 patients with OKC who reported from 2011 to 2015 were included. All the cases were treated by enucleation and peripheral ostectomy of 0.5mm followed by Carnoy's solution cauterization for 4 minutes. All patients were followed up for 4-5 years. **Results:** All the cases were followed-up by using serial panoramic radiography and clinical evaluation at regular intervals. No recurrence was reported in any of the cases. **Conclusion:** Treatment of Odontogenic keratocyst by enucleation and 0.5mm of peripheral ostectomy, followed by Carnoy's solution cauterization for 4 minutes is an effective treatment with zero recurrence rates for five years of follow-up.

## KEYWORDS

Odontogenic keratocyst; Enucleation; Carnoy's solution; Recurrence.

## RESUMO

**Objetivo:** Avaliar o resultado do tratamento de enucleação e osteotomia periférica com o uso de solução de Carnoy para o manejo do ceratocisto odontogênico (OKC). **Material e Métodos:** 17 pacientes com OKC com acompanhamento de 2011 a 2015 foram incluídos. Todos os casos foram tratados através da enucleação e osteotomia periférica de 0,5 mm, seguido da cauterização com solução de Carnoy por 4 minutos. Todos os pacientes foram acompanhados por 4-5 anos. **Resultados:** Todos os casos foram acompanhados por meio de séries de radiografias panorâmicas e avaliação clínica em intervalos regulares. Nenhuma recorrência foi reportada em nenhum dos casos. **Conclusão:** O tratamento de ceratocisto odontogênico por meio da enucleação e osteotomia periférica de 0,5mm, seguido da cauterização com solução de Carnoy por 4 minutos é um tratamento efetivo com zero taxa de recorrência em um acompanhamento de 5 anos.

## PALAVRAS-CHAVE

Ceratocisto odontogênico; Enucleação; Solução de Carnoy; Recorrência.

## INTRODUCTION

Odontogenic keratocyst (OKC) is a cystic lesion of odontogenic origin, which was firstly described by Mikulicz, in 1876, Philipsen, in 1956 was the first to name and recognize OKC as an entity [1,2]. It accounts for approximately 10% of jaw cysts and is considered to be an aggressive lesion because of a relatively high recurrence rate [3]. The term Primordial cyst, synonymous with OKC, was used in the 1992 World Health Organization (WHO) classification and put under the category of developmental odontogenic cysts [4]. In 2005, WHO identified OKC as a neoplasm and renamed it as Keratocystic Odontogenic Tumor (KCOT) contributed to its aggressive nature, high recurrence rate, its association with Nevoid Basal Cell Carcinoma Syndrome (NBCCS) or Gorlin Goltz syndrome, and mutations seen in the Protein Patched Homolog (PTCH) tumor suppressor gene. In 2017, WHO reclassified this lesion under developmental odontogenic cysts as OKC [5,6]. The reported age range is 8 to 82 years old, with a peak in the third decade of life with a slight male predilection. When associated with the NBCCS, the mean age of incidence is around 25 years old [7]. OKCs originate in tooth-bearing regions, the predilection for mandible is more than that of maxilla, the most common location being the posterior part namely the angle or the ramus whereas, in maxilla, the anterior region and the third molar area are the most common sites of occurrence [3]. Due to unpredictable nature of OKC various treatment modalities have been proposed, few of them advocate for conservative procedures and others for aggressive surgical treatment. The recurrence rate for OKC ranges from 2.5 to 62%, depending on the treatment modality used [8]. The majority of recurrence occurs during first few years of treatment. Enucleation alone is associated with a high recurrence rate, it decreases with the addition of an adjuvant procedure. The treatment modality that has shown the lowest recurrence rate is resection of the lesion with or without continuity defects but at the same time causes highest patient morbidity, therefore the requirement of a low recurrence rate needs to be weighed against patient morbidity [9].

We present a study of 17 patients with OKC who were treated by enucleation with peripheral

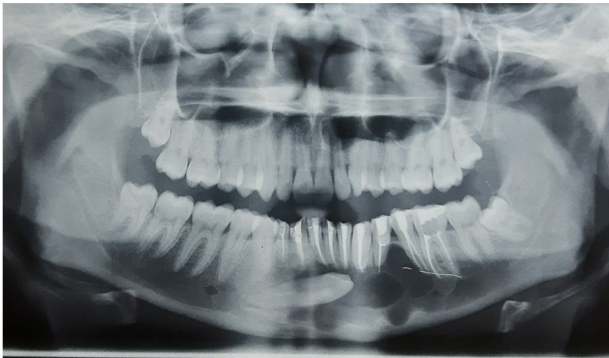ostectomy followed by chemical cauterization with Carnoy's solution. The purpose of the present study was to analyze the recurrence rate of OKC in the same patients for a period of four to five years.

## MATERIAL AND METHODS

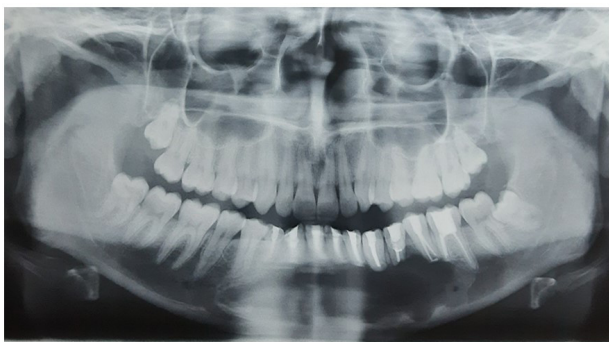This study was conducted from 2011 to 2015 on patients with OKC who satisfied the inclusion and exclusion criteria of the study. Confirmed cases of OKC as diagnosed by histopathology both pre and post-operatively with follow-up of four to five years were included in the present study, whereas syndromic patients with OKCs, patients not willing to participate in the study and patients with pathological fractures were excluded. 17 patients were included out of which 9 were male and 8 females, age ranging from 17 to 60 years. All the patients underwent surgical enucleation under general anaesthesia after obtaining medical fitness. Enucleation of the entire lesion was done while taking care of adjacent neural and vascular structures, it was followed by peripheral ostectomy which was done using a pear-shaped vulcanite bur to remove at least 0.5mm of the cavity bone, while irrigating with saline. Carnoy's solution was freshly made by mixing 1ml of glacial acetic acid, 1g of Ferric Chloride, 6ml of absolute alcohol and 3ml Chloroform. Adjacent mucosa, gingiva and neural structures were preserved by applying a layer of paraffin wax, then a gauze was used to apply Carnoy's solution for 4 minutes. After 4 minutes, the cavity was thoroughly rinsed with saline to wash off the solution and debris, primary closure was done using absorbable suture material. All patients were followed up for four to five years, post-operatively. Figure 1-5 show pre and post-operative radiographs of two cases which were followed up for five and four years, respectively.

## RESULTS

The study included 17 patients with OKC who met the inclusion criteria. 9 patients (52.9%) were male and 8 (47.0%) were female, the ratio being 1.12:1, age ranged from 17 to 60 years. 12 lesions were located in mandible out of which 8 involved posterior region and

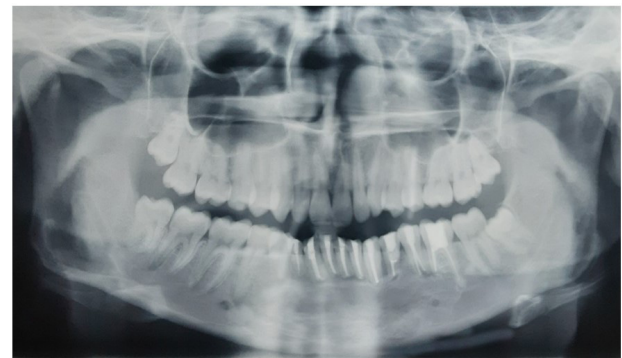

**Figure 1** - Pre-operative pantomogram showing multilocular OKC involving anterior mandible and left side body, impacted canine is also seen.



**Figure 2** - Three months post-operative pantomogram showing persistent mandibular radiolucency, no radiographical signs of recurrence.

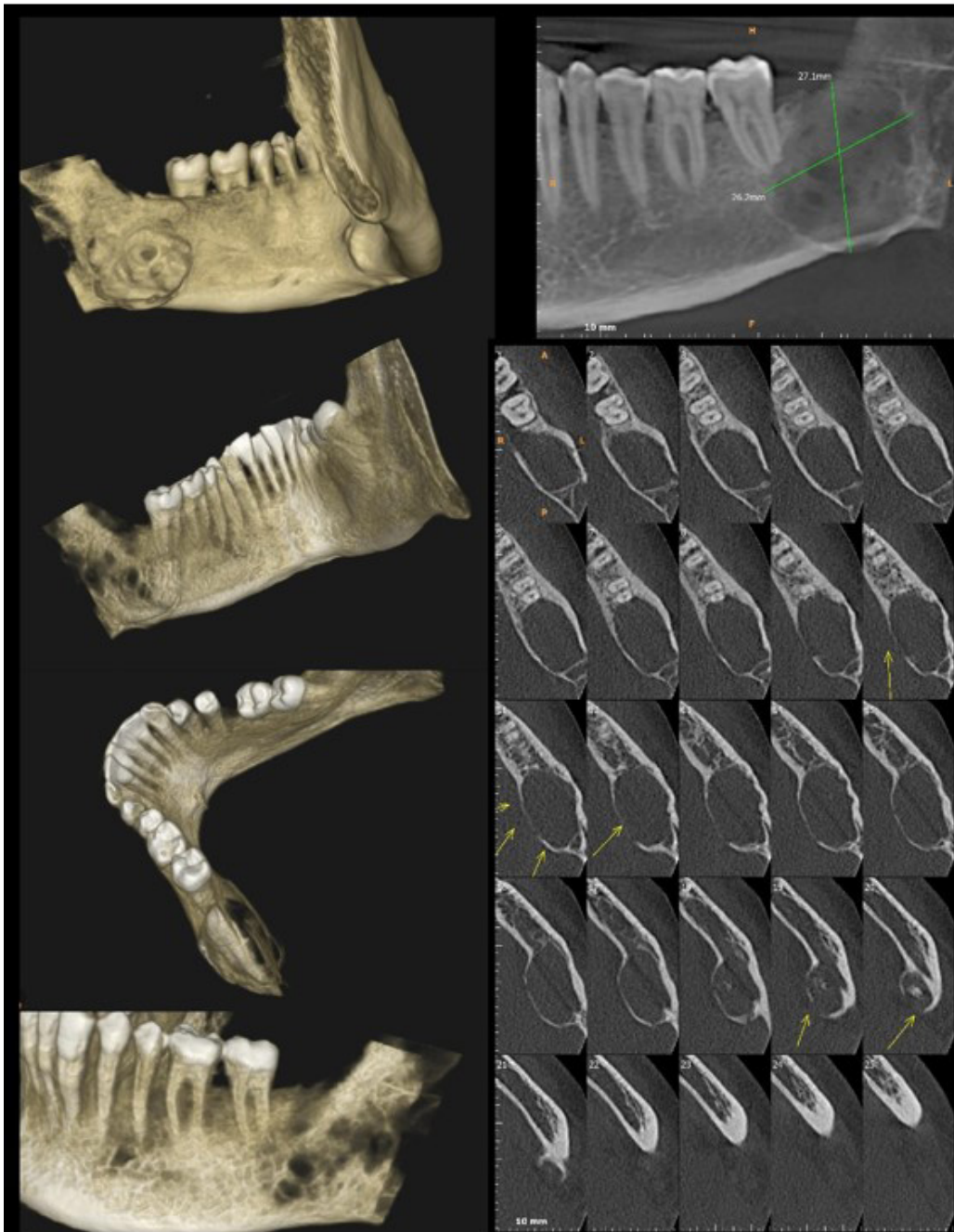
4 involved anterior region, whereas 5 lesions were located in maxilla, out of which 3 involved anterior region and 2 involved posterior region. All patients were followed up for four to five years, post-operatively. None of the cases showed any recurrence throughout the period of follow-up, which might be indicative of the presented protocol being an effective option. Paraesthesia for a maximum of 6 weeks was noted in four patients and wound dehiscence in three, no other complications were noted (Table I).



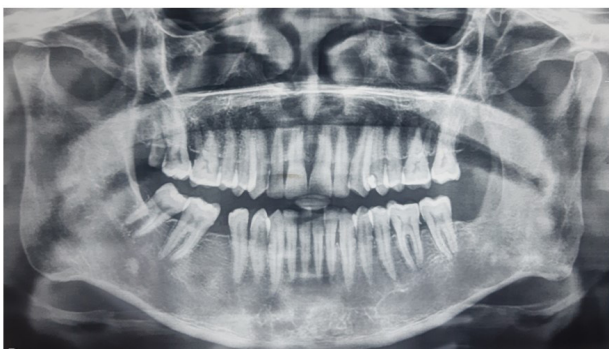**Figure 3** - Five years post-operative pantomogram showing complete ossification of bone, no radiographical signs of recurrence can be seen.

**Table I** - Patient's pre and post-operative data

| S.No. | Age/<br>Sex | Chief Complaint                   | Region involved    | Unilocular/<br>Multilocular | Complication if any                                  | Follow-up |
|-------|-------------|-----------------------------------|--------------------|-----------------------------|--|-----------|
| 1.    | 22/M        | Swelling                          | Posterior mandible | Multilocular                | Paraesthesia for 6 weeks                             | 5 years   |
| 2.    | 35/F        | Swelling                          | Anterior mandible  | Multilocular                | None   | 5 years   |
| 3.    | 58/M        | Swelling                          | Posterior mandible | Multilocular                | None   | 4 years   |
| 4.    | 48/M        | Pain and swelling                 | Anterior maxilla   | Multilocular                | None   | 4 years   |
| 5.    | 26/F        | Pain and swelling                 | Posterior mandible | Multilocular                | Wound dehiscence                                     | 5 years   |
| 6.    | 31/M        | Swelling                          | Posterior mandible | Unilocular                  | Wound dehiscence<br>with paraesthesia for 4<br>weeks | 5 years   |
| 7.    | 49/M        | Mobility of teeth and<br>swelling | Anterior mandible  | Multilocular                | None   | 5 years   |
| 8.    | 55/F        | Swelling                          | Anterior maxilla   | Unilocular                  | None   | 5 years   |
| 9.    | 26/M        | Pain and swelling                 | Posterior mandible | Multilocular                | None   | 4 years   |
| 10.   | 45/F        | Swelling                          | Posterior mandible | Multilocular                | Paraesthesia for 4 weeks                             | 5 years   |
| 11.   | 60/M        | Mobility of teeth and<br>swelling | Anterior mandible  | Unilocular                  | Wound dehiscence                                     | 5 years   |
| 12.   | 33/F        | Swelling                          | Posterior maxilla  | Multilocular                | None   | 5 years   |
| 13.   | 17/M        | Swelling                          | Anterior mandible  | Multilocular                | None   | 5 years   |
| 14.   | 42/F        | Pain and Swelling                 | Posterior mandible | Multilocular                | None   | 4 years   |
| 15.   | 28/F        | Swelling                          | Posterior mandible | Multilocular                | Paraesthesia for 6 weeks                             | 4 years   |
| 16.   | 37/F        | Pain and swelling                 | Posterior maxilla  | Multilocular                | None   | 5 years   |
| 17.   | 28/M        | Pain and swelling                 | Anterior maxilla   | Multilocular                | None   | 5 years   |



**Figure 4** - Pre-operative Cone beam computed tomography showing unilocular OKC involving left angle of mandible, buccal and lingual cortical expansion is appreciable.



**Figure 5** - Four years post-operative pantomogram showing complete ossification of bone, no radiographical signs of recurrence can be seen.

## DISCUSSION

The term Odontogenic Keratocyst was first used by Philipsen, in 1956 [2]. OKC is notorious for its aggressive behavior and high recurrence rate, Pindborg and Hansen (1963) were the first to point this out [10].

In 1992, WHO did not add OKC as a separate entity under developmental odontogenic cysts in their classification but a synonymous term, Primordial Cyst was used instead [4]. In 2005 WHO classification, 3<sup>rd</sup> edition, OKC was renamed

as Keratocystic Odontogenic Tumor (KCOT) and was removed from the list of cysts and was rather reclassified as a neoplasm because of its aggressive nature, high recurrence rate, its association with a syndrome i.e. nevoid basal cell carcinoma syndrome or Gorlin Goltz syndrome, and mutations seen in the protein patched homolog (PTCH) tumor suppressor gene [5]. However, authors reported that KCOT could be treated with decompression and marsupialization, which is not a feature of a neoplastic lesion also PTCH gene suppression can be associated with non-neoplastic lesions such as dentigerous cyst thus, in 2017, 4<sup>th</sup> edition WHO classification again named KOCT as OKC and included it under the category of developmental odontogenic cysts [6].

OKC develops from the dental lamina remnants, before odontogenesis is complete, it may originate from the basal cells of overlying epithelium as well [1]. OKC corresponds to approximately 10% of all odontogenic cysts, occurring twice as commonly in posterior mandible i.e. the third molar region, angle and ramus, than maxilla, where it is mainly found in anterior or third molar region, where an extension into the maxillary sinus is commonly seen. The age range is wide, 8-82 years, peak incidence being in 3<sup>rd</sup> decade of life but when associated with NBCCS, it has been reported that the incidence tends to drop to approximately 25 years of age. Male predilection is slightly more than female, in our study male predilection was nearly equal to that in female [3].

For NBCCS, presence of multiple OKCs is considered as a major criteria. NBCCS, is an autosomal dominant syndrome that is characterised by nevoid basal cell carcinoma, multiple OKCs, palmar or plantar pits, calcifications of falx cerebri and other skeletal abnormalities, such as bifid, fused or splayed ribs. NBCCS is associated with mutations of the PTCH gene which has also been reported in isolated cases of OKC as well [1,11].

OKC is usually asymptomatic, patients with OKCs rarely complain of pain, swelling, discharge or paraesthesia of the lower lip due invasion of inferior alveolar nerve canal, thus this lesion is mostly an incidental radiographic finding and is often misdiagnosed as periapical cyst, lateral periodontal cyst, follicular cyst or Ameloblastoma. OKCs have been reported to acquire a periapical position in 33% of cases,

21% cases show pericoronal position, 19% cases show lateral position with respect to tooth root whereas 27% cases show no relation to any tooth structure [12].

In the mandible, the OKCs tend to grow along the length of the bone, causing minimal antero-posterior expansion. However, in some cases, erosion of buccal and lingual cortices can be appreciated, whereas in the maxilla, expansion of the alveolar bone with thinning and perforation of the cortical bone has been reported in the literature [3,13]. This may be contributed to the greater thickness of mandible cortices than that of maxilla. Radiographically, OKCs appear as osteolytic lesions that may be unilocular or multilocular with incomplete septa or multilocular. The multilocular presentation is seen in large lesions giving a soap-bubble appearance. Tooth displacement or root resorption though uncommon but may be seen, with root resorption incidence being 1.3 to 11%. The perforation of the cortical bone is reported to be seen in nearly 39 to 51% cases. Nearly 30% of OKCs have been found to be associated with impacted teeth, especially third molars [14,15].

The mainstay for diagnosis of OKC is histopathological examination. It characteristically shows a thin, friable wall that consists of 5-10 cell layers of parakeratinised squamous epithelium with a palisaded basal layer of columnar or cuboidal cells, with vertically oriented nuclei. No epithelial rete ridges are present, however budding of basal cells into the connective tissue leads to the formation of small satellite cysts, cords, or islands of odontogenic epithelium. The cystic lumen consists either of a clear transudate like liquid or some cheese like caseous material [16].

Talking about the biochemical composition of OKC, Toller, in 1970 reported that aspirate from OKC has soluble protein levels less than 3.5 g/100 ml whereas, the values for non-keratinising cysts are in the range 5.0-11.0 g/100ml. He stated that a protein level of less than 4.0 g/100ml is diagnostic of OKC. However, inflammation leads to increased protein content, giving false negative diagnosis [17,18].

The choice of treatment modality is driven by the size and location of the cystic lesion, patient's age, radiographical picture of the lesion and presence of cortical perforation or involvement of the surrounding soft tissue. The

treatment modalities include marsupialization, decompression, enucleation, peripheral ostectomy, chemical curettage, cryotherapy or marginal or segmental resection. The incidence of recurrence ranges from 2.5% to 62% as reported in the literature [8]. In 1976, Brannon suggested three reasons for OKC recurrence: Inadequate removal of the cyst lining, formation of a new OKC lesion from satellite cysts, and development of a new OKC in an adjacent area [19].

Marsupialization is a conservative treatment modality. After an opening is made, a window is maintained into the lesion through which its contents get abolished. Marsupialization followed by enucleation can be done for large cystic lesions so that the size gets reduced after marsupialization and enucleation is successful. Disadvantages are that it often requires two surgical procedures and the treatment time is quite long [20].

The advantages of enucleation are complete removal of the cyst and a thorough histopathological examination. However, compromised vitality of adjacent teeth, damage to neurovascular bundle, and injury to adjacent anatomic structures, such as the maxillary sinus, floor of the nasal cavity, and the mandibular canal, may occur [20]. However, to avoid chances of recurrence, 1-2mm of peripheral ostectomy, beyond the lesion margins can be done [21], as we did in our patients and supplemented it with chemical cauterization using Carnoy's solution. Treatment of OKC with Carnoy's solution is done to prevent recurrence by eliminating the remnants of the cyst, but it may also damage adjacent bone and neurovascular bundle as it is neurotoxic and chemically fixes the nerves when in contact for more than 2 minutes, therefore the nerve should be protected using paraffin wax [22]. Stoelinga suggests removal of the overlying mucosa and use of Carnoy's solution to avoid recurrence, he recommends a long term follow-up, regardless of the treatment modality [23,24].

According to Johnson et al., enucleation is associated with 30% chances of recurrence, whereas marsupialization when done alone has a recurrence rate of 18%, when done along with Carnoy's solution application, the recurrence rate reduces to almost 8%. Resection has the lowest recurrent rate but causes highest patient morbidity [9].

There are no clear guidelines reported in literature regarding the follow-up period for OKCs, however studies recommend aggressive monitoring in the first five years of primary surgery as recurrence has been mostly reported within this period [16,25-27]. Pogrel suggested that patients should be followed-up every six months for the first two years, every year for the first five years, and every two years for the first ten years, with panoramic radiographs, irrespective of the treatment modality used [21] whereas Borghesi et al. suggested yearly radiographic follow-up during the first five years and every two or three years subsequently [3]. We recommend a regular follow-up of patients for at least first five years, post-operatively and same was followed in the present study as well.

In the present study, the follow up protocol included the use of two dimensional x-ray imaging which has its own limitations in providing an exact size and spatial orientation of the lesion with an added risk of radiation. Use of other diagnostic modalities such as Magnetic Resonance Imaging (MRI), ultrasound and colour Doppler imaging, has been suggested in literature [28,29]. Along with providing three dimensional status of the lesion and being radiation free, these modalities provide information about the healing of overlying soft tissues as well.

## CONCLUSION

Treatment of OKC using enucleation supplemented with 0.5mm of peripheral ostectomy, followed by chemical cauterization for 4 minutes using Carnoy's solution is an effective treatment with zero recurrence rates for four to five years of follow-up. We suggest that low recurrence rate should be weighed against estimated patient morbidity, thus a less aggressive but equally effective treatment modality should be chosen.

## Authors' Contributions

Varun Arya (MDS) - Formulation and data collection. Minerva Singh (MDS Resident) - Data collection and writing. Rajeev Pandey (MDS) - Data collection and Writing. Sanjeev Kumar (MDS) - Final approval. Jingade Krishnajirao Dayashankara Rao (MDS) - Final approval. Santosh Mishra (MDS) - Data collection.

## Conflict of Interest

No conflicts of interest declared concerning the publication of this article.

## Funding

The authors declare that no financial support was received.

## Regulatory Statement

This study is a retrospective analysis. The approval code for this study is: FODS/EC/FRP/OS/2021/62A.

## REFERENCES

- Nayak MT, Singh A, Singhvi A, Sharma R. Odontogenic keratocyst: what is in the name? *J Nat Sci Biol Med.* 2013;4(2):282-5. <http://dx.doi.org/10.4103/0976-9668.116968>. PMID:24082717.
- Philipsen HP. Om keratocyster (kolesteatom) i kaeberne. *Tandlaegebladet.* 1956;60:963-81.
- Borghesi A, Nardi C, Giannitto C, Tironi A, Maroldi R, Di Bartolomeo F, et al. Odontogenic keratocyst: imaging features of a benign lesion with an aggressive behaviour. *Insights Imaging.* 2018;9(5):883-97. <http://dx.doi.org/10.1007/s13244-018-0644-z>. PMID:30066143.
- Kramer IR, Pindborg JJ, Shear M. The World Health Organization histological typing of odontogenic tumours. Introducing the second edition. *Eur J Cancer B Oral Oncol.* 1993;29B(3):169-71. [http://dx.doi.org/10.1016/0964-1955\(93\)90018-A](http://dx.doi.org/10.1016/0964-1955(93)90018-A). PMID:8298419.
- Barnes L, Eveson JW, Reichart P, et al. WHO classification of tumours, pathology and genetics of Head and Neck tumours. Lyon, France: IARC Press; 2005.
- Suluk-Tekkeşin M, Wright JM. The World Health Organization classification of odontogenic lesions: a summary of the changes of the 2017 (4th) edition. *Turk Patoloji Derg.* 2018;34(1):1-18. PMID:28984343.
- Woolgar JA, Rippin JW, Browne RM. The odontogenic keratocyst and its occurrence in the nevoid basal cell carcinoma syndrome. *Oral Surg Oral Med Oral Pathol.* 1987;64(6):727-30. [http://dx.doi.org/10.1016/0030-4220\(87\)90176-9](http://dx.doi.org/10.1016/0030-4220(87)90176-9). PMID:3480489.
- Li TJ. The odontogenic keratocyst: a cyst, or a cystic neoplasm? *J Dent Res.* 2011;90(2):133-42. <http://dx.doi.org/10.1177/0022034510379016>. PMID:21270459.
- Johnson NR, Batstone MD, Savage NW. Management and recurrence of keratocystic odontogenic tumor: a systematic review. *Oral Surg Oral Med Oral Pathol Oral Radiol.* 2013;116(4):e271-6. <http://dx.doi.org/10.1016/j.oooo.2011.12.028>. PMID:22771402.
- Pindborg JJ, Hansen J. Studies on odontogenic cyst epithelium. 2. Clinical and roentgenologic aspects of odontogenic keratocysts. *Acta Pathol Microbiol Scand.* 1963;58(3):283-94. <http://dx.doi.org/10.1111/j.1699-0463.1963.tb01572.x>. PMID:14044666.
- Gorlin RJ, Goltz RW. Multiple nevoid basal-cell epithelioma, jaw cysts and bifid rib: a syndrome. *N Engl J Med.* 1960;262(18):908-12. <http://dx.doi.org/10.1056/NEJM196005052621803>. PMID:13851319.
- Ali M, Baughman RA. Maxillary odontogenic keratocyst: a common and serious clinical misdiagnosis. *J Am Dent Assoc.* 2003;134(7):877-83. <http://dx.doi.org/10.14219/jada.archive.2003.0286>. PMID:12892445.
- Mosier KM. Lesions of the jaw. *Semin Ultrasound CT MR.* 2015;36(5):444-50. <http://dx.doi.org/10.1053/j.sult.2015.08.003>. PMID:26589698.
- MacDonald D. Lesions of the jaws presenting as radiolucencies on cone-beam CT. *Clin Radiol.* 2016;71(10):972-85. <http://dx.doi.org/10.1016/j.crad.2016.05.018>. PMID:27371961.
- Harmon M, Arrigan M, Toner M, O'Keeffe SA. A radiological approach to benign and malignant lesions of the mandible. *Clin Radiol.* 2015;70(4):335-50. <http://dx.doi.org/10.1016/j.crad.2014.10.011>. PMID:25559378.
- Kshirsagar RA, Bhende RC, Raut PH, Mahajan V, Tapadiya VJ, Singh V. Odontogenic keratocyst: developing a protocol for surgical intervention. *Ann Maxillofac Surg.* 2019;9(1):152-7. [http://dx.doi.org/10.4103/ams.ams\\_137\\_18](http://dx.doi.org/10.4103/ams.ams_137_18). PMID:31293945.
- Toller PA. Protein substances in odontogenic cyst fluids. *Br Dent J.* 1970;128(7):317-22. <http://dx.doi.org/10.1038/sj.bdj.4802465>. PMID:5270321.
- Patidar M, Shetty P, Patidar N, Mittal S, Singh H, Chethna. Biochemical and cytological comparison of keratocystic odontogenic tumours to nonkeratinising odontogenic cysts fluid. *J Clin Diagn Res.* 2015;9(7):ZC34-8. <http://dx.doi.org/10.7860/JCDR/2015/12501.6195>. PMID:26393202.
- Brannon RB. The odontogenic keratocyst: a clinicopathologic study of 312 cases. Part I. Clinical features. *Oral Surg Oral Med Oral Pathol.* 1976;42(1):54-72. [http://dx.doi.org/10.1016/0030-4220\(76\)90031-1](http://dx.doi.org/10.1016/0030-4220(76)90031-1). PMID:1065842.
- Zhao YF, Wei JX, Wang SP. Treatment of odontogenic keratocysts: a follow-up of 255 Chinese patients. *Oral Surg Oral Med Oral Pathol Oral Radiol Endod.* 2002;94(2):151-6. <http://dx.doi.org/10.1067/moe.2001.125694>. PMID:12221380.
- Pogrel MA. The keratocystic odontogenic tumor. *Oral Maxillofac Surg Clin North Am.* 2013;25(1):21-30, v. <http://dx.doi.org/10.1016/j.coms.2012.11.003>. PMID:23218985.
- Frerich B, Cornelius CP, Wiethölter H. Critical time of exposure of the rabbit inferior alveolar nerve to Carnoy's solution. *J Oral Maxillofac Surg.* 1994;52(6):599-606. [http://dx.doi.org/10.1016/0278-2391\(94\)90098-1](http://dx.doi.org/10.1016/0278-2391(94)90098-1). PMID:8189298.
- Stoelinga PJ. The treatment of odontogenic keratocysts by excision of the overlying, attached mucosa, enucleation, and treatment of the bony defect with carnoy solution. *J Oral Maxillofac Surg.* 2005;63(11):1662-6. <http://dx.doi.org/10.1016/j.joms.2005.08.007>. PMID:16243184.
- Stoelinga PJ. Long-term follow-up on keratocysts treated according to a defined protocol. *Int J Oral Maxillofac Surg.* 2001;30(1):14-25. <http://dx.doi.org/10.1054/ijom.2000.0027>. PMID:11289615.
- Pitak-Arnop P, Chaîne A, Oprean N, Dhanuthai K, Bertrand JC, Bertolus C. Management of odontogenic keratocysts of the jaws: a ten-year experience with 120 consecutive lesions. *J Craniomaxillofac Surg.* 2010;38(5):358-64. <http://dx.doi.org/10.1016/j.jcms.2009.10.006>. PMID:19897381.
- Hadziabdic N, Dzinovic E, Udovicic-Gagula D, Sulejmanagic N, Osmanovic A, Halilovic S, et al. Nonsyndromic examples of odontogenic keratocysts: presentation of interesting cases with a literature review. *Case Rep Dent.* 2019;2019:9498202. <http://dx.doi.org/10.1155/2019/9498202>. PMID:31511794.
- Alstad V, Abtahi J. Surgical removal of keratocystic odontogenic tumours via a Le Fort I osteotomy approach: a retrospective study of the recurrence rate. *Int J Oral Maxillofac Surg.* 2017;46(4):434-9. <http://dx.doi.org/10.1016/j.ijom.2017.01.006>. PMID:28189375.

28. Reda R, Zanza A, Mazzoni A, Cicconetti A, Testarelli L, Di Nardo D. An update of the possible applications of magnetic resonance imaging (MRI) in dentistry: a literature review. *J Imaging*. 2021;7(5):75. <http://dx.doi.org/10.3390/jimaging7050075>. PMID:34460671.
29. Tikku AP, Kumar S, Loomba K, Chandra A, Verma P, Aggarwal R. Use of ultrasound, color Doppler imaging and radiography to monitor periapical healing after endodontic surgery. *J Oral Sci*. 2010;52(3):411-6. <http://dx.doi.org/10.2334/josnusd.52.411>. PMID:20881334.

**Varun Arya****(Corresponding address)**

SGT University, Faculty of Dental Sciences, Department of Oral and Maxillofacial Surgery, Gurugram, Haryana, India.  
Email: drvarunrya@gmail.com

Date submitted: 2021 May 31  
Accept submission: 2021 July 04