



Guided endodontic access of severe calcified tooth without incisal edge – case report

Acesso endodôntico guiado de dente calcificado severamente sem borda incisal – relato de caso

Esteban Isai FLORES OROZCO¹ , Amjad ABU HASNA¹ , Guilherme Schmitt de ANDRADE² ,
Vinícius de Carvalho MACHADO³ ; Luiz Roberto Coutinho MANHÃES JUNIOR^{4,5} ,
Guilherme de Siqueira Ferreira Anzaloni SAAVEDRA²

1 - Universidade Estadual Paulista, Institute of Science and Technology, Endodontics Division, Department of Restorative Dentistry. São José dos Campos, SP, Brazil.

2 - Universidade Estadual Paulista, Institute of Science and Technology, Department of Prosthodontics and Dental Materials. São José dos Campos, SP, Brazil.

3 - Faculdade São Leopoldo Mandic de Belo Horizonte (SLM-Campinas), Faculty of Dentistry, Department of Radiology. Belo Horizonte, MG, Brazil.

4 - Universidade Estadual Paulista, Institute of Science and Technology, Department of Diagnosis and Surgery. São José dos Campos, SP, Brazil.

5 - Faculdade São Leopoldo Mandic, Faculty of Dentistry, Department of Radiology. Campinas, SP, Brazil.

ABSTRACT

Pulp tissue may suffer calcification because of trauma, operative procedures or carious lesions. This paper aimed to report and discuss the guided endodontic access as an alternative treatment. A 52 years old female patient had severe root canal calcification of tooth #11 associated with a radiolucent periapical lesion. Firstly, the crown and metal post and core were removed. A digital impression and cone-beam computed tomography “CBCT” scans were performed and imported to implant planning software (SimPlant Version 11; Materialise Dental, Leuven, Belgium). The guided endodontic access template was designed to allow the drill to reach a distance of 2 mm short of the apical foramen, once printed, it was tested in the mouth to evaluate its insertion and stability in the dental arch. The calcified root canal was penetrated using the access drill rotating by a low-speed hand-piece (10,000 rpm) under saline solution irrigation through advancing movements. Then, the apical foramen was negotiated with C-Pilot files #10 and #15. The working length was measured using the iPex-II apex locator. The instrumentation was carried out with Reciproc R50 and 2.5% sodium hypochlorite. One week later, a full-ceramic crown preparation was performed, and polyvinyl siloxane impression was carried out. A total of three follow-up sessions were performed after one week, one and twelve months. Bone neoformation was observed in the site of the periapical lesion and the patient had no signs or symptoms of any discomfort. Therefore, guided endodontics is indicated for severe calcified root canals.

KEYWORDS

Guided endodontics; Calcified root canals; Access cavity.

RESUMO

O tecido pulpar pode sofrer calcificação por trauma, procedimentos cirúrgicos ou como resposta a lesões cariosas. Este trabalho teve como objetivo relatar e discutir o acesso endodôntico guiado como opção de tratamento. Paciente do sexo feminino, 52 anos, com calcificação severa do canal radicular do dente 11 associada a lesão periapical radiolúcida. Na primeira intervenção clínica, a coroa e o pino de metal foram removidos. Uma impressão digital e imagens de CBCT foram realizadas e importadas para o software de planejamento de implante (SimPlant Versão 11; Materialize Dental, Leuven, Bélgica) tentando projetar um modelo de acesso endodôntico guiado para permitir que a broca alcance uma distância de 2 mm antes do forame apical, uma vez impresso, foi testado na boca para avaliar sua inserção e estabilidade na arcada dentária. O canal radicular calcificado foi penetrado

com broca de acesso girando por peça de mão de baixa velocidade (10.000 rpm) sob irrigação com solução salina por meio de movimentos de avanço. Em seguida, o forame apical foi negociado com as limas C-Pilot nº 10 e nº 15. O comprimento de trabalho foi determinado usando o localizador de ápice iPex-II. A instrumentação foi realizada com Reciproc R50 e hipoclorito de sódio 2,5%. Uma semana depois, foi realizado o preparo da coroa total em cerâmica e a moldagem com polivinilsiloxano. Um total de três sessões de acompanhamento foram realizadas após uma semana, um e doze meses. A neoformação óssea foi observada no local da lesão periapical e a paciente não apresentava sinais ou sintomas de qualquer desconforto. Portanto, o acesso endodôntico guiado é indicado para canais radiculares calcificados severamente.

PALAVRAS-CHAVE

Endodontia guiada; Canais radiculares calcificados; Acesso endodôntico.

INTRODUCTION

Periapical periodontitis is an inflammatory disease that affects the periapical region of infected teeth [1]. It is characterized by pyogenic material accumulation in a soft tissue cavity [2]. Clinically, it may be manifested as a periapical cyst or granuloma, however, the histological exam permits a differential diagnosis [3].

Pulp tissue may suffer calcification (obliteration) because of trauma, operative procedures or carious lesions [4,5]. It is characterized principally by apparent loss of the pulp space and a yellow discoloration of the clinical crown [6] and this makes the root canal treatment challengeable as the calcification complicates the root canal disinfection [7].

In the literature, some treatment options were stated like ultrasonic tips [8] and methylene-blue dye to locate the root canal orifice under magnification [9]. Conversely, as the minimally invasive endodontics is occupying a greater space in contemporary endodontics, new techniques like guided endodontics become widespread [10,11] to minimize roots perforation risk [12].

The term “guided endodontics” was firstly used by Krastl et al. [13] to relate a virtually planned and guided minimally invasive access cavity with the proposal of more conservative treatment [10]. Guided endodontics tried to simulate guided implant surgery [10] that uses cone beam computed tomography “CBCT” scans to create a surgical template by identifying bone-tooth position prior to surgery and thus to place implants more accurately [14].

Endodontic retreatment always presents a challenge for the clinician, considering the insufficient amount of remaining tooth structure associated with the presence of root canal calcification. This article aimed to report and

discuss the proper case in which the guided access may be an alternative treatment.

CASE REPORT

Patient information

A 52 years old female patient was referred for clinical evaluation at the Institute of Science and Technology of São Paulo State University (ICT-UNESP), the patient complained of discomfort in tooth #11 (ADA classification) and even the tooth presented signs of trauma the patient declared no trauma history. Patient clinical history did not present relevant findings.

Diagnostic assessment

Clinical exams revealed the presence of poorly adapted full crown on tooth #11 (Figure 1A), tooth discoloration and inflamed gingiva. The depth of its gingival pocket varied between 1 and 2 mm with various exploring locations and grade I mobility. Teeth #12 and #21 presented positive response by pulp vitality test using refrigerant gas (Endo Ice, Maquira Dental products industry LTDA–Brazil) and relative isolation whereas tooth #11 presented a negative response.

Digital palpation and perpendicular percussion of tooth #11 presented a slightly discomfort indicating a presence of periapical lesion which was confirmed by periapical radiography (Figure 1B). A severe calcified root canal system of tooth #11 associated was noticed radiographically. The diagnosis was symptomatic periapical periodontitis.

Treatment planning and execution

This work was authorized by the Research Ethics Committee Involving Human Beings

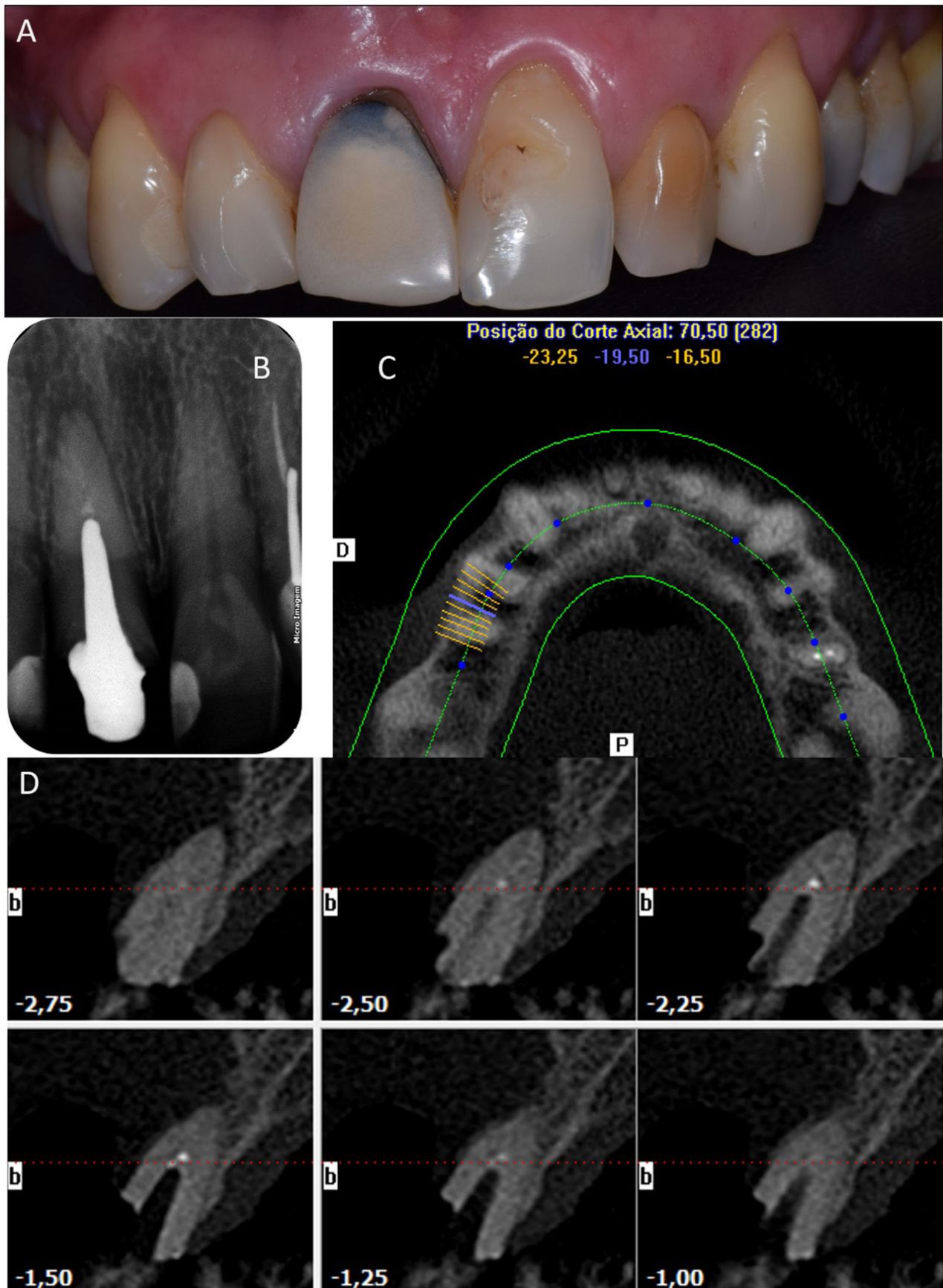


Figure 1 - The clinical and radiographical examination of the calcified tooth. (A) Clinical intraoral image of the anterior teeth; (B) Initial periapical radiography of the tooth #11; (C) Cone-beam computed tomographic (CBCT) image of the sagittal section showing the relation of the lesion with the apex of the upper right central incisor; (D) axial reconstruction of the periapical lesion.

(n 4.151.622) of Institute of Science and Technology (ICT-UNESP). As well, the patient signed an informed consent form. .

At the first session, the ceramic crown was removed using a transmetal bur FG (Dentsply, Konstanz, Germany). The metal post and core removal was performed by ultrasonic vibration (ALT– Equipamentos Médicos e Odontológicos, Ribeirão Preto, SP, Brazil) using the ultrasonic insert E12 (Helse Dental, Ribeirão Preto, SP, Brasil).

Then, CBCT scan (Figure 1C, D) was performed with a soft tissue retraction using a plastic lip retractor and adjusted as the following settings: exposure time 26.9 seconds, 120 kV and 37 mA, 0.12 mm voxel, gray scale, 14 bits to obtain high quality images. Then, intraoral impression was performed (CS 3600, Carestream, Nova York, USA) (Figure 2B). The digital impression and CBCT scans were imported to implant planning software (SimPlant Version 11;

Materialise Dental, Leuven, Belgium). The guided endodontic access template was designed to allow A 1.3 diameter drill (Neodent SA, Curitiba, Brazil) to reach a distance of 2 mm short of the apical foramen (Figure 2A, C, D).The guided endodontic template printed, and tested in the mouth to evaluate its insertion and stability in the dental arch.

The calcified root canal penetration was carried-out using the access drill rotating by low-speed hand-piece at a speed of 10,000 rpm under saline solution irrigation through advancing movements (Figure 3). Then, rubber dam was installed and the distance of 2 mm till reaching the apical foramen was negotiated with C-Pilot files #10 and #15 (VDW, Munich, Germany). The working length was determined using the iPex-II apex locator (NSK, Tokyo, Japan). The instrumentation was carried out with Reciproc R50 (VDW, Munich, Germany) and 2.5% sodium hypochlorite (totaling 15 mL) for root canal lubrication and disinfection. Then, the root

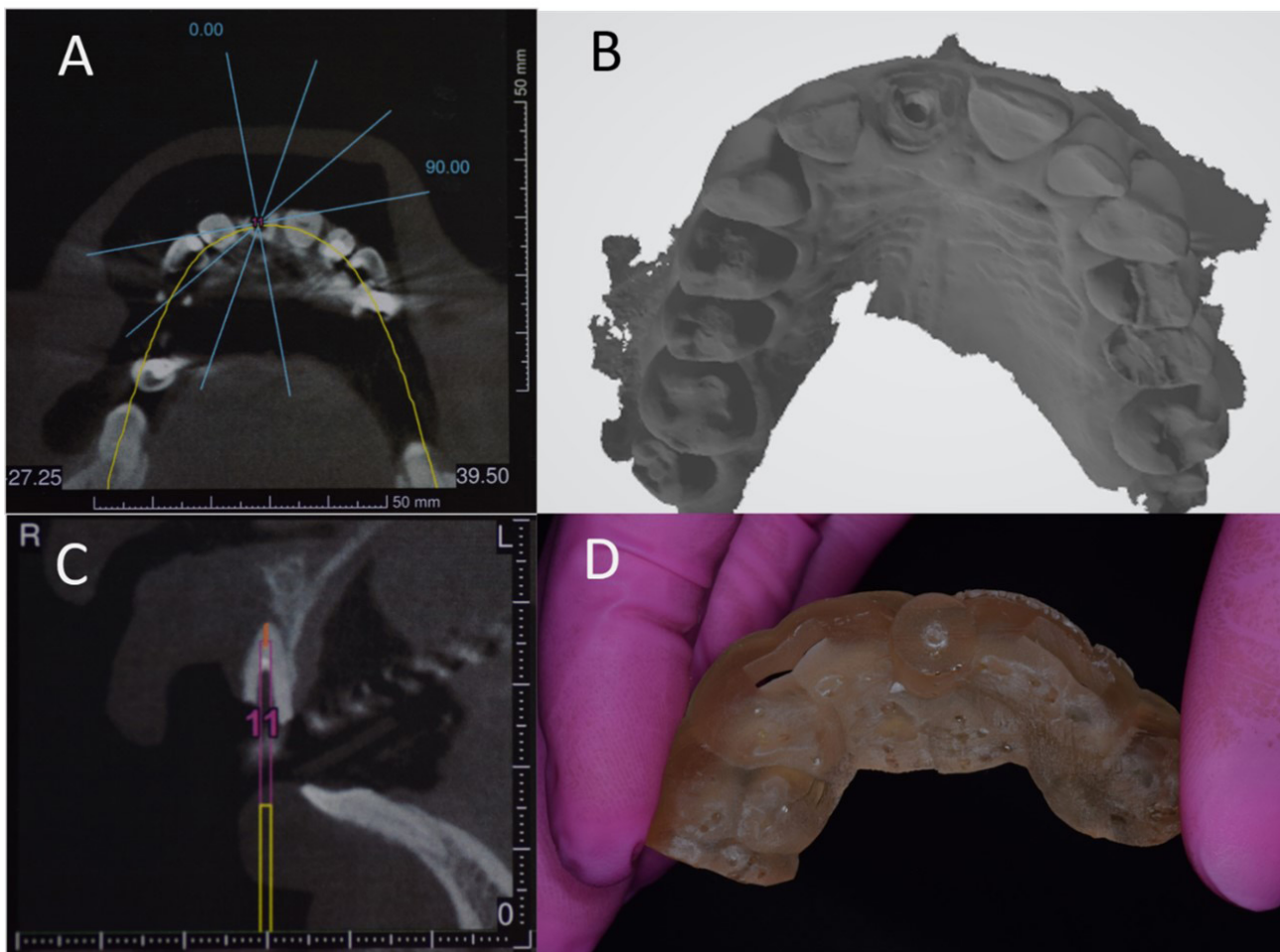


Figure 2 - CBCT images and intraoral impression to design the guided endodontic template. (A) and (C) Virtual planning of the guided endodontic template in CBCT images at axial section; (B) intraoral impression; (D) the template after impression.

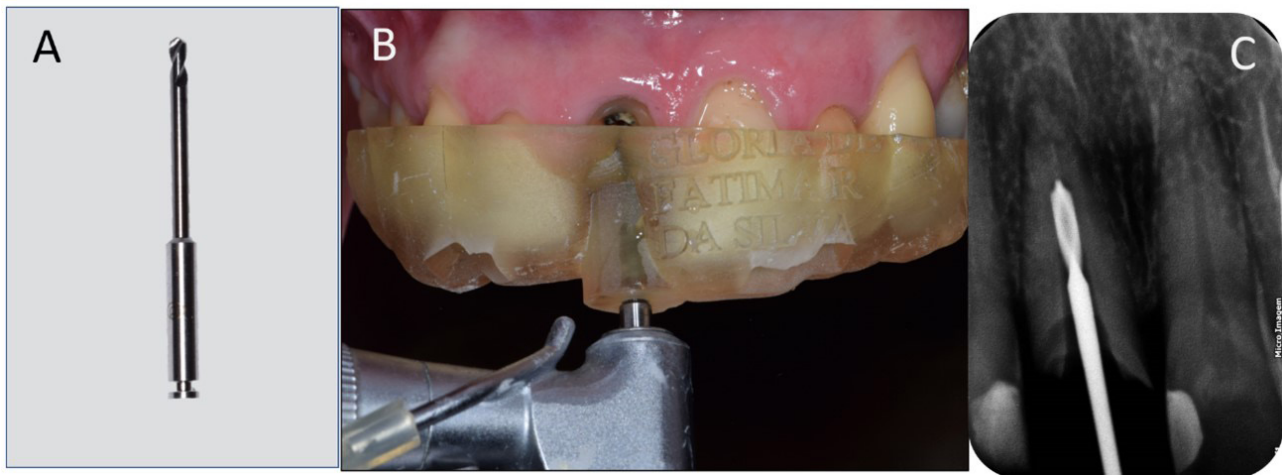


Figure 3 - Clinical execution of the access cavity. (A) Using Neodent drill to access cavity; (B) testing the guide insertion and adaptation in the mouth and execution with a low rotation handpiece; (C) Periapical radiography to check the length.

canal was filled with ethylenediaminetetraacetic acid (EDTA) 17% (Inodon, Porto Alegre, RS, Brasil) and activated with Easy Clean (Easy Dental Equipment, Belo Horizonte, Brazil) for 3 cycles of 20s totaling 60 s. Then irrigated again with 2.5% sodium hypochlorite with 3 cycles of activation by Easy Clean totaling 60 s. Finally, the root canal was washed by 15 mL by sterile saline solution, dried with paper points and obturated in the same session by guta-percha points and AH Plus sealer (Dentsply DeTrey GmbH, Konstanz, Germany) (Figure 4B). The tooth was restored with a provisional crown.

Follow-up and outcomes

One week later, a full ceramic crown preparation was performed, and polyvinyl siloxane impression was carried out (Elite HD, Zhermack, Badia Polesine, Italy). A monolithic heat-pressed lithium disilicate glass ceramic crown was fabricated. After adaptation checking, adjustments and final polishing was performed, the crown was cemented with a dual-cure self-etch resin cement (Multilink N, Ivoclar Vivadent, Schaan, Liechtenstein) (Figure 4A). In this session the patient had no pain or any inflammation signs.

More two follow-up sessions were performed after one and twelve months. A bone neoformation was observed in the site of the periapical lesion and the patient had no signs or symptoms of any discomfort (Figure 4C). In these sessions, clinical intraoral examination was performed and revealed a well-adapted crown and no signs of gingival inflammation or tooth discoloration.

DISCUSSION

Radiographically, calcified tooth seems like a radiopaque mass without any root canal space because of the low sensitivity of conventional radiography, however, histologically, in most calcified teeth, a pulp space with pulp tissue is present [15]. Therefore, retaining pulp chamber by making the access cavity closer to cingulum than to incisal edge [11] may results in root canal treatment failure, as this should totally remove the necrosed tissue and disinfect the whole root canal system [6] through an access cavity close to or through the incisal edge [16].

Pulp calcification itself is not considered as an endodontic disease [17], then the clinical intervention is indicated only when the calcified tooth complicates the treatment execution, prognosis or outcome as in teeth associated with periapical lesions [18] in which a greater disinfection is indicated using intracanal medication, photodynamic therapy and passive ultrasonic irrigation [19-21]

In the case report of Krastl et al. [13] and the study of Zehnder et al. [10], it was clearly demonstrated that the access cavity should pass through the incisal edge and be parallel to the long axis of the tooth. This promotes a more conservative access, beyond an appropriate root canal disinfection [22]. Mechanical shaping may retain untouched areas where cleaning, disinfection and necrosed tissue dissolution should be carried-out chemically by endodontic irrigants [23]. Even more, it is recommended to obtain a postoperative CBCT scan to verify

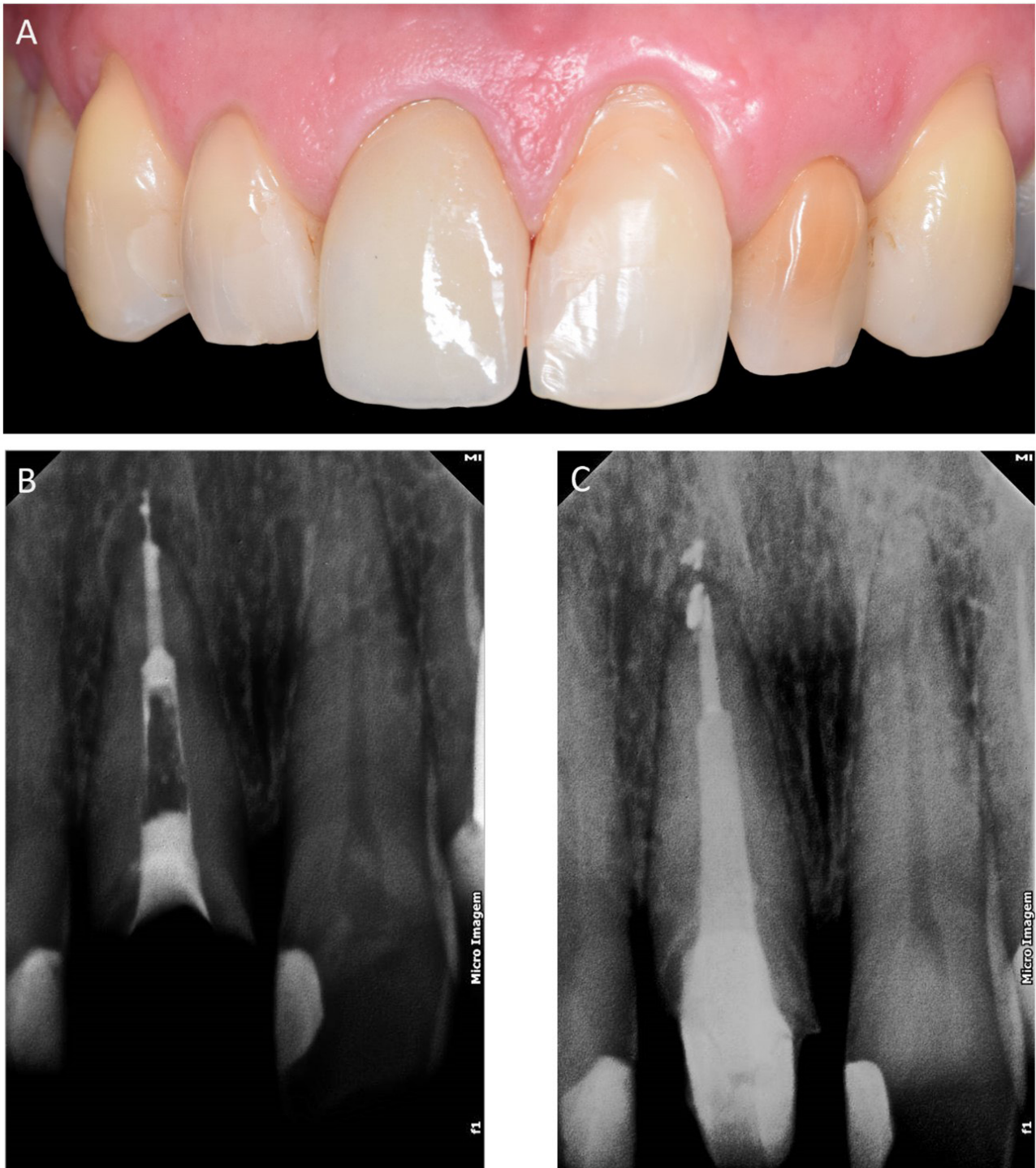


Figure 4 - Crown cementation and follow-up sessions. (A) intraoral image immediately after the crown cementation; (B) periapical radiography immediately after the obturation; (C) periapical radiography at one-year follow-up session.

the accuracy of guided endodontic access and thus to assure a homogenic tridimensional cone preparation [24].

In the present case report, there was no incisal edge due to the little amount of remaining crown tissues, this makes the use of guided endodontics more appropriate as the access will

not retain necrosed tissue and permits more disinfection of the root canal system [6]. Similar clinical situation was reported recently by the case report of Ishak [12] where little remaining structures were observed as a result of bruxism that subsequently caused a severe calcified root canals. However, in another case report, the access was closer to the gingulum [11] and thus

necrosed tissues may be retained during the instrumentation [22].

In this case report, the guided endodontic access was used rather than the ultrasonic minimally invasive access, as the guided endodontic access was recommended in the literature as a valuable tool for the negotiation of partial or complete root canal calcification. Even more, the guided endodontic access can be easily executed by less expert professionals, requires less chair time, and finally it permits a more predictable and expeditious location of calcified root canals when compared to conventional access [25].

Sodium hypochlorite was used in this case because it has a wide antimicrobial action over variety of microorganisms, their endotoxins including LPS and LTA [21] and over the matrix metalloproteinases [26]. It was activated by EasyClean to improve its penetration to untouched areas and inside the dentinal tubules and removes the remaining filling material [27].

The proper treatment planning demands an accurate diagnosis [28], for this, the CBCT scans were used in this case report because of its high resolution and effectivity in determining the relationship between the root apex and the adjacent anatomical structures [29] beside its relevance for the planning of the template of guided endodontic access.

Finally, the guided endodontics, as an innovative technique, is effective in a severe calcified root canal negotiation as related in the literature [12,13,25] and confirmed in this case report disinfecting the root canal. Still, more studies should evaluate its effectiveness in totally removing the necrosed pulp as this is affected by the access direction and location.

CONCLUSION

Guided endodontics is indicated to penetrate severe calcified root canals.

Acknowledgements

None declared.

Authors' Contributions

EIFO: conceptualization, software, data curation, visualization and writing - original

draft. AAH: conceptualization, software, data curation, visualization and writing - original draft. GSA: methodology, resources, investigation, data curation and writing - review. VCM: methodology, resources, investigation, data curation and writing - review. LRCMJ: methodology, writing - review & editing, supervision, and project administration. GSFAS: methodology, writing - review & editing, supervision, and project administration.

Conflict of Interest

The authors deny any conflict of interest.

Funding

None.

Regulatory Statement

This study was conducted in accordance with all the provisions of the local human subjects oversight committee guidelines and policies of the ethics research committee of São Paulo State University - Institute of Science and Technology (ICT-UNESP).

The approval code for this study is 4.151.622.

REFERENCES

1. Kakehashi S, Stanley HR, Fitzgerald RJ. The effects of surgical exposures of dental pulps in germ-free and conventional laboratory rats. *Oral Surg Oral Med Oral Pathol.* 1965;20(3):340-9. [http://dx.doi.org/10.1016/0030-4220\(65\)90166-0](http://dx.doi.org/10.1016/0030-4220(65)90166-0). PMID:14342926.
2. Kinaston R, Willis A, Miskiewicz JJ, Tromp M, Oxenham MF. The dentition. In: Buikstra JE, editor. *Ortner's identification of pathological conditions in human skeletal remains.* London: Academic Press; 2019. p. 749-97. <http://dx.doi.org/10.1016/B978-0-12-809738-0.00021-1>.
3. Mortensen H, Winther JE, Birn H. Periapical granulomas and cysts. *Eur J Oral Sci.* 1970;78(1-4):241-50. <http://dx.doi.org/10.1111/j.1600-0722.1970.tb02070.x>.
4. Beresford JS. Post-traumatic calcification of a root canal. *Br Dent J.* 1951;91(9):241. PMID:14886455.
5. Patterson SS. Pulp calcification due to operative procedures-pulpotomy. *Int Dent J.* 1967;17(2):490-505. PMID:5233878.
6. McCabe PS, Dummer PMH. Pulp canal obliteration: an endodontic diagnosis and treatment challenge. *Int Endod J.* 2012;45(2):177-97. <http://dx.doi.org/10.1111/j.1365-2591.2011.01963.x>. PMID:21999441.
7. Dodds RN, Holcomb JB, McVicker DW. Endodontic management of teeth with calcific metamorphosis. *Compend Contin Educ Dent.* 1985;6(7):520.
8. Suehara M, Sano Y, Sako R, Aida N, Fujii R, Muramatsu T, et al. Microscopic endodontics in infected root canal with calcified structure: a case report. *Bull Tokyo Dent Coll.* 2015;56(3):169-

75. <http://dx.doi.org/10.2209/tdcpublication.56.169>. PMID:26370577.
9. Johnson BR. Endodontic access. *Gen Dent*. 2009;57(6):570-7. PMID:19906609.
10. Zehnder MS, Connert T, Weiger R, Krastl G, Kühl S. Guided endodontics: accuracy of a novel method for guided access cavity preparation and root canal location. *Int Endod J*. 2016;49(10):966-72. <http://dx.doi.org/10.1111/iej.12544>. PMID:26353942.
11. Lara-Mendes STO, Barbosa CFM, Machado VC, Santa-Rosa CC. A new approach for minimally invasive access to severely calcified anterior teeth using the guided endodontics technique. *J Endod*. 2018;44(10):1578-82. <http://dx.doi.org/10.1016/j.joen.2018.07.006>. PMID:30154005.
12. Ishak G, Habib M, Tohme H, Patel S, Bordone A, Perez C, et al. Guided endodontic treatment of calcified lower incisors: a case report. *Dent J*. 2020;8(3):74. <http://dx.doi.org/10.3390/dj8030074>. PMID:32650552.
13. Krastl G, Zehnder MS, Connert T, Weiger R, Kühl S. Guided Endodontics: a novel treatment approach for teeth with pulp canal calcification and apical pathology. *Dent Traumatol*. 2016;32(3):240-6. <http://dx.doi.org/10.1111/edt.12235>. PMID:26449290.
14. Balshi SF, Wolfinger GJ, Balshi TJ. Surgical planning and prosthesis construction using computed tomography, CAD/CAM technology, and the Internet for immediate loading of dental implants. *J Esthet Restor Dent*. 2006;18(6):312-23, discussion 324. <http://dx.doi.org/10.1111/j.1708-8240.2006.00029.x>. PMID:17083435.
15. Schindler WG, Gullickson DC. Rationale for the management of calcific metamorphosis secondary to traumatic injuries. *J Endod*. 1988;14(8):408-12. [http://dx.doi.org/10.1016/S0099-2399\(88\)80126-2](http://dx.doi.org/10.1016/S0099-2399(88)80126-2). PMID:2908117.
16. Amir FA, Gutmann JL, Witherspoon DE. Calcific metamorphosis: a challenge in endodontic diagnosis and treatment. *Quintessence Int*. 2001;32(6):447-55. PMID:11491624.
17. Morse DR, Seltzer S, Sinai I, Biron G. Endodontic classification. *J Am Dent Assoc*. 1977;94(4):685-9. <http://dx.doi.org/10.14219/jada.archive.1977.0329>. PMID:265327.
18. Holcomb JB, Gregory WB Jr. Calcific metamorphosis of the pulp: its incidence and treatment. *Oral Surg Oral Med Oral Pathol*. 1967;24(6):825-30. [http://dx.doi.org/10.1016/0030-4220\(67\)90521-X](http://dx.doi.org/10.1016/0030-4220(67)90521-X). PMID:5234871.
19. Hasna AA, et al. In vitro evaluation of the antimicrobial effect of N-acetylcysteine and photodynamic therapy on root canals infected with enterococcus faecalis. *Iran Endod J*. 2020;15:236-45.
20. Abu Hasna A, Ferrari CH, Talge Carvalho CA. Endodontic treatment of a large periapical cyst with the aid of antimicrobial photodynamic therapy: case report. *Braz Dent Sci*. 2019;22(4):561-8. <http://dx.doi.org/10.14295/bds.2019.v22i4.1745>.
21. Abu Hasna A, Pereira Da Silva L, Pelegrini FC, Ferreira CLR, Oliveira LD, Carvalho CAT. Effect of sodium hypochlorite solution and gel with/without passive ultrasonic irrigation on *Enterococcus faecalis*, *Escherichia coli* and their endotoxins. *F1000 Res*. 2020;9:642. <http://dx.doi.org/10.12688/f1000research.24721.1>. PMID:33149896.
22. Castellucci A. Endodontics. Florence: Il Tridente; 2004. Access cavity and endodontic anatomy; p. 244-5.
23. Peña López A, Conde AJ, Estevez R, Valencia de Pablo O, Rossi-Fedele G, Cisneros R. Sodium hypochlorite and a preparation containing glycocholic acid and surfactants have a synergistic action on organic tissue dissolution in vitro. *J Endod*. 2018;44(5):813-5. <http://dx.doi.org/10.1016/j.joen.2018.01.007>. PMID:29550010.
24. Connert T, Zehnder MS, Weiger R, Kühl S, Krastl G. Microguided endodontics: accuracy of a miniaturized technique for apically extended access cavity preparation in anterior teeth. *J Endod*. 2017;43(5):787-90. <http://dx.doi.org/10.1016/j.joen.2016.12.016>. PMID:28292595.
25. Connert T, Krug R, Eggmann F, Emsermann I, ElAyouti A, Weiger R, et al. Guided endodontics versus conventional access cavity preparation: a comparative study on substance loss using 3-dimensional-printed teeth. *J Endod*. 2019;45(3):327-31. <http://dx.doi.org/10.1016/j.joen.2018.11.006>. PMID:30803541.
26. Carvalho CAT, Hasna AA, Carvalho AS, Vilela PDGF, Ramos LP, Valera MC, et al. Clinical study of sodium hypochlorite, polymyxin B and limewater effect on MMP-3,-8,-9 in apical periodontitis. *Braz Dent J*. 2020;31(2):116-21. <http://dx.doi.org/10.1590/0103-6440202003081>. PMID:32556009.
27. Rodrigues CT, Duarte MAH, Guimarães BM, Vivan RR, Bernardineli N. Comparison of two methods of irrigant agitation in the removal of residual filling material in retreatment. *Braz Oral Res*. 2017;31(0):e113. <http://dx.doi.org/10.1590/1807-3107bor-2017.vol31.0113>. PMID:29267674.
28. Abu Hasna A, Pinto ABA, Minhoto GB, Corazza BJM, Carvalho CAT, Ferrari CH. Pictograph system for diagnosis making and data management in endodontics. *Braz Dent Sci*. 2020;23(04):6p. <http://dx.doi.org/10.14295/bds.2020.v23i4.2056>.
29. Ferrari CH, Abu Hasna A, Martinho FC. Three Dimensional mapping of the root apex: distances between apexes and anatomical structures and external cortical plates. *Braz Oral Res*. 2021;35:e022. <http://dx.doi.org/10.1590/1807-3107bor-2021.vol35.0022>. PMID:33605353.

Amjad Abu Hasna
(Corresponding address)

Universidade Estadual Paulista, Institute of Science and Technology, Endodontics Division,
Department of Restorative Dentistry, São José dos Campos, SP, Brazil.
Email: d.d.s.amjad@gmail.com

Date submitted: 2021 Jun 29
Accept submission: 2021 Aug 06