



## CASE REPORT

DOI: <https://doi.org/10.4322/bds.2022.e3315>

# Rehabilitation of atrophic posterior partial edentulous maxilla with TTPHIL ALL TILT® technique: 3 year follow-up case report

Reabilitação de maxila atrófica posterior parcialmente desdentada com técnica TTPHIL ALL TILT®: relato de caso de acompanhamento de 3 anos

Puppala Venkata Ratne NAG<sup>1,2</sup> , Ramanathan MANIKANDHAN<sup>3</sup> , Puppala SARIKA<sup>4,5</sup> , Smitha DANIEL<sup>5</sup> , Kaligotla Apoorva VASUNDHARA<sup>5</sup> 

1 - Institute for Dental Implantology. Hyderabad, India.

2 - Panineeya Dental College, Department of Prosthodontics and Implantology. Hyderabad, India.

3 - Meenakshi Ammal Dental College. Chennai, India.

4 - SB Patil Dental College. Bidar, India.

5 - The Dental Specialists Clinic. Hyderabad, India.

## ABSTRACT

Maxillary sinus pneumatization pose a grave clinical challenge for implant fixed rehabilitation in posterior maxilla owing to diminished bone volume. This necessitates sinus lift and grafting which increase the duration and cost and possible surgical complications. Pterygoid implant has a greater short term osseointegration and is a proven treatment method for rehabilitation of highly resorbed posterior maxilla. To overcome the limitations of sinus grafting techniques, the current case report describes the use of flapless, tilted and pterygoid implant for restoration of partially edentulous atrophic maxilla eliminating grafting.

## KEYWORDS

Dental Implants; Immediate Dental Implant Loading; Jaw Edentulous Partially; Surgery Computer-Assisted; Case Reports.

## RESUMO

A pneumatização do seio maxilar representa um grande desafio clínico para a reabilitação fixa por implante na região posterior da maxila devido ao volume ósseo diminuído. Isso requer elevação do seio e enxerto, fatores que aumentam a duração, o custo e as possíveis complicações cirúrgicas. O implante pterigóide tem uma osseointegração maior em curto prazo e é um método de tratamento comprovado para reabilitação de maxila posterior altamente reabsorvida. Para superar as limitações das técnicas de enxerto de seio, o relato de caso atual descreve o uso de implante sem retalho, inclinado e pterigóide para restauração de maxila atrófica parcialmente edêntula eliminando o enxerto.

## PALAVRAS-CHAVE

Implantes Dentários; Carga Imediata em Implante Dentário; Arcada Parcialmente Edêntula; Cirurgia Assistida por Computador; Relatos de Casos.

## INTRODUCTION

A critical determining factor for favourable implant placement is optimal bone in all three dimensions. However, edentulous posterior maxillary rehabilitation using dental implants is frequently accompanied by anatomic constraints, mainly residual ridge resorption and maxillary sinus pneumatization [1]. This clinical scenario results in the diminished implant survival rates for maxillary posterior fixed rehabilitation [2]. In resorbed posterior maxilla, implant placement with sinus grafting is a common intervention for bone augmentation. However high treatment cost and time, donor site selection and morbidity along with lesser patient acceptance are possible limitations of sinus lifts. Insubstantial bone density in posterior maxilla also affects the outcome of implant success [3]. To overcome these negative aspects, treatment options, namely short implants [4]; or fixtures placed in zygoma [5] are documented in the literature. These approaches enhance surgical and prosthetic risks, decreasing the patient acceptance.

Employment of inclined implants harness morphologic features for placement, such as the septa, posterior or anterior wall of sinus, nose corticals, palatal bone, providing an alternative to bone augmentation [6,7]. These implants have significantly aided in the restoration of posterior maxilla by gaining bicortical anchorage and primary stability, thus, improving posterior support for better load distribution. However, it is associated with either biomechanical effects of cantilever or functional effects of reduction in the occlusal units [8]. Accurate bone dimensions can be established with 3D diagnostics, however, the esthetic and functional evaluations can be performed priorly with a single pre-examination operative [9]. In patients with minimal bone requiring full mouth implant rehabilitation, chewing ability can be enhanced with implant restoration anchored in maxillary anterior region resulting in cantilevers. Nevertheless, this treatment modality can be unpredictable in partially edentulous arches [10]. To achieve acceptable chewing capacity, optimum support is pertinent for load distribution in the areas of premolar and molar where maximum masticatory function takes place [11]. Further, chewing capacity is dependent on implant distribution in the arch [12]. Therefore, pterygoid implants represent a graftless treatment modality for

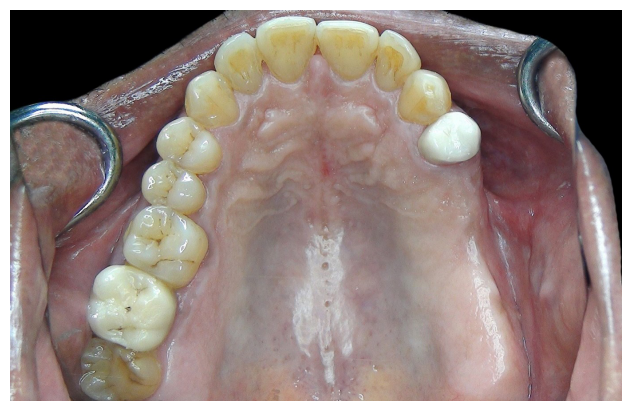posterior maxillary rehabilitation that anchors in pterygoid cortical bone, enhancing primary stability and extended success [13]. From a prosthetic perspective, it eliminates distal cantilever and allows to perform an immediate prosthetic load [14].

Guided implant surgery was suggested since last decade to minimize the invasiveness of the surgical procedure through flapless technique [15]. Digital technology employs the localizing capabilities of three-dimensional imaging and executes implant surgery with an appropriate guidance system. The efficacy of digital implant planning and stents to achieve high precision of implant placement into any bone type have been illustrated by various authors [16].

The objective of present case report is to delineate the rehabilitation of atrophic posterior partially edentulous maxilla without sinus grafting employing tilted implant and pterygoid implant.

## CASE REPORT

A 61-year-old male visited Institute for Dental Implantology, Hyderabad in March 2018 with the chief complaint of replacement of missing upper back teeth with immediate functional teeth (Figure 1). Past dental history revealed missing teeth #25,26,27,46. He had visited another clinic and was told that sinus lift along with delayed implant surgery was required due to sinus pneumatization. However, the patient was not willing for multiple surgeries and had come for a second opinion. The patient also had a crown fracture wrt #47. Following diagnostic orthopantomogram (Figure 2) and



**Figure 1** - Pre-operative occlusal view of partially edentulous maxilla.

cone-beam computed tomography (Figure 3), patient was told the option of TTPHIL ALL TILT® technique and the purpose of immediate implants without grafting and immediate function. This technique employs two-piece, long tilted implants engaging the corticals of the nasal bone, maxillary sinus and pterygoids with subcrestal placements in a flapless manner. After taking signed consent for the treatment plan, CBCT DICOM data was used for virtual implant planning and fabrication of stereolithographic model and surgical stents for flapless guided surgery (Figure 3).

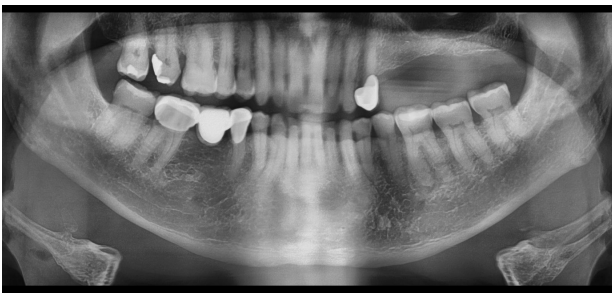


Figure 2 - Panoramic view of the patient.

### Surgical protocol

Lignocaine with Epinephrine (1:100,000) was administered for the implant surgery. Pre and post surgical medication included Augmentin 625 mg (antibiotic) 1 hour prior to surgery and once daily for next 5 days; prednisone 15 mg to 5 mg (corticosteroid) daily from the day of surgery upto 4 days in a tapering manner; clonidine 300mg (analgesic) once daily for 4 days; Ibuprofen 600 mg (anti-inflammatory) on the fourth day postoperatively; omeprazole 20 mg (antiacid) once daily for 5 days postoperatively were administered. A stereolithographic surgical stent with metal guides was used for flapless placement (Figure 4a). Underdrilling of the implant site using single drill was employed in order to obtain minimum 50 N/cm of primary anchorage enabling immediate function. 20 degrees mesial tilt in relation to the anterior wall of maxillary sinus was used for anterior implant to achieve bicortical anchorage by fixating in nasal cortical (Figure 4b-d). Distally

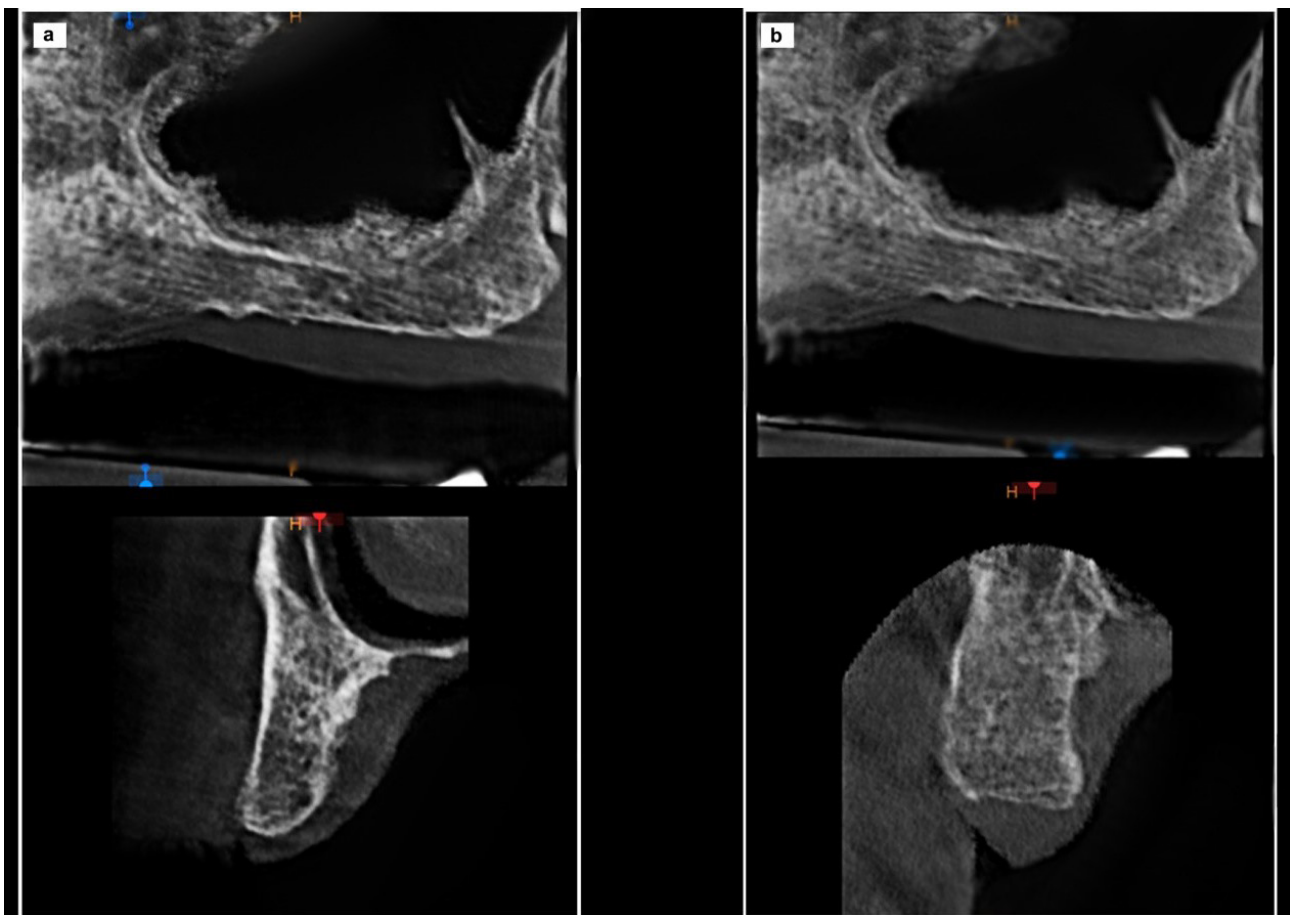
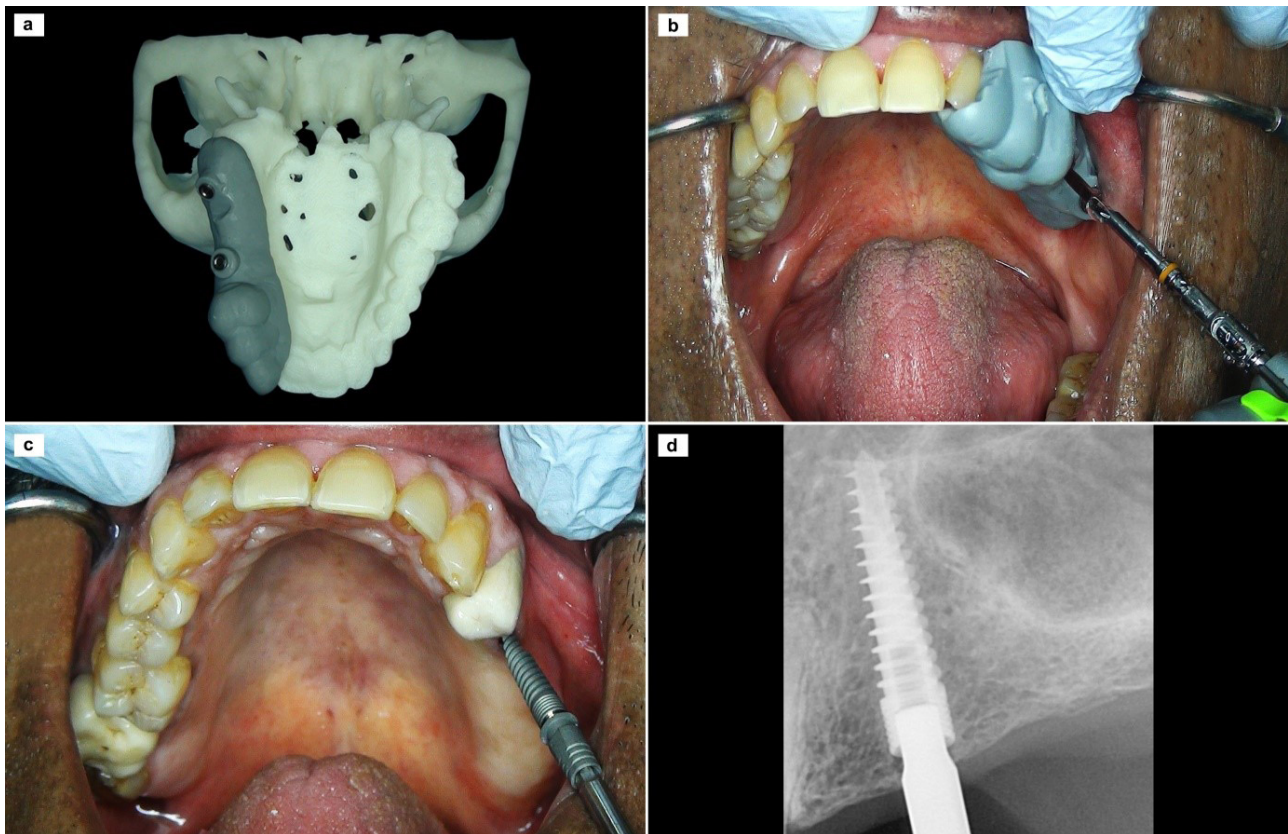


Figure 3 - (a) Cone beam computer tomography image in the region of 25; (b) Cone beam computer tomography image of maxillary left pterygoid region.



**Figure 4** - (a) 3D printed stereolithographic model with surgical stent; (b) Intra oral view of surgical guide with single drill placement in the region of 25; (c) Implant placement in the region of 25; (d) RVG of the implant placed in the region of 25.

tilted pterygoid implants were inclined 45 degrees for the purpose of anchorage in pterygoid cortical plate, avoidance of maxillary sinus penetration, and for posterior shift of implant platform as much as possible (Figure 5a-c). For compensating implant inclination, 30-degree and 20-degree multi-unit abutments were attached in posterior and anterior implants respectively (Figure 6a). The length of the pterygoid implant (BiolineDental GmbH&Co.KG, Berlin, Germany) was 3.75x21mm and anterior tilted implant with nasopalatal inclination was 3.75x16 mm.

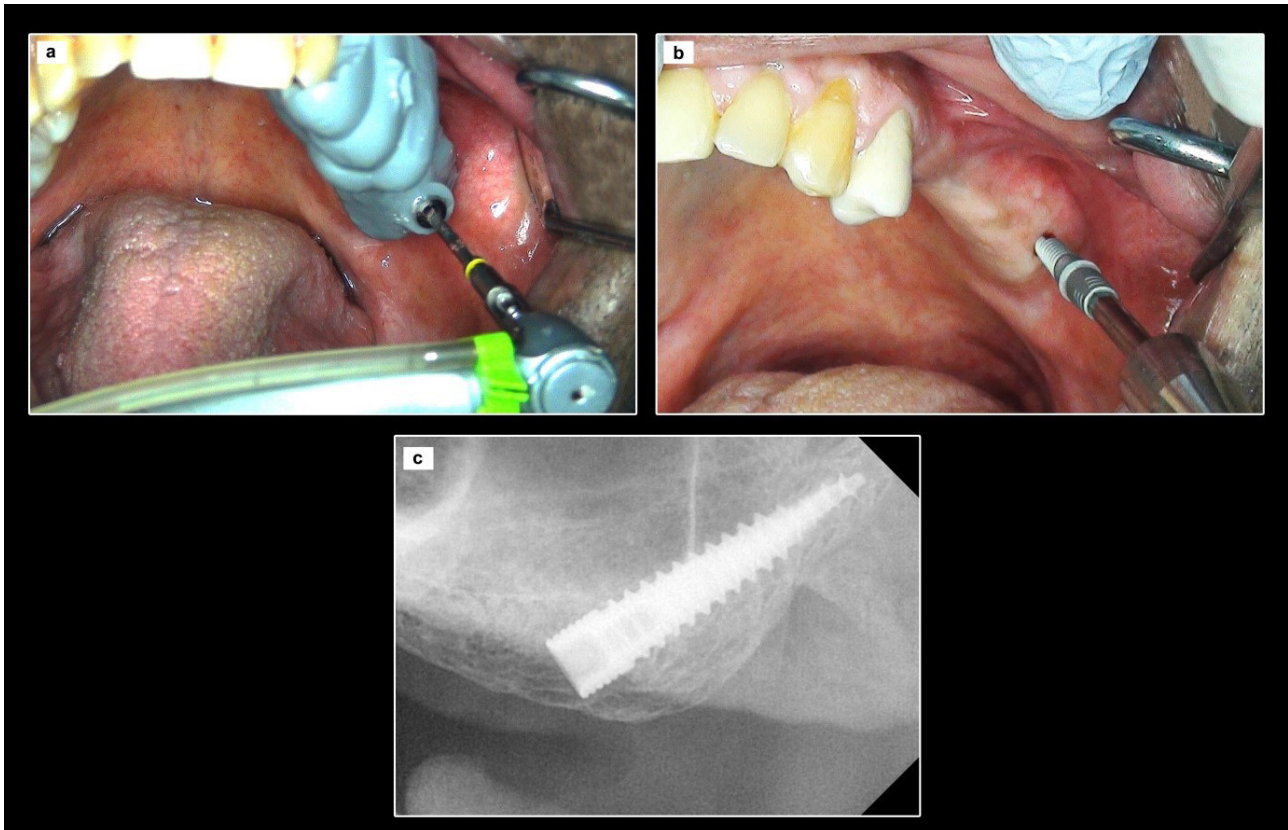
### Prosthetic protocol

An elastomeric impression was performed immediately following the implant surgery (Figure 6b, c). After detaching impression copings, healing abutments were attached. Screw retained metal-ceramic bridge #25,26,27,28 was fabricated and bisque tryin was done on the next day for eliminating excursive contacts (Figure 7a, b). Following glazing, the prosthesis was torqued to 35 N/cm. Review was done the next day, followed up with one week, one, three and six months reviews which were uneventful.

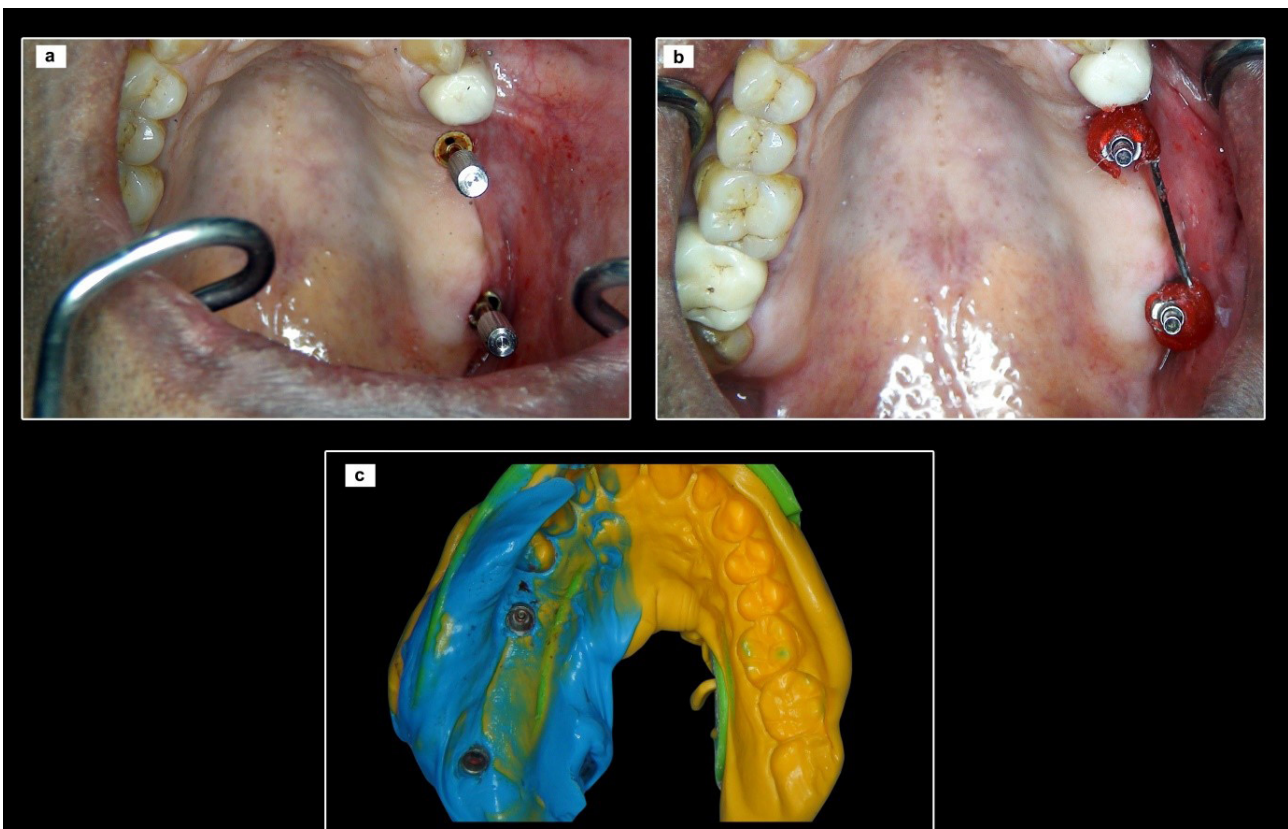
Following which, the patient came for yearly follow up and regular oral prophylaxis was performed. A 3 year postoperative clinical and three-dimensional CBCT review showed healthy soft tissues around the prosthesis and stable bone levels (Figure 8a-c).

### DISCUSSION

Posterior maxilla has limited vertical height availability and has poor marrow quality, vascularity and bone density [17]. Treatment modalities including bone augmentations, sinus grafts and short implants are used for rehabilitation of areas affected by poor quantity and quality bone. Despite their widespread usage among clinicians, the results of these therapeutic options are undermined [18]. Therefore, the treatment modalities are shifting towards minimally invasive immediate function protocols. One such treatment modality is TTPHIL ALL TILT® technique that employs anatomic features of nasal cortical and pterygoid bone aiding in immediate function [19,20]. It also provides second molars without cantilever, unlike



**Figure 5** - (a) Intra oral view of surgical guide with single drill placement in the pterygoid region; (b) Implant placement in the pterygoid region; (c) Radiographic view of the implant placed in the pterygoid region.



**Figure 6** - (a) Multi unit abutment placement showing parallelism; (b) Splinting of abutment with pattern resin; (c) Elastomeric impression with transfer copings attached.

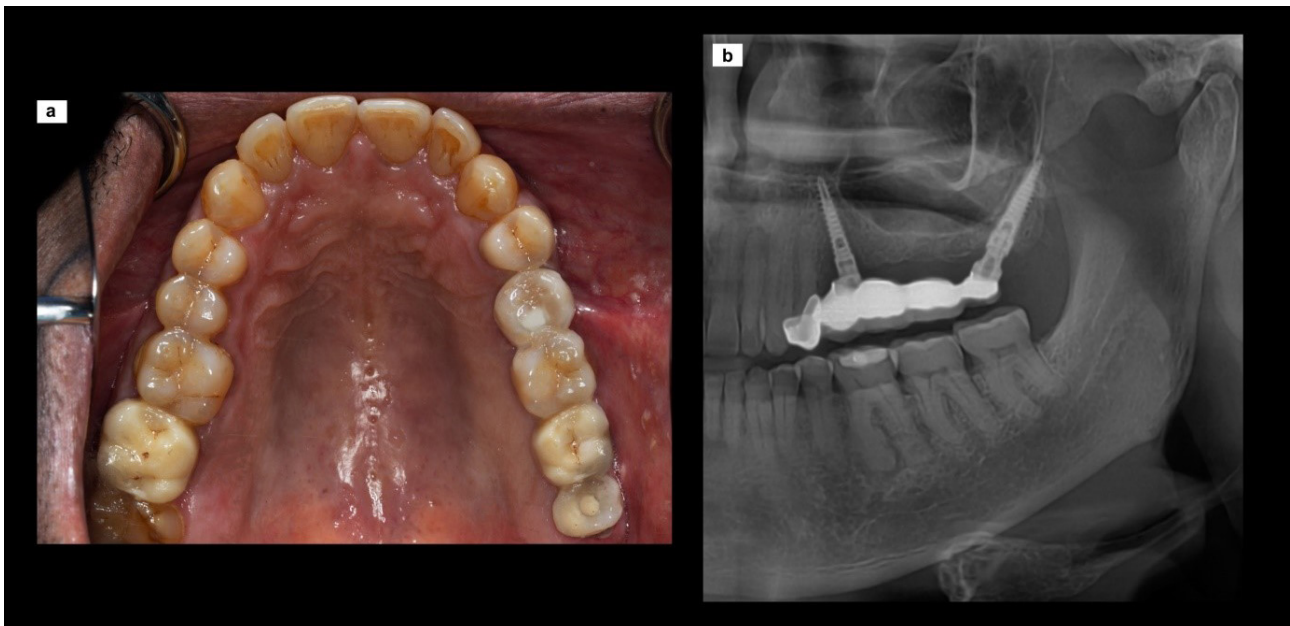


Figure 7 - (a) Occlusal view of screw retained definitive prosthesis; (b) Post operative panoramic view of prosthesis.

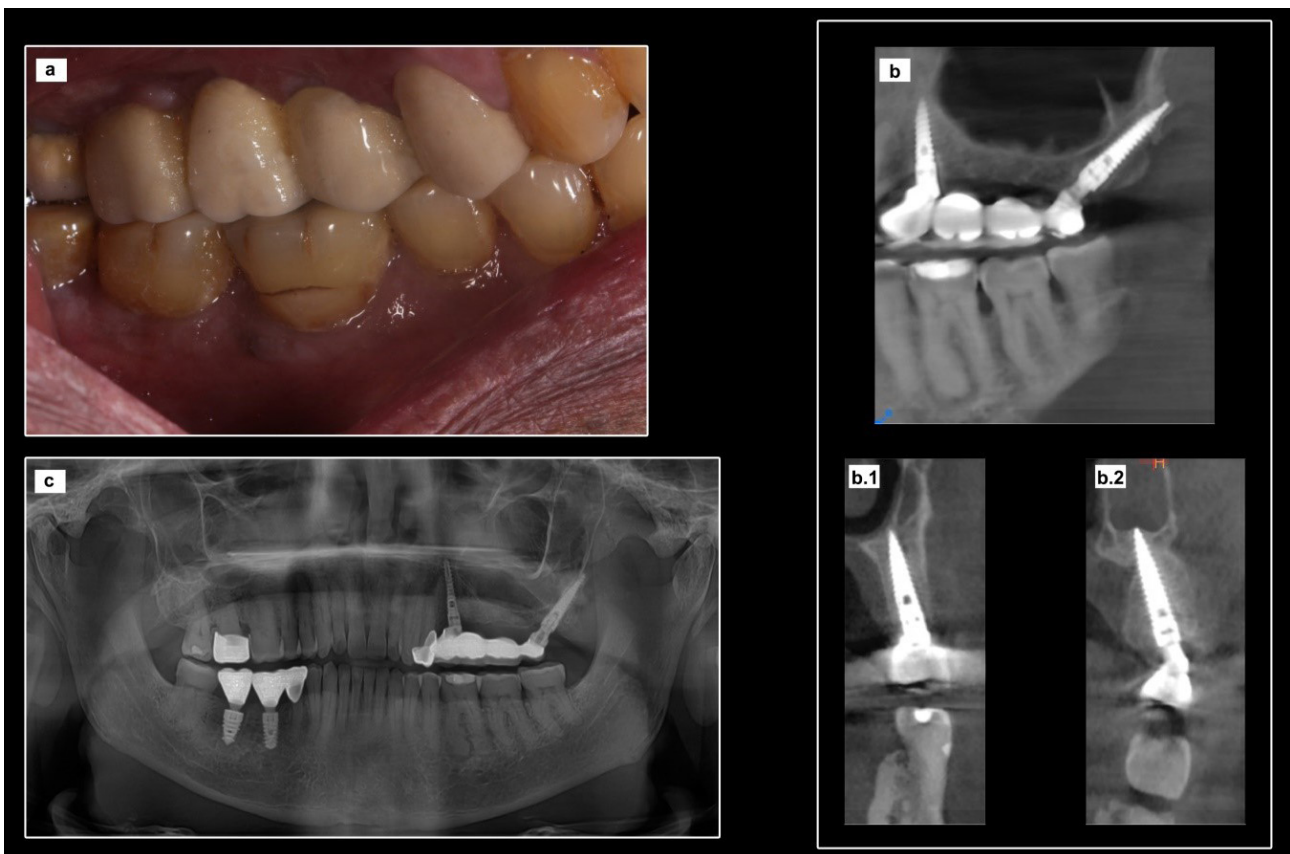


Figure 8 - (a) Lateral view of 3 year follow up of prosthesis; (b) CBCT view of 3 year follow up of prosthesis in the region of 25 (b.1) and pterygoid region (b.2); (c) Panoramic view of 3 year follow up of the patient.

other techniques which eliminate second molars to minimise cantilevers. They are capable of providing support for immediate fixed prostheses owing to osseofixation and high primary stability

and subsequent osseointegration [17]. This case report elucidates graftless implant treatment modality along with immediate functional load in resorbed sinus region.

The tilting of implants allows placement of longer implants in the available residual bone, enhancing bone-implant contact area and primary anchorage [21]. Utilising anatomic features of the maxillary bone, inclined implants have the advantage of expanding the prosthetic base of the arch [22]. Pterygoid implant is placed posteriorly allowing a greater distance between implants. This favourable interimplant distance facilitates the addition of second molars to the prosthesis along with elimination of cantilever, resulting in better load distribution [21]. The two implants are placed in such a way that a maximum of two pontics were placed between abutments which is significant for biomechanical success [23]. Further, longer implants enable their usage in areas of high masticatory loads [24]. This case report is unique due to the combination of tilted anterior implant and pterygoid implant for rehabilitation of four missing posterior teeth.

TTPHIL ALL TILT® technique is used for surgical and prosthetic protocol making it minimally invasive. It utilises the guided implant systems for virtual implant planning and fabrication of stereolithographic models and stents [25]. It enables flapless placement and allows implant placement in deficient bone. The benefits of this implant placement method as a therapeutic option encompasses patient-centric and clinician centric benefits. It shortens surgical time and overall treatment duration by avoiding of grafts thereby reducing treatment cost. Further, it improves clinician's surgical ease as well as patient's acceptance of treatment, especially in severely resorbed posterior maxillary rehabilitations wherein bone harvest is done from morbid sites.

This case report elucidates a severely atrophic posterior maxillae, wherein the use of CBCT images and guided implant planning software allows implant placement and early prosthetic load without grafting. Additional studies with long term follow up are required to substantiate the results of technique. Nevertheless, a guided implant planning system can be the potential aid in rehabilitation of these clinical situations.

## CONCLUSION

Use of tilted implants with palatonasal inclination and pterygoid implant with guided implant surgery have rendered satisfactory implant and prosthetic success at 3 year follow-up

minimising treatment duration, waiting time and increasing patient acceptance. Nevertheless its use in more number of clinical cases will bring further validation.

## Author's Contributions

PVRN: Concept, Design of the technique, Data analysis. RM: Literature search, Manuscript review. PS: Data acquisition, Data analysis. SD: Data analysis, Manuscript preparation, Manuscript editing. KVAV: Manuscript preparation, Manuscript review.

## Conflict of Interest

None.

## Funding

None.

## Regulatory Statement

Signed informed consent form has been taken from the patient for the disclosure of the case.

## REFERENCES

- Wallace SS, Froum SJ. Effect of maxillary sinus augmentation on the survival of endosseous dental implants. A systemic review. *Ann Periodontol.* 2003;8(1):328-43. <http://dx.doi.org/10.1902/annals.2003.8.1.328>. PMID:14971260.
- Becker W, Becker B, Alsuwyed A, Al-Mubarak S. Long term evaluation of 282 implants in maxillary and mandibular molar position: a prospective study. *J Periodontol.* 1999;70(8):896-901. <http://dx.doi.org/10.1902/jop.1999.70.8.896>. PMID:10476898.
- Sogo M, Ikebe K, Yang TC, Wada M, Maeda Y. Assessment of bone density in the posterior maxilla based on Hounsfield units to enhance the initial stability of implants. *Clin Implant Dent Relat Res.* 2012;14(Suppl. 1):e183-7. <http://dx.doi.org/10.1111/j.1708-8208.2011.00423.x>. PMID:22176704.
- Maló P, Araújo Nobre M, Lopes A. Short implants in posterior jaw: a prospective 1-year study. *Eur J Oral Implantology.* 2011;4(1):47-53. PMID:21594219.
- Maló P, Araújo Nobre M, Lopes I. A new approach to rehabilitate the severely atrophic maxilla using extramaxillary anchored implants in immediate function: a pilot study. *J Prosthet Dent.* 2008;100(5):354-66. [http://dx.doi.org/10.1016/S0022-3913\(08\)60237-1](http://dx.doi.org/10.1016/S0022-3913(08)60237-1). PMID:18992569.
- Calandriello R, Tomatis M. Simplified treatment of the atrophic posterior maxilla via immediate/early function and tilted implants: A prospective 1-year clinical study. *Clin Implant Dent Relat Res.* 2005;7(s1, Suppl supp1):S1-12. <http://dx.doi.org/10.1111/j.1708-8208.2005.tb00069.x>. PMID:16137082.
- Del Fabbro M, Bellini CM, Romeo D, Francetti L. Tilted implants for the rehabilitation of edentulous jaws. A systematic review.

- Clin Implant Dent Relat Res. 2012;14(4):612-21. <http://dx.doi.org/10.1111/j.1708-8208.2010.00288.x>. PMID:20491823.
8. Maló P, Agarwal A, Araújo Nobre M. Partial rehabilitation of the posterior edentulous maxilla using axial and tilted implants in immediate function to avoid bone grafting. *Compend Contin Educ Dent*. 2011;32(9):E136-45. PMID:23627307.
  9. Alhammedi MS, Al-Mashraqi AA, Alnami RH, Ashqar NM, Alamir OH, Halboub E, et al. Accuracy and reproducibility of facial measurements of digital photographs and wrapped cone beam computed tomography (CBCT) photographs. *Diagnostics*. 2021;11(5):757. <http://dx.doi.org/10.3390/diagnostics11050757>. PMID:33922543.
  10. Krekmanov L, Kahn M, Rangert B, Lindstrom H. Tilting of posterior mandibular and maxillary implants for improved prosthesis support. *Int J Oral Maxillofac Implants*. 2000;15(3):405-14. PMID:10874806.
  11. Krekmanov L. Placement of posterior mandibular and maxillary implants in patients with severe bone deficiency: a clinical report of procedure. *Int J Oral Maxillofac Implants*. 2000;15(5):722-30. PMID:11055139.
  12. Krekmanov L, Rangert B. Tilting of posterior implants for additional support of the bridge base. *Int J Oral Maxillofac Surg*. 1997;26(Suppl. 1):38. [http://dx.doi.org/10.1016/S0901-5027\(97\)80958-7](http://dx.doi.org/10.1016/S0901-5027(97)80958-7).
  13. Fuh LJ, Huang HL, Chen CS, Fu KL, Shen YW, Tu MG, et al. Variations in bone density at dental implant sites in different regions of the jawbone. *J Oral Rehabil*. 2010;37(5):346-51. <http://dx.doi.org/10.1111/j.1365-2842.2010.02061.x>. PMID:20113389.
  14. Bidra AS, Huynh-Ba G. Implants in the pterygoid region: A systematic review of the literature. *Int J Oral Maxillofac Surg*. 2011;40(8):773-81. <http://dx.doi.org/10.1016/j.ijom.2011.04.007>. PMID:21601424.
  15. Tatakis DN, Chien H-H, Parashis AO. Guided implant surgery risks and their prevention. *Periodontol 2000*. 2019;81(1):194-208. <http://dx.doi.org/10.1111/prd.12292>. PMID:31407433.
  16. Widmann G, Bale RJ. Accuracy in computer-aided implant surgery: a review. *Int J Oral Maxillofac Implants*. 2006;21(2):305-13. PMID:16634503.
  17. Oliveira Nicolau Mantovani AK, Mattias Sartori IA, Azevedo-Alanis LR, Tiozzi R, Fontão FNGK. Influence of cortical bone anchorage on the primary stability of dental implants. *Oral Maxillofac Surg*. 2018;22(3):297-301. <http://dx.doi.org/10.1007/s10006-018-0705-y>. PMID:29876688.
  18. Esposito M, Grusovin MG, Rees J, Karasoulos D, Felice P, Alissa R, et al. Effectiveness of sinus lift procedures for dental implant rehabilitation: a Cochrane systematic review. *Eur J Oral Implantology*. 2010;3(1):7-26. PMID:20467595.
  19. Nag PVR, Dhara V, Puppala S, Bhagwatkar T. Treatment of the complete edentulous atrophic maxilla: the Tall Tilted Pin Hole Placement Immediate Loading (TTPHIL)-ALL TILT™ implant option. *J Contemp Dent Pract*. 2019;20(6):754-63. <http://dx.doi.org/10.5005/jp-journals-10024-2592>. PMID:31358722.
  20. Venkat Ratna Nag P, Sarika P, Bhagwatkar T, Dhara V. Angulated implant a novel concept for rehabilitation of severe atrophic maxilla with 3 years follow up supported by Finite Element Analysis. *J Osseointegr*. 2020;13(1):39-44.
  21. Maló P, Araújo Nobre M, Lopes A, Rodrigues R. Preliminary report on the outcome of tilted implants with longer lengths (20-25 mm) in low-density bone: one-year follow-up of a prospective cohort study. *Clin Implant Dent Relat Res*. 2015;17(Suppl. 1):e134-42. <http://dx.doi.org/10.1111/cid.12144>. PMID:24004159.
  22. Fortin T, Isidori M, Bouchet H. Placement of posterior maxillary implants in partially edentulous patients with severe bone deficiency using CAD/CAM guidance to avoid sinus grafting: a clinical report of procedure. *Int J Oral Maxillofac Implants*. 2009;24(1):96-102. PMID:19344031.
  23. Resnik R. Misch's contemporary implant dentistry: treatment plans related to key implant positions and implant number. 4th ed. St. Louis: Elsevier; 2020. 470 p.
  24. Barnea E, Tal H, Nissan J, Tarrasch R, Peleg M, Kolerman R. The use of tilted implant for posterior atrophic maxilla. *Clin Implant Dent Relat Res*. 2016;18(4):788-800. <http://dx.doi.org/10.1111/cid.12342>. PMID:25853626.
  25. Kernen F, Kramer J, Wanner L, Wismeijer D, Nelson K, Flügge T. A review of virtual planning software for guided implant surgery - data import and visualization, drill guide design and manufacturing. *BMC Oral Health*. 2020;20(1):251. <http://dx.doi.org/10.1186/s12903-020-01208-1>. PMID:32912273.

**P. Venkat Ratna Nag**  
(Corresponding address)

Institute for Dental Implantology, Hyderabad, India.  
Email: [tdspublication@gmail.com](mailto:tdspublication@gmail.com)

Date submitted: 2021 Nov 18  
Accept submission: 2022 May 22