



## 3D stereophotogrammetry quantification for tissue repositioning using Botulinum toxin A: a case report

Quantificação por estereofotogrametria 3D para reposicionamento tecidual com Toxina botulínica A: relato de caso

Victor ROGERIO<sup>1</sup> , Janafina Badin CARVAS<sup>1</sup> , Marcelo Germani VIEIRA<sup>1,2</sup> , Viviane RABELO<sup>1</sup> , Pietra ROSCHEL<sup>1</sup> , Victor Ricardo Manuel MUNOZ-LORA<sup>1,2</sup>

1 - Let's HOF Academy, São Paulo, Brazil

2 - Departamento de Investigação em Odontologia, Faculdade de Odontologia, Universidade Ibirapuera, São Paulo, Brazil

### ABSTRACT

Hereby, we objectively assessed the outcomes of a facial-lifting procedure with Botulinum toxin type A (BoNT-A) using a 3D stereophotogrammetry quantification (3D-SQ). A 46-year-old female patient received a full face BoNT-A treatment in a total dose of 180 Speywood Units (sU). Frontal, lateral and oblique photographs were taken before and 20 days after treatment, at rest and during mimic movements. Also, a facial scanning was performed before and 20 days after BoNT-A injections. The results were analyzed using a 3D-SQ software. The photographs showed a decrease in expression lines and dynamic wrinkles. In addition, a better-defined jawline and volume gain in the midface area with improvement of the profile appearance, due to the reduction of the sagging skin under the chin, was observed. The 3D-SQ showed volume gains of 1.17 ml on the right and of 1.59 ml on the left cheekbone areas, due to the cranially soft-tissue repositioning. In addition, a decrease in the volume of melomental folds areas (0.27ml on the right and 0.41 ml on the left side) was reported, compatible to the above-mentioned volume gain. Measurements considering cephalometric points showed a decrease in the total facial height (distance from Trichion to Mental points), suggesting a soft tissue dislocation in an upward direction. Finally, this case report showed quantitative results that can evidence the role of BoNT-A in facial-lifting procedures. These results reinforce the importance of using a 3D-SQ to assess the outcomes of BoNT-A and, probably, other aesthetic procedures.

### KEYWORDS

Botulinum Toxin; Platysma; Facelifting; 3D images; Quantificare.

### RESUMO

No presente estudo avaliamos objetivamente os resultados de um procedimento de lifting facial com toxina botulínica tipo A (BoNT-A) usando uma quantificação de estereofotogrametria 3D (3D-SQ). Uma paciente do sexo feminino de 46 anos recebeu um tratamento facial completo com BoNT-A em uma dose total de 180 unidades Speywood (sU). Fotografias frontais, laterais e oblíquas foram tomadas antes e 20 dias após o tratamento, em repouso e durante os movimentos mímicos. Além disso, um escaneamento facial foi realizado antes e 20 dias após as injeções de BoNT-A. Os resultados foram analisados por meio de um software 3D-SQ. As fotografias mostraram uma diminuição das linhas de expressão e rugas dinâmicas. Além disso, observou-se um maxilar mais bem definido e ganho de volume na região média da face com melhora da aparência do perfil, devido à redução da flacidez da pele sob o queixo. O 3D-SQ apresentou ganho de volume de 1,17 ml à direita e 1,59 ml à esquerda, devido ao reposicionamento do tecido mole. Além disso, foi relatada diminuição do volume das áreas do sulco mental (0,27 ml à direita e 0,41ml à esquerda), compatível com o ganho de volume acima citado. As medidas considerando os pontos cefalométricos mostraram uma diminuição da altura facial total (distância dos pontos Triquion ao Mental), sugerindo um deslocamento superior dos tecidos moles. Em conclusão, este relato de caso mostrou resultados quantitativos que podem evidenciar o papel da BoNT-A em procedimentos

de lifting facial. Esses resultados reforçam a importância da 3D-SQ para avaliar objetivamente os resultados de harmonização orofacial com BoNT-A e outros materiais.

## PALAVRAS-CHAVE

Toxina botulínica, platisma, lifting facial, imagens 3D, Quantificare.

## INTRODUCTION

Botulinum toxin type A (BoNT-A) injections have been successfully used as minimally invasive procedures for facial rejuvenation. BoNT-A acts as a neuromodulator, blocking the release of acetylcholine from the peripheral cholinergic nerve terminals, thus preventing muscle contraction [1,2]. In this way, an effective reduction of the dynamic wrinkles and hyperfunctional lines can be obtained. This aesthetical approach is commonly used in the upper face and, with less frequency, in the lower face and neck area [3].

The injection of BoNT-A into specific muscles of the lower face and neck area can be considered as an advanced technique for the reduction of mouth frown, labiomental folds, mental crease, hyperfunctional platysmal bands, and horizontal necklines. Moreover, it is essential to consider the critical role of these muscles on facial skin displacement and tissue repositioning [4]. Facial muscles are directly, indirectly or loosely attached to facial skin, so paralyzing them with neuromodulators, like BoNT-A, can result on facial skin displacement [4,5]. For upwards tissue repositioning, also known as facial-lifting, the upper platysma plays an important role since it acts as a major depressor muscle [5]. By these means, it seems reasonable that BoNT-A treatments on this muscle release the downward tension on the jawline by alleviating its pulldown effect and generating a soft tissue lifting effect [3]

Outcomes of BoNT-A procedures are usually measured using before and after photographs, clinical evaluations with validated scales, and patient's reports [6]. However, there is a lack of quantitative methods to assess the outcomes of BoNT-A treatments. By this way, the 3D stereophotogrammetry quantification (3D-SQ) is an innovative and non-invasive methodology that can mathematically assess the outcomes by quantifying volumetric changes and soft tissue dislocation. It is an excellent and novel tool for clinical documentation that provides important data with an objective assessment of the efficacy

of BoNT-A aesthetic outcomes [7]. Hereby, we report a case of an objective assessment of the clinical outcomes after a facial-lifting procedure with BoNT-A using a 3D-SQ.

## CASE REPORT DESCRIPTION

A 46-year-old female patient, looking for a facial rejuvenation procedure, attended to the Let's HOF clinic in São Paulo, Brazil. No history of previous applications of BoNT-A, facial fillers, and/or biostimulators were related by the patient. After a careful evaluation by our experts and explaining all possible options, a full-face rejuvenation procedure using BoNT-A was indicated.

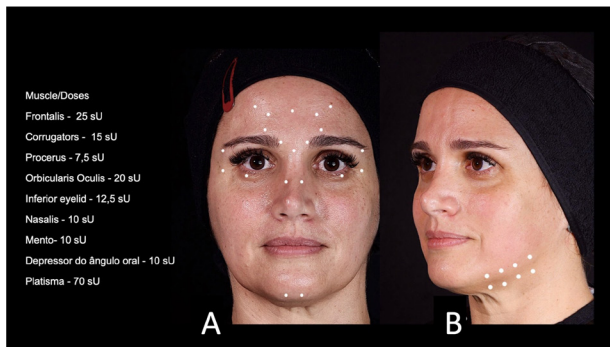### BoNT-A applications

The patient was treated with a total of 180 Speywood Units (sU) of abobotulinumtoxin A (Dysport®, Galderma, Brazil). For this, a 300sU vial of abobotulinumtoxin A was reconstituted on a 1.2 ml of sterile saline solution. The saline solution was slowly injected into the BoNT-A vial using a 22G needle adapted to a 5 ml syringe. Then, the vial was kindly mixed for 2 minutes to achieve a full reconstitution of the toxin.

BoNT-A injections were performed with the patient lying in a 45-degree position. Antisepsis of the skin was realized with non-alcoholic chlorhexidine 2% applied to all face after the patient had washed the face with water and soap. In order to reduce the discomfort during injection, a topical anesthetic (Pliaglis®, Galderma, Brazil) containing lidocaine (70mg/g) and tetracaine (70mg/g) was applied 20 minutes before the procedure. The sites of injection were marked with a white dermatographic pencil (Galderma, Brazil) as shown in Figure 1. The intramuscular injections were performed using 0.3 ml insulin syringes with a 31-gauge needle (Becton Dickinson, NJ, USA).

### Photographic and facial images capture

Photographs using a semi-professional photographic camera (Canon EOS Rebel T5i,



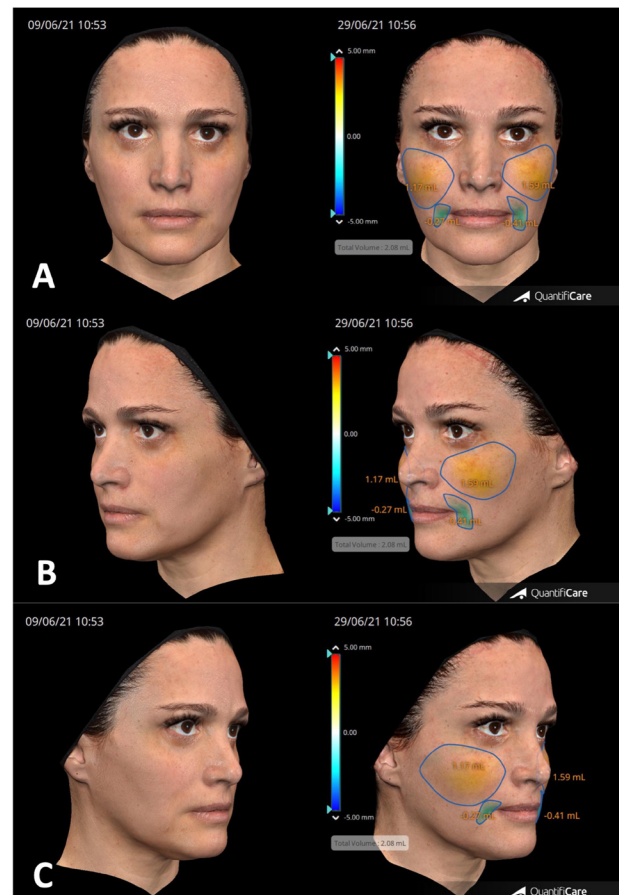
**Figure 1** - Doses per area and schematic representation of BoNT-A injection points from a (A) frontal and (B) side view.

Canon, USA) were taken before and 20 days after BoNT-A treatment. Photos were taken at different angles including frontal, lateral and oblique views during rest and contraction of the assessed muscles. In addition, a facial scanning using a 3D-SQ three-dimensional image capture system (3D Life Viz™ Mini-Quantificare, Sophia Antipolis, France) was realized before and 20 days after BoNT-A applications (Figure 2 and 3). The 3D-SQ system is based on passive stereophotogrammetry and includes a customized digital camera of 13.5-24 million pixels (Nikon 3200, Nikon, Japan). Photographs were taken from a standardized distance of 70 cm and the camera was held perpendicular to the targeted point.

The 3D-SQ camera captures two images simultaneously from different angles and a software (DermaPix Database for photo documentation, Quantificare, Sophia Antipolis, France) automatically integrates the stereo images and produces a three-dimensional reconstruction. The LifeViz™ app for computing and managing images in 3D calculates and appoints the differences in between the analyzed images [6,8]. This software has specific tools to compare the 3D images obtained before and after the procedures. It is also capable to report the soft tissue dislocation, as well as the volumetric changes calculated in the outlined area by estimating the differences observed. This alteration is converted in milliliters (ml) and translated into a colorimetric scale that marks in yellow the volume gain areas and, in green the volume loss areas, showing the obtained outcomes.

## Results obtained

The quantifications obtained by 3D-SQ are presented on Figures 2 and 3. Volume

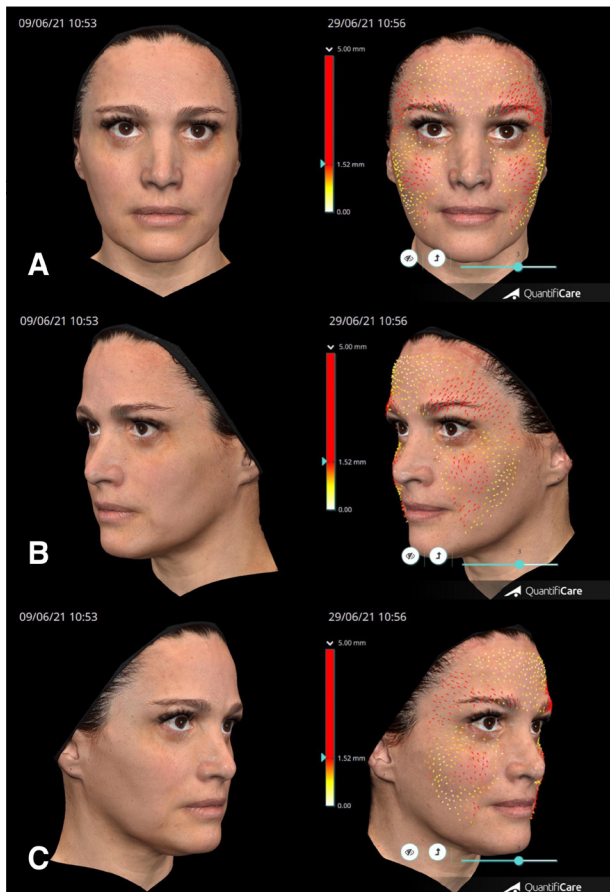


**Figure 2** - Quantification of the facial soft tissue volume obtained by 3D Life Viz™ Mini- Quantificare from a (A) frontal, (B) left lateral and (C) right lateral view. Volume gains on the cheekbone areas are colored in yellow and volumes losses on the melomental folds (i.e. marionette lines) are colored in green.

gains of 1.17 ml and 1.59 ml on the right and left cheek respectively were observed. Volume loss of 0.27 ml and 0.41 ml on the right and left melomental folds (i.e. marionette lines) area were also found (Figure 2). Soft tissue displacement upwards is shown in red arrows and static in yellow arrows (Figure 3).

Cephalometric points used to analyze facial proportions were obtained by the software in order to measure the linear distances between them, and to compare the changes observed after treatment. The points obtained to perform the measurements were: Trichion (Tr) - the midline hairline point, Nasion (N) - the deepest point in the intersection between the nasal and frontal bones, Pronasion (Prn) - the most prominent location of the nasal tip, on the mid-axis of the apex nasi, Menton (Me) - the most inferior point of the mandibular symphysis, Stomio (St) - a point located at the intersection of the upper and lower lips on the midfacial line. The distances between these points were obtained to quantify





**Figure 3** - The "Quantificare Analysis 3D viewer +" software calculates the volumetric changes and soft tissue displacement in between the initial and final images. Upward displacement of soft tissue is shown in red arrows and static tissue in yellow arrows from a (A) frontal, (B) left lateral and (C) right lateral view.

the soft tissue repositioning. The results showed a 1.21 mm decrease in the analyzed image total facial height, observed by the distance from T to Me. A diminished distance was observed between N to Prn points, ranging from 36.47 to 34.99 mm, suggesting a midface soft tissue elevation; and the distance between N to St diminished from 67.57 mm to 66.59mm reinforcing this perception. The distance between Prn to M enhanced, ranging from 66.05 mm to 66.52mm, in contrast to other measurements, showing an upward movement of the midface. The total high from the N to Me diminished from 102.52 mm to 101.51 mm.

There were no side effects reported.

## DISCUSSION

BoNT-A is a popular aesthetic treatment used in the upper face for facial rejuvenation. Less commonly, BoNT-A is used in the lower face to address perioral lines and platysmal bundles, in

order to produce a face-lifting action and improve the facial contour [9,10]. Hereby, we presented data of soft tissue repositioning after BoNT-A injections, objectively assessed by 3D-SQ. Upward soft tissue displacement represented by bilateral volume gains on the cheek and bilateral volume loss on the melomental folds were observed and will be discussed thereafter.

The presented data, obtained by 3D-QS analysis, proved to be a reliable and innovative tool to mathematically demonstrate the dislocation of the soft tissues in an upward direction (Figure 3), clarifying the role of BoNT-A in the facial-lifting procedure. The volumetric changes (Figure 2) are of greater importance and elucidate how the facial muscles are also responsible for the facial ptosis that takes place on the aging process. The three-dimensional quantification of the outcomes fills the gap of scientific evaluation in minimally invasive facial aesthetic treatments [6], bringing more confidence and satisfaction for professionals and patients. Since this evaluation is not subjective, and is highly effective and replicable, the 3D images obtained, and software analysis can be an objective endpoint for the guidance of clinical aesthetic protocols.

Even though the role of the facial platysma in lower face dynamics and contour is already well known, the facial-lifting effect is an interesting outcome that is not common for the physicians that are still unsecure for not knowing the benefit of this technique [9]. It is important to consider that all facial tissues are anatomically interconnected [11,12], so the lifting effect may also be influenced by the paralysis of other upper mimic muscles [13]. However, as the platysma acts as the major lower depressor muscle, it is expected that most of the lifting effect is caused by its paralysis [9]. Importantly, platysma pars labialis, may have some fibers interdigitated and blended to the mentalis muscles. Therefore, injecting neuromodulator into this muscle (i.e. mentalis muscle) will also help to improve chin contour and diminish downwards movement of the platysma [9]. The paralysis of the platysma resulted in a superior repositioning of the soft tissues, including the superior and inferior jowl fat pads, beyond the submandibular jowl fat compartment.

The quantification of these results was mathematically achieved by a volumetric augment of 1.17 ml in the right side and 1.59 ml in the

left cheekbone area (Figure 2), as well as the soft tissue displacement upwards shown by the red arrows, suggesting the facelift effect (Figure 3). The volume reduction in the melomental folds of 0.27 ml in the right side and 0.41 ml in the left side, are compatible to the volume gain immediately above, showing the soft tissue cranially dislocation. We did not inject the platysmal bands, and the injection points performed at the mandibular border were sufficient to achieve the described outcomes.

Our results showed a facelift effect over the mandibular border, diminishment of the jowls and marionette lines, and the enhancement of the jawline with a volume gain in cheekbone area and soft tissue displacement upwards. All these results might be correlated to the attachment of the superficial fibers of the platysma into the mandibular septum adjacent to the subcutaneous overlapping fat compartments at the mandibular border [11,14]. As a limitation of this methodology, clinicians must consider the cost of the 3D-QS device. Although the acquisition of a 3D-QS device represents a single investment, currently the cost of the device may be considered high, and should be evaluated according to the necessity.

## CONCLUSION

This case report showed that 3D-QS can be an objective guidance to assess tissue repositioning after aesthetic procedures like BoNT-A injections, although it may represent an investment for the clinician. Hereby, we also evidenced the important role of BoNT-A injections in the lower face to obtain facial-lifting results.

## Author's Contributions

VR: Conceptualization, Design, Writing, Executing the Procedure. JBC: Executing the procedure. MG: Conceptualization, Executing the Procedure, Data Curation. VR: Data Curation, Writing. PR: Writing, Executing the Procedure. VRMML: Conceptualization, Data Curation, Writing, Review.

## Conflict of interest

The authors have no proprietary, financial, or other personal interest of any nature or kind in any product, service, and/or company that is presented in this article.

## Funding

This research did not receive any specific grant from funding agencies in the public, commercial, or not-for-profit sectors.

## Regulatory Statement

All procedures were performed with prior informed consent from the patient.

## REFERENCES

- Muñoz Lora VRM, Del Bel Cury AA, Jabbari B, Lacković Z. Botulinum toxin Type A in Dental Medicine. *J Dent Res*. 2019;98(13):1450-7. <http://dx.doi.org/10.1177/0022034519875053>. PMID:31533008.
- Nestor MS, Arnold D, Fischer D. The mechanisms of action and use of botulinum neurotoxin type A in aesthetics: Key Clinical Postulates II. *J Cosmet Dermatol*. 2020;19(11):2785-804. <http://dx.doi.org/10.1111/jocd.13702>. PMID:32866999.
- Levy PM. The "Nefertiti lift": a new technique for specific re-contouring of the jawline. *J Cosmet Laser Ther*. 2007;9(4):249-52. <http://dx.doi.org/10.1080/14764170701545657>. PMID:18236245.
- Swift A, Green JB, Hernandez CA, Aguilera SB, Fagien S, Gold MH, et al. Tips and tricks for facial toxin injections with illustrated anatomy. *Plast Reconstr Surg*. 2022;149(2):303e-12e. <http://dx.doi.org/10.1097/PRS.00000000000008708>. PMID:35077430.
- D'Emilio R, Rosati G. Full-face treatment with onabotulinumtoxinA: results from a single-center study. *J Cosmet Dermatol*. 2020;19(4):809-16. <http://dx.doi.org/10.1111/jocd.13130>. PMID:31486568.
- Rappl T, Wurzer P, May S, Tuca AC, Cambiaso-Daniel J, Parvizi D, et al. Three-dimensional evaluation of static and dynamic effects of botulinum toxin A on glabellar frown lines. *Aesthetic Plast Surg*. 2019;43(1):206-12. <http://dx.doi.org/10.1007/s00266-018-1230-y>. PMID:30311033.
- Stekelenburg CM, Jaspers MEH, Niessen FB, Knol DL, Van Der Wal MBA, De Vet HCW, et al. In a clinimetric analysis, 3D stereophotogrammetry was found to be reliable and valid for measuring scar volume in clinical research. *J Clin Epidemiol*. 2015;68(7):782-7. <http://dx.doi.org/10.1016/j.jclinepi.2015.02.014>. PMID:25817943.
- Diaspro A, Rossini G. Thread lifting of the midface: a pilot study for quantitative evaluation. *Dermatol Ther*. 2021;34(4):e14958. PMID:33840127.
- de Almeida ART, Romiti A, Carruthers JDA. The facial platysma and its underappreciated role in lower face dynamics and contour. *Dermatol Surg*. 2017;43(8):1042-9. <http://dx.doi.org/10.1097/DSS.0000000000001135>. PMID:28394862.
- Felix Bravo BS, De Bastos JT, Da Rocha CRM, Alcalá B, Bianco S, Dos Santos FLL, et al. Definition of the mandibular angle using botulinum toxin type A: a new technique for the improvement of mandibular contour and definition. *J Clin Aesthet Dermatol*. 2019;12(11):32-4. PMID:32038755.
- Suwanchinda A, Rudolph C, Hladik C, Webb KL, Custozzo A, Muste J, et al. The layered anatomy of the jawline. *J Cosmet Dermatol*. 2018;17(4):625-31. <http://dx.doi.org/10.1111/jocd.12728>. PMID:30091282.
- Cotofana S, Schenck TL, Trevidic P, Sykes J, Massry GG, Liew S, et al. Midface: clinical anatomy and regional approaches with injectable fillers. *Plast Reconstr Surg*. 2015;136(5, Suppl):219S-34S. <http://dx.doi.org/10.1097/PRS.0000000000001837>. PMID:26441102.

13. Petchngaovilai C. Midface lifting with botulinum toxin: intradermal technique. *J Cosmet Dermatol*. 2009;8(4):312-6. <http://dx.doi.org/10.1111/j.1473-2165.2009.00467.x>. PMID:19958437.
14. Reece EM, Pessa JE, Rohrich RJ. The mandibular septum: anatomical observations of the jowls in aging - Implications for facial rejuvenation. *Plast Reconstr Surg*. 2008;121(4):1414-20. <http://dx.doi.org/10.1097/01.prs.0000302462.61624.26>. PMID:18349664.

**Victor Ricardo Manuel Munoz-Lora**  
Corresponding address  
Universidade Ibirapuera, São Paulo, Brazil  
Email: [victormunoz2512@gmail.com](mailto:victormunoz2512@gmail.com)

Date submitted: 2021 Feb 08  
Accept submission: 2022 Jun 13