



Accuracy of selective laser sintered computer guided stents versus digital light processing stents in immediate implant placement in esthetic zone: a randomized controlled trial

Precisão de *stents* sinterizados por laser seletivo guiados por computador *versus stents* de processamento de luz digital na colocação imediata de implantes em região estética: um ensaio randomizado

Mahetab HAMDI¹ , Amr Hosny EL KHADEM¹ , Ashraf Abel Moneam AMER¹ 

1 - Cairo University, Faculty of Dentistry. Cairo, Egypt.

How to cite: Hamdi M, El Khadem AH, Amer AAM. Accuracy of selective laser sintered computer guided stents versus digital light processing stents in immediate implant placement in esthetic zone: a randomized controlled trial. *Braz. Dent. Sci.* 2023;26(2):e3472. <https://doi.org/10.4322/bds.2023.e3472>

ABSTRACT

Objective: To compare accuracy of selective laser sintered computer guided stents versus digital light processing stents in immediate implant placement in esthetic zone. **Material and Methods:** The patients were selected according to the eligibility criterias. The selected patients were randomly allocated to either digital light processing stents (test group) or selective laser sintered computer guided stents (control group). Proper examination and diagnostic records were done for each patient followed by triple scan protocol with cone beam computer tomography (CBCT). Planning and construction of tooth supported computer guided surgical stent was done by either digital light processing technique for test group or selective laser sintering for control group. Twenty implants were inserted following computer guided implant placement protocol. After post-operative CBCT pre and post images were merged using blue sky bio software. Linear and angular deviations between planned implant and actual implant positions were measured. **Results:** Tests were considered statistically significant if the p- value was less than 0.05. Difference in means were calculated for the analysis of continuous variables with corresponding 95% confidence intervals. There was no statistical difference between selective laser sintering and digital light processing groups in all measured terms. **Conclusion:** Within the limitations of this study, both techniques can be used for immediate implant placement with clinically satisfactory results decreasing the positional errors associated with immediate implant placement.

KEYWORDS

Computer aided; Immediate dental implant; Stents; Surgery; Guided surgery.

RESUMO

Objetivo: Comparar a acurácia de *stents* sinterizados por laser seletivo guiados por computador *versus stents* de processamento de luz digital na colocação imediata de implantes em região estética. **Material e Métodos:** Os pacientes foram selecionados de acordo com os critérios de elegibilidade. Os pacientes selecionados foram distribuídos aleatoriamente nos seguintes grupos: *stents* de processamento de luz digital (grupo experimental) ou *stents* sinterizados por laser seletivo guiados por computador (grupo controle). Os registros dos exames adequados e diagnósticos foram realizados para cada paciente seguido por um protocolo de varredura tripla com tomografia computadorizada de feixe cônico (TCFC). O planejamento e a construção do *stent* cirúrgico guiado por computador com suporte dentário foram feitos pela técnica de processamento de luz digital para o grupo experimental ou sinterização a laser seletivo para o grupo controle. Vinte implantes foram inseridos seguindo o protocolo de colocação de implante guiado por computador. Após a TCFC pós-operatória, as imagens pré e pós foram mescladas usando o *software blue sky bio*. Foram medidos os desvios lineares e angulares entre o implante planejado e as posições reais do implante. **Resultados:** Os testes foram considerados estatisticamente

significativos se o valor de p fosse menor que 0,05. A diferença nas médias foi calculada para a análise das variáveis contínuas com intervalos de confiança de 95%. Não houve diferença estatística entre os grupos de sinterização a laser seletivo e processamento digital de luz em todas as variáveis mensuradas. **Conclusão:** Dentro das limitações deste estudo, ambas as técnicas podem ser utilizadas para colocação imediata de implantes com resultados clinicamente satisfatórios diminuindo os erros posicionais associados à colocação imediata de implantes.

PALAVRAS-CHAVE

Projeto Assistido por Computador; Implante Dentário de Carga Imediata; Estêntes; Cirurgia Assistida por Computador; Cirurgia.

INTRODUCTION

Nowadays, the demand of immediate implant placement remarkably increased [1]. It offers shorter treatment period, fewer surgical intervention and improved patient esthetics and satisfaction [1,2]. According to Slagter et al. [3] systematic review, immediate implant was accompanied by 97.1% survival for the first year.

Although such technique offers a promising solution for treatment of hopeless teeth in patient with high esthetic demands, it could not compete with the routine implant protocol. It has been associated with both linear and angular errors that can lead to serious positional complications [2,4]. Such positional errors might be due to the local anatomy of the socket after extraction, osteotomy drills might deflect from intended site of preparation due to the palatal bony slope of the socket resulting in a suboptimal implant position [5]. Accurate implant placement in immediate implant cases is very critical as it directly affects the esthetics outcome [6].

With the growing field of computer guided surgery, many researchers introduced the use of guided surgery for immediate implant placement and reported increased success rate for computer guided immediate implant placement [6,7]. Arisan et al. [8] reported a dramatically decrease in the positional errors in computer guided implants compared to the free hand one. Alzoubi et al recommended the use of computer guided stent for immediate implant for more accurate results [9].

However, also CAD CAM surgical stents have been associated with linear and angular errors [10-13]. For instance, Jung et al. [14] reported a mean deviation of 1.07 mm at the entry point, 1.6 mm at the apex and a mean of 5.3° angular deviation. Comparable results were reported by a systematic review studying the accuracy of static computer implant surgery. It

revealed a total mean error of 1.2 mm at the entry point, 1.4 mm at the apical point and deviation of 3.5° [15]. That transfer deviation is a result of accumulative errors starting from planning stage to the operative phase [15-17]. Errors can be generated from any step in the computer aided implant placement cascade.

The errors can be classified into five main categories: imaging, planning, stent support, surgical kit related factors (sleeve/drill combination) and manufacturing related errors. Regarding the imaging related errors, The used imaging modality, geometric configuration and radiographic unit parameters, metal artifacts and patient movement are all effective parameters [18-20]. Furthermore, the scanning protocol whether single, dual or triple protocol is used. Planning related errors can result from either the planning software itself or examiners errors that include Volume rendering, fiducial marker identification and visualization. Regarding stent support, Tooth supported stent can offer more stable guide with higher accuracy [21]. For surgical kit, the sleeve/drill combination properties should be well studied including the clearance between drill and sleeve, sleeve height, offset amount. Finally, whether single or multiple sleeve system is used [22]. The stent manufacturing technology may have an influence on the overall accuracy of the stent. Whether different manufacturing techniques can affect the amount of linear and angular deviation in computer guided implant especially in challenging cases as immediate implant or not, the literature addressing such issue is limited and inconclusive [23].

Selective laser sintering (SLS) is one of the most and oldest used additive prototyping techniques in dentistry. It uses a computer guided carbon dioxide laser beam to fuse a thermoplastic powder together to build up a 3 D prototype layer by layer [24]. The unscanned powder in the

previously sintered layer is left to function as a support for the next layers. SLS was reported to have high accuracy of maximum standard error 0.1-0.6 mm and capability of constructing small parts of 0.5 mm [25]. Beside that, the absence of the support material and material versatility allowed SLS to be one of the most used additive technologies in dentistry. However, the high cost of SLS and the slow process are the main disadvantages of the technique [25].

DLP is a more recent type of liquid polymerization printing. The designed 3D object is built up layer by layer by tracing the surface of photopolymer resin with ultraviolet depolarized light [26]. The whole image for the layer is displayed from a projector and harden at once decreasing the curing time. It needs support material to support the prototype during printing. The low cost and decreased process time allowed DLP technology to grow rapidly [27].

The aim of current study was to compare accuracy of selective laser sintered computer guided stents versus digital light processing stents in immediate implant placement in esthetic zone. The null hypothesis was "the manufacturing technique has no influence on the accuracy of computer immediate implant placement in esthetic zone.

SUBJECTS AND METHODS

This was a randomized clinical trial, triple blinded, two arm parallel group, with allocation ratio 1:1. The study was conducted in research clinic, Prosthodontic department, Faculty of dentistry, Cairo university, Egypt and was approved by Ethics Committee of Scientific Research at Faculty of Dentistry with registration number 17910. It was registered online at clinicaltrials.gov with identifier registration number NCT03211819.

Sample size calculation was done using R statistical package, The R Foundation for Statistical Computing. The results showed that a total sample size of 16 implants will be adequate to detect a mean difference of 1.54 mm (± 1.03) in implant position between study groups with a power of 80% and a two-sided significance level of 5%; with equal allocation to two arms (8 implants in each group).

A total of 20 implants were inserted. The patients were recruited according to the following eligibility criteria:

Inclusion criteria

- Adult patient elder than 18 years and had good oral hygiene;
- The patient had a non-restorable tooth/teeth in esthetic zone;
- The tooth is asymptomatic with no periapical lesion or fistula;
- Small radiolucency that was included within the osteotomy was an exception;
- 3 mm or more bone apical to the tooth root and a minimum of 1.5 mm interdental bone between the tooth root and the adjacent teeth;
- Intact labial bone at level comparable to adjacent teeth;
- At least 2 mm band of keratinized mucosa.

Exclusion criteria

- heavy smoking;
- any systemic condition that is considered absolute contraindication for implant;
- placement;
- pregnancy;
- in adequate inter-arch space;
- parafunctional habits as bruxism.

The patients were randomly allocated to either test or control group using a computer-generated table of random numbers.

Intervention for both groups

Preparatory phase

Dental and medical history was taken followed by careful examination for the entire oral cavity and teeth. Impressions were made and poured twice. The target tooth was waxed up to its final restorative shape with scanable wax. The target tooth in the second poured cast was trimmed.

Scanning protocol

A triple scanning protocol was followed for all participating patients. CBCT was done for each patient. Moreover, the 2 casts were optically scanned (DOF freedom HD, extra-oral scanner, United states of America).

Preparing the virtual model

Superimposition of the 3-D models

The surgical stent was designed using the implant planning software (Blue sky bio plan 4 version, United states). DICOM files from the cbct and STL files from the 2 casts scan were imported to the blue sky.

The patient CBCT image and The cast scans STL format files, were imported to the software. The superimposition function of the software was utilized to superimpose the 3-D images of the virtual casts to the CBCT reconstructed 3-D image then Virtual implant position was optimized according to both the functional and esthetic needs.

Designing the surgical stent

Hypothetically, the surgical stent may be considered as consisting of two functionally different parts. A locating or reference part, which is the stent body itself. The stent body fits on the patient's teeth, soft tissue, or bone to place the other part in an exact planned position. The second part is a sleeve hole, in which a metal sleeve fits guide the drills, and subsequently the implants, to the pre-planned depth and orientation.

The guide tube is automatically generated by the software parallel to the long axis of the planned virtual implant after determination of four parameters in the advanced panel of its guide module. The parameters are related to the surgical kit and specific for each implant system. These parameters are the outer sleeve diameter and the sleeve height, the offset and the drill stop. These parameters control the diameter and length of the guide tube location of the metal to govern the depth of drilling for guided insertion of the implant future in the same depth of the virtual one by changing the offset (Figure 1). All parameters are supplied in the company catalogue only the offset was calculated for each implant (Equation 1).

$$\left[\begin{array}{l} \text{offset distance} = \\ \text{prolongation distance} * - (\text{drill stop value} + \text{implant length}) \end{array} \right] \quad (1)$$

In the guide module, the draw outline function was selected to draw the surgical stent outline on the model with trimmed tooth and then converted into 3-D stent through function create.

The completed surgical stent design was saved in STL format to be exported to the manufacturing unit. Stents used for the first group patients were 3-D printed by Selective Laser Sintering (EOS4 Mega selective laser sintering) of polymeric powder (polyamide) (Figure 2). Stents used for the second group patients were 3-D printed by Digital Light Processing2 (Dent 2 3D printer Mogassam) of a photo reactive acrylate liquid (Figure 3). The adaptation of the manufactured stents was checked on the corresponding casts, and the metal sleeve was fitted in sleeve hole.

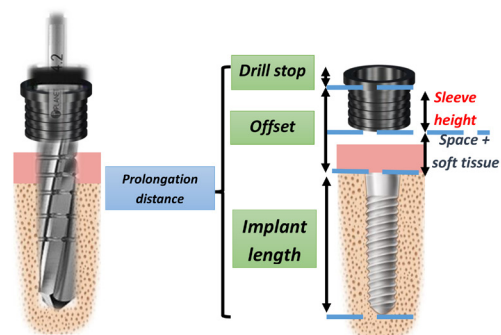


Figure 1 - Diagrammatic representation of the offset.

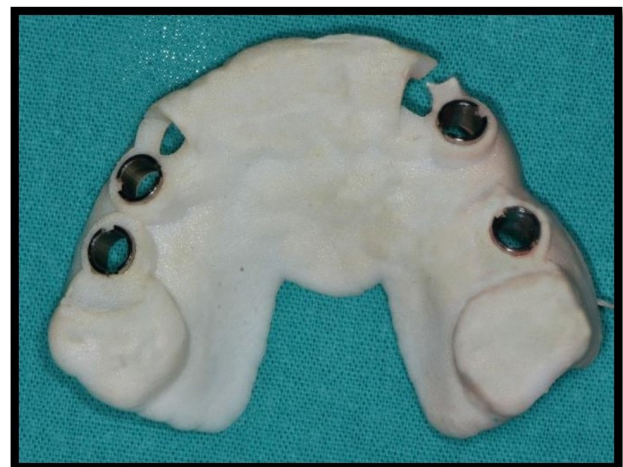

Figure 2 - Selective Laser Sintered stent.

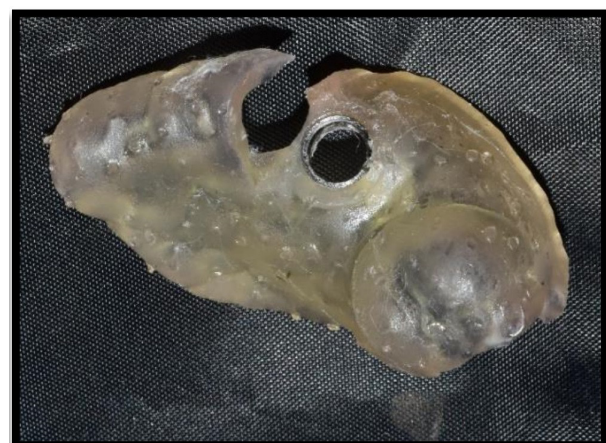

Figure 3 - Digital Light Processed stent.

*Prolongation distance is distance from drill stop to drill tip.

Surgical phase

Atraumatic extraction

The tooth was atraumatically extracted aided by twist periosteal elevator, and the integrity of the buccal bone plate was examined. After that, the stent adaptation was checked in patient mouth (Figure 4).

Drilling and implant insertion

The stent was held in its place and osteotomy was sequentially drilled by the use of Direct implant kit for computer guided surgery. Under copious irrigation of sterile saline. The implant was manually threaded through the stent until resistance was

felt, after complete implant insertion covering screw was tightened (Figure 4). Postoperative cone beam CT was made.

Outcome assessment

For outcome assessment the virtual plan was exported and superimposed to the post-operative cone beam. The accuracy of implant placement was measured in terms of both linear (both apically and coronally) and angular deviation of the actual implant from planned one by two independent operators (Figures 5 and 6). Accuracy was measured in the verification view of bluesky software in two slices one buccolingual and other mesiodistal.

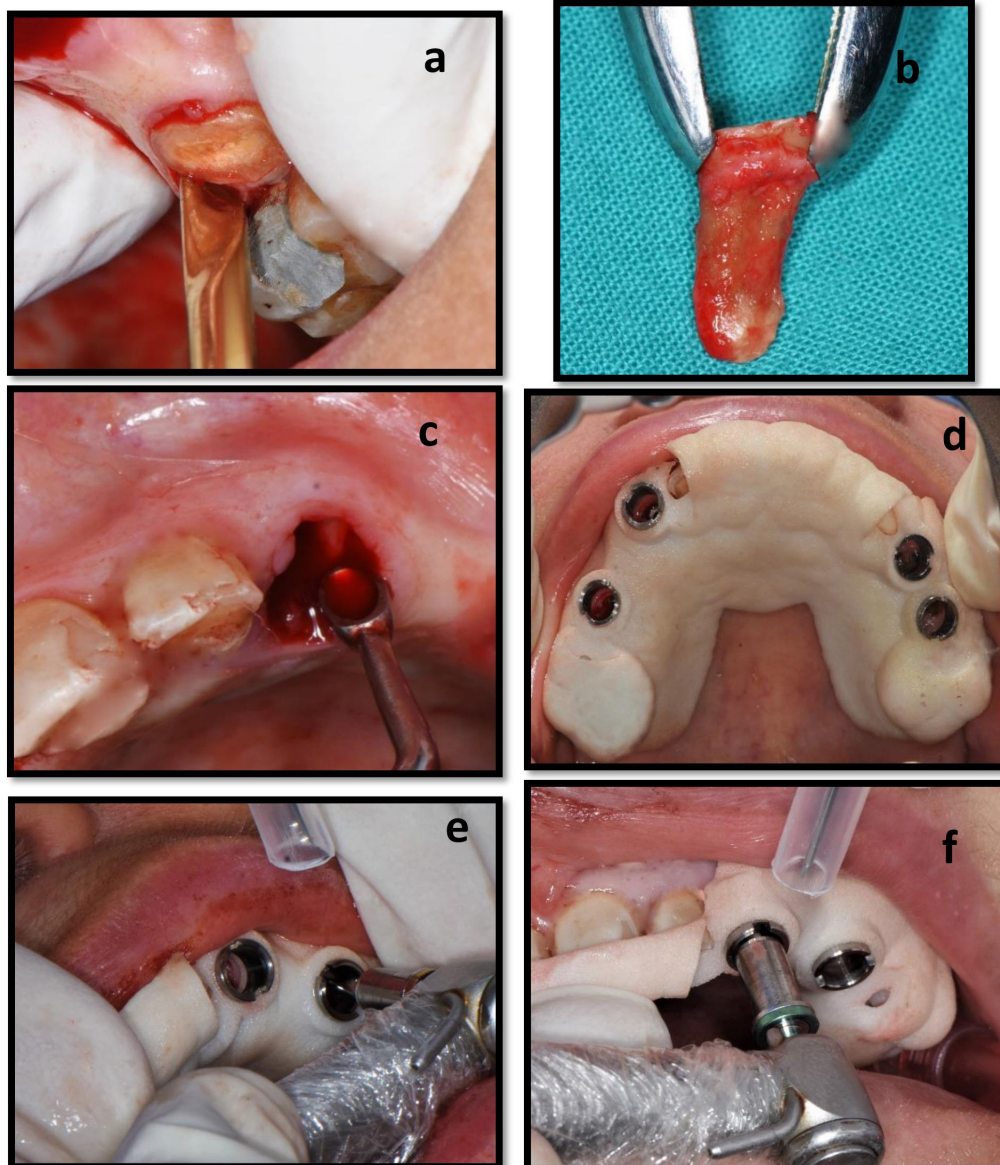


Figure 4 - Surgical procedure. **a & b**: atraumatic extraction; **c**: curettage of the socket; **d**: checking the stent fit; **e**: Osteotomy preparation through the guide.

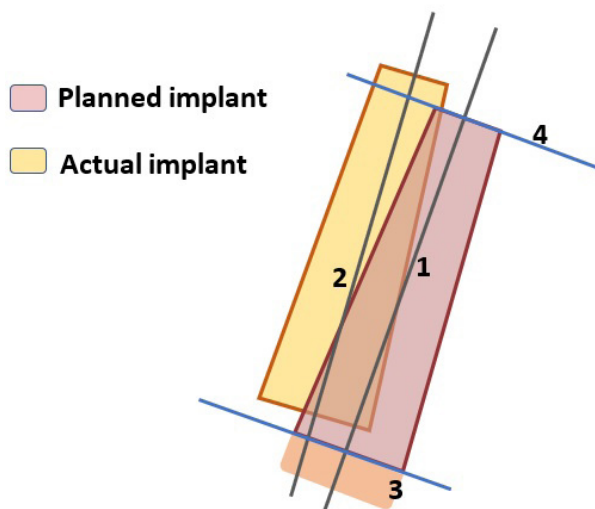


Figure 5 - Reference planes: **1)** long axis of planned implant; **2)** long axis of the actual implant; **3)** coronal reference plane; **4)** apical reference plan.

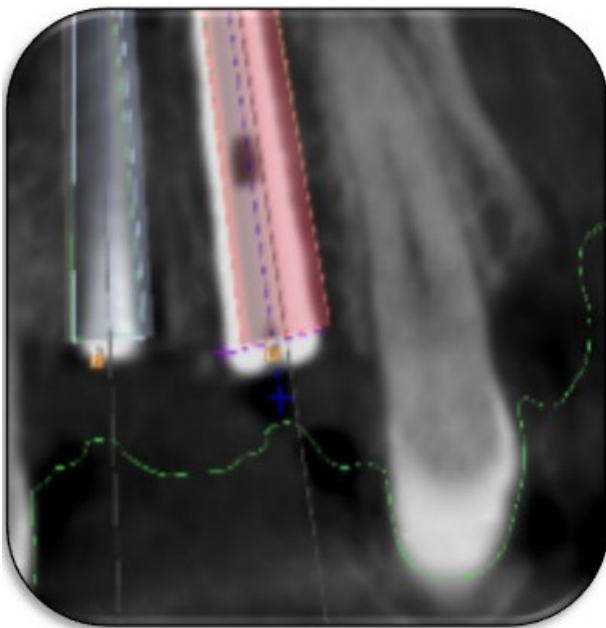


Figure 6 - Linear deviation measured in mesiodistal slice.

RESULTS

Statistical analysis was performed using Statistical Package For The Social Sciences (SPSS) software (version 20, IBM corp., U.S.A.). Inter-observer reliability was assessed using Intra-class correlation coefficient between two observers. Kolmogorov-Smirnov (K-S) was used to assess normality of data distribution. Independent sample t test was used to compare the different deviation parameters (i.e., global, angular, depth and lateral deviation) between the two studied groups. Then statistical analysis to compare the combined results of SLS and that of DLP was made. Tests were considered statistically significant if the p- value was less than 0.05. Difference in means were calculated for the analysis of continuous variables with corresponding 95% confidence intervals. The results were tabulated and statistically analysed by the help of a Professional academic statistician blinded to study groups.

Results of deviation in mesiodistal slice (Table I)

On comparing combined global linear deviation of both SLS and DLP groups the SLS group showed less global linear deviation at the implant shoulder (coronal) compared to the DLP with mean values 0.63 mm and 0.69 mm respectively. The same was found at implant apex (apical) with 0.92 mm mean deviation for the SLS and 1.26 mm for the DLP. But there was no statistical difference in both the coronal and apical linear deviation

On statistical analysis of the lateral linear deviation of the two groups, the SLS group showed less mean lateral deviation 0.29 mm for

Table I - Statistical Analysis Of Mean Difference Between SLS And DLP Groups, 95% Confidence Intervals And P-Value Groups In Mesio-Distal Slice

Measurements in Mesio-Distal Slice	Independent Sample T- Test			Interpretation	
	Mean of the differences	95% Confidence Interval	P-Value		
Coronal	Global Linear Deviation	-0.0614	-0.4693 to 0.3464	0.75	No Statistical Difference
	Lateral Linear Deviation	-0.1363	-0.3708 to 0.0983	0.2316	No Statistical Difference
	Depth Linear Deviation	0.1414	-0.4258 to 0.7087	0.5992	No Statistical Difference
Apical	Global Linear Deviation	-0.3386	-0.8628 to 0.1857	0.1863	No Statistical Difference
	Lateral Linear Deviation	-0.1716	-0.9287 to 0.5855	0.6325	No Statistical Difference
	Depth Linear Deviation	-0.0257	-0.5476 to 0.4962	0.9169	No Statistical Difference
Angular		-0.7757	-2.4453 to 0.8939	0.3338	No Statistical Difference

the coronal deviation and 0.65 mm for the apical one compared with 0.43 mm and 0.82 mm for DLP respectively without statistical difference

Regarding the depth deviation, there was not any statistical difference between both groups. The SLS group had mean depth deviation of 0.57 mm coronally and 0.58 mm apically in mesio-distal slice. While DLP showed mean depth deviation of 0.43 mm coronally and 0.61 mm apically

the SLS group showed angular deviation of 2.38° while DLP 3.14° with no statistical difference between both groups.

Results of deviation in buccolingual slice (Table II)

The SLS group showed less global linear deviation at the implant shoulder (coronal) compared to the DLP with mean values 0.54 mm and 0.96 respectively. The same was found at implant apex (apical) with 1 mm for the SLS and 1.64 mm for the DLP. But there was no statistical difference in both the coronal and apical linear deviation.

Moreover, the SLS group had less lateral deviation 0.39 mm for the coronal deviation and 0.85 mm for the apical one compared with 0.73 mm and 1.3 mm for DLP respectively with no statistical difference.

Regarding depth deviation, there was not any statistical difference between both groups. The SLS group had less depth deviation 0.31 mm coronally and 0.62 mm apically. While DLP showed more depth deviation 0.47 mm coronally and 1.24 mm apically.

For angular deviation, the SLS group showed angular deviation of 3.14° while DLP 3.3° with no statistical difference.

DISCUSSION

Accuracy of computer guided immediate implant placement

There was no single case of pure linear deviation without angular deviation. Meanwhile, apical deviations showed higher values than coronal deviations with only statistical difference between apical and coronal lateral deviations. These lead to the assumption that both apical and coronal liner deviations were dependent on angular deviation. This assumption is braced by Jung et al. [14] and Van Assche and Quirynen [28].

In literature, many studies [12,16,29-34] attributed Such deviation to nature of the guided surgery that suffers flaws of accumulative error starting from CBCT acquisition errors, superimposition, conversion of dicomes to STL file, manufacturing technique, guide design and support. Some of those studies [22,28,35,36] discussed the relation between the deviation of actual implant and both the guide adaptation and mechanical components of the guide in terms of sleeve height, clearance between osteotomy drill and sleeve, and the offset.

Cassetta et al. [35] estimated that 62.7% of the total implant positioning error was due to the properties of the sleeve/ drill combination. The same was reported by Apostolakis and Kourakis [22] who studied the interaction between implant position accuracy and each of

Table II - Statistical Analysis Of Mean Difference In Accuracy Measurements In Bucco-Lingual Slice Between SLS And DLP Groups, 95% Confidence Intervals And P-Value

Measurement in Bucco-lingual slice	Independent Sample T- Test			Interpretation	
	Mean of the differences	95% Confidence Interval	P-Value		
Coronal	Global Linear Deviation	-0.4048	-0.9306 To 0.120	0.1201	No Statistical Difference
	Lateral Linear Deviation	-0.3452	-0.8825 To 0.1921	0.1885	No Statistical Difference
	Depth Linear Deviation	-0.1564	-1.1340 To 0.8212	0.7351	No Statistical Difference
Apical	Global Linear Deviation	-0.5479	-1.3201 To 0.2244	0.1493	No Statistical Difference
	Lateral Linear Deviation	-0.4434	-1.0960 To 0.2092	0.1659	No Statistical Difference
	Depth Linear Deviation	-0.6009	-1.4650 To 0.2632	0.1569	No Statistical Difference
Angular		-0.1743	-1.6950 To 2.0436	0.8435	No Statistical Difference

the following: sleeve height, clearance between the drills and the sleeve, offset value and finally the implant length. They had concluded that implant length, sleeve clearance, and offset are proportionally related to the error in implant positioning, while the sleeve length is inversely related to the error [22]. These results highly support the assumption of deviation being primary angular followed by associated linear deviation.

The surgical kit design may be considered as an effective factor in the guided implant placement accuracy. Systems with drill guide would show higher error values since there are two clearance gaps. There is clearance between the sleeve and the drill guide, and another clearance is between the drill and the drill guide itself [35]. Furthermore, the abrasion of the sleeve itself should be taken into consideration especially if used several times [22].

Depth deviation may be slightly different. It was reported that the main causes of depth deviation in guided surgery might be the vertical setting of the guide itself in addition to accumulative errors of the guided surgery that were mentioned above [22,37-39].

SLS versus DLP

In spite the statistical analysis revealed insignificant difference between both groups (SLS and DLP) in all terms of accuracy measurements, DLP showed the higher mean values of all terms of deviation measurements.

The superiority of SLS could be attributed to the nature of manufacturing technique itself. For instance, the absence of support material that represented one of the weakness points of DLP could be considered an important reason of the superior adaptation of the SLS guides. Moreover, the small particle sizes and the minimal layer thickness of SLS were other factors [24].

On reviewing the DLP technique problems, the need for both supporting material and post curing cycle could be considered their main problem. Even after post curing cycle, the material was easily scratched that might indicate incomplete curing of the material that might be the cause of the less adaptation. That was in accordance with a previous review of literature that stated that both the rough surface finish

and need of support material were the main limitations of such technique [40].

CONCLUSIONS

Based on the results of the current study the following can be concluded:

Computer guided stents can decrease the positional errors associated with immediate implant placement.

The null hypothesis was accepted, manufacturing technique has no influence on overall accuracy of computer guided surgical stent in immediate implant placement in esthetic zone. Both techniques can be used for immediate implant placement with clinically satisfactory results.

Author's Contributions

MH: Conceptualization, methodology, software, investigation, resources, data curation, writing – original draft preparation, writing – review & editing, visualization and funding acquisition. AHEK: Conceptualization, validation, formal analysis data curation review & editing, visualization, supervision, project administration. AAMA: Conceptualization, methodology, investigation, resources, writing – original draft preparation, writing – review & editing, visualization, supervision.

Conflict of Interest

The authors have no proprietary, financial, or other personal interest of any nature or kind in any product, service, and/or company that is presented in this article.

Funding

This research did not receive any specific grant from funding agencies in the public, commercial, or not-for-profit sectors.

Regulatory Statement

This study was conducted in accordance with all the provisions of the local human subjects oversight committee guidelines and policies of: Ethics Committee of Scientific Research at Faculty of Dentistry. The approval code for this study is: 17910.

REFERENCES

1. Tonetti MS, Cortellini P, Graziani F, Cairo F, Lang NP, Abundo R, et al. Immediate versus delayed implant placement after anterior single tooth extraction: the timing randomized controlled clinical trial. *J Clin Periodontol*. 2017;44(2):215-24. <http://dx.doi.org/10.1111/jcpe.12666>. PMID:27978602.
2. Koh RU, Rudek I, Wang H-L. Immediate implant placement: positives and negatives. *Implant Dent*. 2010;19(2):98-108. <http://dx.doi.org/10.1097/ID.0b013e3181d47eaf>. PMID:20386212.
3. Slagter KW, den Hartog L, Bakker NA, Vissink A, Meijer HJ, Raghoebar GM. Immediate placement of dental implants in the esthetic zone: a systematic review and pooled analysis. *J Periodontol*. 2014;85(7):e241-50. <http://dx.doi.org/10.1902/jop.2014.130632>. PMID:24502614.
4. Ayman DM, Elkhadem AH, Elkerdawy MW. Evaluation of accuracy in computer guided versus free hand immediate implant placement in fresh extraction sockets: a randomized controlled clinical trial. *Indian J Public Heal Res Dev*. 2022;13(1):131-42.
5. Alzoubi F, Massoomi N, Nattestad A. Accuracy assessment of immediate and delayed implant placements using CAD/CAM surgical guides. *J Oral Implantol*. 2016;42(5):391-8. <http://dx.doi.org/10.1563/aaid-joi-D-16-00017>. PMID:27266995.
6. Kotb A, Elkerdawy M, Elfar M. Esthetic outcome of computer-guided versus free-hand immediate implant placement in fresh extraction sockets in esthetic zone, a randomized clinical trial. *Indian J Public Heal Res Dev*. 2020;11(12):140-7.
7. Edelmann AR, Hosseini B, Byrd WC, Preisser JS, Tyndall DA, Nguyen T, et al. Exploring effectiveness of computer-aided planning in implant positioning for a single immediate implant placement. *J Oral Implantol*. 2016;42(3):233-9. <http://dx.doi.org/10.1563/AAID-JOI-D-15-00056>. PMID:26652644.
8. Arisan V, Karabuda CZ, Mumcu E, Özdemir T. Implant positioning errors in freehand and computer-aided placement methods: a single-blind clinical comparative study. *Int J Oral Maxillofac Implants*. 2013;28(1):190-204. <http://dx.doi.org/10.11607/jomi.2691>. PMID:23377066.
9. Alzoubi F, Massoomi N, Nattestad A. Accuracy assessment of immediate and delayed implant placements using CAD/CAM surgical guides. *J Oral Implantol*. 2016;42(5):391-8. <http://dx.doi.org/10.1563/aaid-joi-D-16-00017>. PMID:27266995.
10. Schneider D, Marquardt P, Zwahlen M, Jung RE. A systematic review on the accuracy and the clinical outcome of computer-guided template-based implant dentistry. *Clin Oral Implants Res*. 2009;20(Suppl. 4):73-86. <http://dx.doi.org/10.1111/j.1600-0501.2009.01788.x>. PMID:19663953.
11. Nickenig H-J, Eitner S, Rothamel D, Wichmann M, Zöller JE. Possibilities and limitations of implant placement by virtual planning data and surgical guide templates. *Int J Comput Dent*. 2012;15(1):9-21. PMID:22930944.
12. Cassetta M, Stefanelli LV, Giansanti M, Di Mambro A, Calasso S. Depth deviation and occurrence of early surgical complications or unexpected events using a single stereolithographic surgical guide. *Int J Oral Maxillofac Surg*. 2011;40(12):1377-87. <http://dx.doi.org/10.1016/j.ijom.2011.09.009>. PMID:22001378.
13. D'haese J, Van De Velde T, Komiyama A, Hultin M, De Bruyn H. Accuracy and complications using computer-designed stereolithographic surgical guides for oral rehabilitation by means of dental implants: a review of the literature. *Clin Implant Dent Relat Res*. 2012;14(3):321-35. <http://dx.doi.org/10.1111/j.1708-8208.2010.00275.x>. PMID:20491822.
14. Jung RE, Schneider D, Ganeles J, Wismeijer D, Zwahlen M, Hämmerle CH, et al. Computer technology applications in surgical implant dentistry: a systematic review. *Intern J Maxillofac Implants*. 2009;24(Suppl):92-109. PMID:19885437.
15. Tahmaseb A, Wu V, Wismeijer D, Coucke W, Evans C. The accuracy of static computer-aided implant surgery: a systematic review and meta-analysis. *Clin Oral Implants Res*. 2018;29(29, Suppl 16):416-35. PMID:30328191.
16. D'haese J, Ackhurst J, Wismeijer D, De Bruyn H, Tahmaseb A. Current state of the art of computer-guided implant surgery. *Periodontol 2000*. 2017;73(1):121-33. <http://dx.doi.org/10.1111/prd.12175>. PMID:28000275.
17. Naziri E, Schramm A, Wilde F. Accuracy of computer-assisted implant placement with insertion templates. *GMS Interdiscip Plast Reconstr Surg DGPW*. 2016;5:15. PMID:27274440.
18. Loubele M, Maes F, Jacobs R, van Steenberghe D, White SC, Suetens P. Comparative study of image quality for MSCT and CBCT scanners for dentomaxillofacial radiology applications. *Radiat Prot Dosimetry*. 2008;129(1-3):222-6. <http://dx.doi.org/10.1093/rpd/ncn154>. PMID:18583372.
19. Choi Y, Mai HN, Mai HY, Ha JH, Li LJ, Lee DH. The effects of distribution of image matched fiducial markers on accuracy of computer-guided implant surgery. *J Prosthodont*. 2020;29(5):409-14. <http://dx.doi.org/10.1111/jopr.13171>. PMID:32237001.
20. Tatakis DN, Chien HH, Parashis AO. Guided implant surgery risks and their prevention. *Periodontol 2000*. 2019;81(1):194-208. <http://dx.doi.org/10.1111/prd.12292>. PMID:31407433.
21. El Kholy K, Lazarin R, Janner SFM, Faerber K, Buser R, Buser D. Influence of surgical guide support and implant site location on accuracy of static Computer-Assisted Implant Surgery. *Clin Oral Implants Res*. 2019;30(11):1067-75. <http://dx.doi.org/10.1111/clr.13520>. PMID:31381178.
22. Apostolakis D, Kourakis G. CAD/CAM implant surgical guides: maximum errors in implant positioning attributable to the properties of the metal sleeve/osteotomy drill combination. *Int J Implant Dent*. 2018;4(1):34. <http://dx.doi.org/10.1186/s40729-018-0146-2>. PMID:30411253.
23. Keßler A, Dosch M, Reymus M, Folwaczny M. Influence of 3D-printing method, resin material, and sterilization on the accuracy of virtually designed surgical implant guides. *J Prosthet Dent*. 2021;128(2):196-204. PMID:33573833.
24. Di Giacomo GA, da Silva JV, da Silva AM, Paschoal GH, Cury PR, Szarf G. Accuracy and complications of computer-designed selective laser sintering surgical guides for flapless dental implant placement and immediate definitive prosthesis installation. *J Periodontol*. 2012;83(4):410-9. <http://dx.doi.org/10.1902/jop.2011.110115>. PMID:21819249.
25. Zaharia C, Gabor A-G, Gavrilovici A, Stan AT, Idorasi L, Sinescu C, et al. Digital dentistry: 3D printing applications. *J Interdiscip Med*. 2017;2(1):50-3. <http://dx.doi.org/10.1515/jim-2017-0032>.
26. Nulty A. 3D printing part 1 : a history and literature review of 3D printing technologies used. *Indent (Engl)*. 2021;(May):1-17.
27. Schweiger J, Edelhoff D, Güth JF. 3d printing in digital prosthetic dentistry: an overview of recent developments in additive manufacturing. *J Clin Med*. 2021;10(9):2010. <http://dx.doi.org/10.3390/jcm10092010>. PMID:34067212.
28. Van Assche N, Quirynen M. Tolerance within a surgical guide. *Clin Oral Implants Res*. 2010;21(4):455-8. <http://dx.doi.org/10.1111/j.1600-0501.2009.01836.x>. PMID:20074247.
29. Vercruyssen M, Coucke W, Naert I, Jacobs R, Teughels W, Quirynen M. Depth and lateral deviations in guided implant surgery : an RCT comparing guided surgery with mental navigation or the use of a pilot-drill template. *Clin Oral Implants Res*. 2015;26(11):1315-20. PMID:25179585.
30. Tahmaseb A, Wismeijer D, Coucke W, Derksen W. Computer technology applications in surgical implant dentistry: a systematic review. *Int J Oral Maxillofac Implants*. 2014;29(Suppl):25-42. <http://dx.doi.org/10.11607/jomi.2014suppl.g1.2>. PMID:24660188.

31. Bilhan H, Arat S, Mumcu E, Geckili O, Sakar O. Precision of implant placement with stereolithographic templates: a pilot in vitro study. *J Oral Implantol.* 2012;38(5):569-74. <http://dx.doi.org/10.1563/AAID-JOI-D-10-00109>. PMID:21126171.
32. Almeida E, Pellizzer EPE, Goiatto MC, Margonar R, Rocha EP, Freitas AC, et al. Computer-guided surgery in implantology: review of basic concepts. *J Craniofac Surg.* 2010;21(6):1917-21. <http://dx.doi.org/10.1097/SCS.0b013e3181f4b1a0>. PMID:21119455.
33. Behneke A, Burwinkel M, Behneke N. Factors influencing transfer accuracy of cone beam CT-derived template-based implant placement. *Clin Oral Implants Res.* 2012;23(4):416-23. <http://dx.doi.org/10.1111/j.1600-0501.2011.02337.x>. PMID:22092586.
34. Schicho K, Figl M, Seemann R, Ewers R, Lambrecht JT, Wagner A, et al. Accuracy of treatment planning based on stereolithography in computer assisted surgery. *Med Phys.* 2006;33(9):3408-17. <http://dx.doi.org/10.1118/1.2242014>. PMID:17022237.
35. Cassetta M, Di Mambro A, Di Giorgio G, Stefanelli LV, Barbato E. The influence of the tolerance between mechanical components on the accuracy of implants inserted with a stereolithographic surgical guide: a retrospective clinical study. *Clin Implant Dent Relat Res.* 2015;17(3):580-8. <http://dx.doi.org/10.1111/cid.12120>. PMID:23879723.
36. Schneider D, Schober F, Grohmann P, Hammerle CHF, Jung RE. In-vitro evaluation of the tolerance of surgical instruments in templates for computer-assisted guided implantology produced by 3-D printing. *Clin Oral Implants Res.* 2015;26(3):320-5. <http://dx.doi.org/10.1111/clr.12327>. PMID:24438229.
37. Vercruyssen M, van de Wiele G, Teughels W, Naert I, Jacobs R, Quirynen M. Implant- and patient-centred outcomes of guided surgery, a 1-year follow-up: an RCT comparing guided surgery with conventional implant placement. *J Clin Periodontol.* 2014;41(12):1154-60. <http://dx.doi.org/10.1111/jcpe.12305>. PMID:25197015.
38. Vercruyssen M, Jacobs R, Van Assche N, van Steenberghe D. The use of CT scan based planning for oral rehabilitation by means of implants and its transfer to the surgical field: a critical review on accuracy. *J Oral Rehabil.* 2008;35(6):454-74. <http://dx.doi.org/10.1111/j.1365-2842.2007.01816.x>. PMID:18429973.
39. Vercruyssen M, van de Wiele G, Coucke W, Naert I, Jacobs R, Quirynen M. Implant and patient-centered outcome of guided surgery, a 1-year follow-up: an rct comparing guided surgery with conventional implant placement. *J Clin Periodontol.* 2014;41(12):1154-60. <http://dx.doi.org/10.1111/jcpe.12305>. PMID:25197015.
40. Winder J, Bibb R. Medical rapid prototyping technologies: state of the art and current limitations for application in oral and maxillofacial surgery. *J Oral Maxillofac Surg.* 2005;63(7):1006-15. <http://dx.doi.org/10.1016/j.joms.2005.03.016>. PMID:16003630.

Mahetab Hamdi
(Corresponding address)

Cairo University, Faculty of Dentistry, Cairo, Egypt.
Email: mahetab.hamdi@dentistry.cu.edu.eg

Date submitted: 2022 Mar 31
Accept submission: 2022 Oct 04