

Estrogen deficiency influences SEC23A gene expression in the odontogenic region of incisors – a murine model study

A deficiência de estrogênio influencia a expressão gênica de SEC23A na região odontogênica de incisivos – um estudo em modelo murino

Clara Costa do NASCIMENTO¹ , Marcus Augusto SILVEIRA¹ , Millena Cristina de PAULA¹ , Martinelle Ferreira da Rocha TARANTO¹ , Agnes SCHRÖDER² , Christian KIRSCHNECK² , Paulo NELSON-FILHO³ , César Penazzo LEPRI⁴ , Flares BARATTO-FILHO^{5,6} , Erika Calvano KÜCHLER^{4,5} , Isabela Ribeiro MADALENA^{1,4,6} 

1 - Centro Universitário Presidente Tancredo de Almeida Neves, Faculdade de Odontologia. São João del Rei, MG, Brazil.

2 - University of Regensburg, Department of Orthodontics. Regensburg, Germany.

3 - Universidade de São Paulo, Faculdade de Odontologia de Ribeirão Preto, Departamento de Clínica Infantil. Ribeirão Preto, SP, Brazil.

4 - Universidade de Uberaba, Departamento de Biomateriais. Uberaba, MG, Brazil.

5 - Universidade Tuiuti do Paraná, Faculdade de Odontologia. Curitiba, PR, Brazil.

6 - Universidade da Região de Joinville, Departamento de Odontologia. Joinville, SC, Brazil.

How to cite: Nascimento CC, Silveira MA, Paula MC, Taranto MFR, Schröder A, Kirschneck C, et al. Estrogen deficiency influences SEC23A gene expression in the odontogenic region of incisors – a murine model study. *Braz Dent Sci.* 2024;27(1):e3827. <https://doi.org/10.4322/bds.2024.e3827>

ABSTRACT

Recent scientific evidence suggests a close relationship between estrogen deficiency and vitamin D- related genes. Estrogen and vitamin D were involved with alterations in odontogenesis and tooth eruption process. **Objective:** The aim of the present study was to evaluate the influence of estrogen deficiency on the expression of genes related to the activation and degradation of vitamin D in the odontogenic region of incisors in a murine model. **Material and Methods:** This is an experimental clinical study that used female Wistar Hannover rats. The animals were randomly divided into two groups according to the intervention received: Hypoestrogenism Group – animals submitted to estrogen deficiency by ovariectomy surgery and Control Group – animals submitted to sham surgery. Surgical intervention was performed in the prepubertal period; the animals were followed throughout the pubertal period. After euthanasia, the hemimandibles were removed to evaluate the mRNA expression of the vitamin D-related genes AMDHD1, CYP24A1, NADSYN1 and SEC23A in the odontogenic region of incisors through real time PCR. Student's t test was used to compare means. Kruskal-Wallis test and Dunn's posttest were also used. The level of significance was 5%. **Results:** SEC23A was overexpressed in the estrogen deficiency condition in the odontogenic region ($p=0.021$). **Conclusion:** Estrogen deficiency may influence the expression of the SEC23A gene involved in the activation and degradation of vitamin D in the odontogenic region of incisors in a murine model.

KEYWORDS

Estrogen; 25-hydroxyvitamin D3; Gene expression; Odontogenesis; Vitamin D.

RESUMO

Evidências científicas recentes sugerem uma estreita relação entre a deficiência de estrogênio e os genes relacionados à vitamina D. O estrogênio e a vitamina D estão envolvidos com alterações na odontogênese e no processo de erupção dentária. **Objetivo:** O objetivo do presente estudo foi avaliar a influência da deficiência de estrogênio na expressão de genes relacionados à ativação e degradação da vitamina D na região odontogênica de incisivos em modelo murino. **Material e Métodos:** Trata-se de um estudo clínico experimental que utilizou ratas Wistar Hannover fêmeas. Os animais foram divididos aleatoriamente em dois grupos de acordo com a intervenção recebida: Grupo Hypoestrogenismo – animais submetidos à deficiência de estrogênio pela cirurgia de ovariectomia e Grupo Controle – animais submetidos à cirurgia simulada. A intervenção cirúrgica foi realizada no período pré-púbere; os animais foram acompanhados durante todo o período puberal. Após a eutanásia, as hemimandíbulas foram removidas para avaliar a expressão de mRNA dos genes AMDHD1, CYP24A1, NADSYN1 e SEC23A, relacionados à vitamina D, na região odontogênica de incisivos por meio de PCR em tempo real. O teste t de Student foi utilizado para comparar as médias. Também foram utilizados o teste de Kruskal-Wallis e o pós-teste de Dunn. O nível de significância foi de 5%. **Resultados:** SEC23A foi superexpresso na condição de deficiência de estrogênio na região odontogênica ($p=0,021$). **Conclusão:** A deficiência de estrogênio pode influenciar a expressão do gene SEC23A envolvido na ativação e degradação da vitamina D na região odontogênica de incisivos em modelo murino.

PALAVRAS-CHAVE

Estrógeno; 25-hidroxi-vitamina D3; Expressão gênica; Odontogênese; Vitamina D.

INTRODUCTION

Estrogen is a steroid hormone present and active throughout an individual's life [1]. Although it is mainly responsible for female characteristics, it is also important in the neuroendocrine, vascular, skeletal and immune systems of both sexes and dental development/tooth eruption [2-4]. Imbalances in serum estrogen levels can cause significant changes in body homeostasis. Growing scientific evidence indicates that imbalances in estrogen levels compromise the gene expression of its main intracellular receptors, *ESR1* and *ESR2*, and consequently, the physiological development of several structures, in special, involved in craniofacial development [3,5-7].

Vitamin D is an important component in the biosynthesis of estrogen in the female and male body [8]. Vitamin D represents a group of fat-soluble steroid hormones obtained mainly through exposure of the skin to UVB irradiation by sunlight [9]. In addition to the biological effects of vitamin D being mediated by binding to its intracellular receptor, the vitamin D receptor, other important genes should also be cited. The amidohydrolase domain containing 1 (*AMDHD1*), the cytochrome P450 family 24 subfamily A member 1 (*CYP24A1*), the NAD synthetase 1 (*NADSYN1*) and the Sec23 homolog A (*SEC23A*) are related to the synthesis, activation and degradation of vitamin D [9]. Vitamin D deficiency, in turn, is significant to bone homeostasis [9], host immune response [10], the development of the stomatognathic system and teeth [8,11] and risk of the main oral diseases [12,13]. Estrogen have a close relationship with Vitamin D [14]. When estrogen is deficient, low levels of vitamin D can also be observed [15].

Odontogenesis and tooth eruption process are strongly influenced by several local, systemic, environmental, genetic, and epigenetic factors [2-4,7,16]. There is some scientific evidence coming from studies in animal models showing that estrogen receptors are expressed in cells in the odontogenic region of teeth with continuous growth (incisors) [2-4]. There is also evidence demonstrating that vitamin D and its receptor are involved in tooth development [17]. Our hypothesis is that estrogen deficiency may alter the expression of vitamin D related genes. Thus, the aim of the present study was to evaluate the influence of estrogen deficiency on the expression of genes related to the activation

and degradation of vitamin D in the odontogenic region of incisors in a murine model.

MATERIAL AND METHODS

Ethical aspects

This study was submitted to the Ethics Committee on the Use of Animals of the School of Dentistry of Ribeirão Preto – University of São Paulo FORP/USP and was approved (#2018.1.40.58.3). This research was performed and reported according to the ARRIVE guidelines [18].

Experimental design

This is an *in vivo* experimental study. Specimens from a previous study by Madalena et al. [3], were used to analyze the mRNA expression of genes related to the activation and degradation of vitamin D in the odontogenic region of teeth in continuous growth. Estrogen deficiency was caused by ovariectomy surgery (Experimental group) (n=8), and the control group underwent fictitious surgery (Control group) (n=9). The animals underwent intervention in the prepubertal period and were euthanized after the pubertal period was completed. After euthanasia, the hemimandibles were removed and sectioned in the region of the condyle, coronoid process, and ramus of the mandible in order to isolate the odontogenic region of the lower incisor. The section of the hemimandible was performed with a 7011 double-sided diamond disc (KG Sorensen, Cotia, BR) with a thickness of 0.18 mm [2-4]. The mRNA samples from the odontogenic region were submitted to quantification of the gene expression of *AMDHD1*, *CYP24A1*, *NADSYN1* and *SEC23A*. Figure 1 shows the chronology of procedures carried out in this study.

Sampling of animals

Seventeen 21-day-old female Wistar rats were obtained from the animal facility of Ribeirão Preto, University of São Paulo, Brazil, were stored in the Bioterium II of the FORP/USP and housed in groups of two or three with circadian conditions of 12 hours, constant temperature and humidity (21 ± 1 °C and 55 to 75%, respectively) and *ad libitum* access to water and a standard diet for rodents (Labina Purina®/Agribbrands do Brasil LTDA, Paulínia, São Paulo, Brazil). The animals were monitored throughout the pubertal period and were euthanized after 56 days of life [2-4].

Estrogen deficiency model

Estrogen deficiency was caused by ovariectomy surgery (Experimental group), and the control group underwent fictitious surgery (Control group). Briefly, when the animals were 25 days old, they were anesthetized by intraperitoneal injection of 10% ketamine hydrochloride (55 mg/kg of gross body weight) and 2% xylazine hydrochloride (10 mg/kg of gross body weight). In the experimental group, the ovaries were removed bilaterally; while in the control group, a fictitious surgery was performed without removing or damaging the ovaries of the animals [2-4]. The success of the ovariectomy was confirmed by the gradual increase in the weight of the animals and uterine atrophy [2-4]. After the surgical procedure, antibiotic, anti-inflammatory and analgesic medication was administered. The drugs used were Benzylpenicillin Benzathine (Pentabiotic®) at a dosage of 24,000UI/kg; Flunixin (Aplonal® 1%) at a dosage of 1mg/kg, both intramuscularly, and Tramadol (Cronidor® 2%), at a dosage of 1mg/kg, subcutaneously. Tramadol is also administered again 24 hours after the surgical procedure [2-4].

Euthanasia and preparation of specimens

Euthanasia was performed following the guidelines of the National Council for the Control of Animal Experimentation – CONCEA, through anesthetic overdose with Ketamine Hydrochloride (300mg/kg of weight) and Xylazine Hydrochloride (30mg/kg of weight) associated with decapitation [2-4].

Evaluation of the gene expression of AMDHD1, CYP24A1, NADSYN1 and SEC23A in the odontogenic region - RT-qPCR

To quantify the gene expression of AMDHD1, CYP24A1, NADSYN1 and SEC23A differentially expressed between experimental and control groups, specimens were kept in RNAlater (Life Technologies Corporation – Carlsbad®, Canada, USA) and frozen at -80 °C until processing day. The mirVana™ miRNA Isolation kit (Thermo Fischer Scientific, Carlsbad, USA) was used to extract total RNA. Complementary DNA (cDNA) was synthesized by reverse-transcription with a High Capacity Kit (Applied Biosystems, Foster City, CA, USA). RT-qPCR was carried out on Mastercycler® ep realplex-S thermocycler (Eppendorf AG, Hamburg, Germany) for AMDHD1, CYP24A1, NADSYN and SEC23A. PPIB was used as endogenous controls. The relative levels of mRNA expression were determined as previously described [19]. All procedures were performed following the respective manufacturer's instructions and according to established protocols. Primers are described in the Table I.

Statistical analysis

Data were statistically analyzed using the GraphPad Prism 7.04 software (GraphPad Software®, La Jolla, USA), considering a significance level of 5% (type I error). The gene expression of AMDHD1, CYP24A, NADSYN1 and SEC23A is demonstrated by means and standard deviation (SD). Student's t test was used to compare means. The Kruskal-Wallis test and Dunn's post-test were also performed.

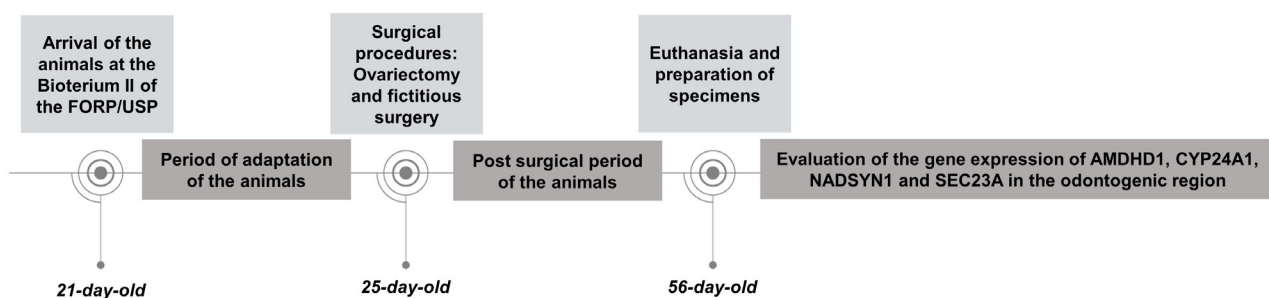


Figure 1 - Experimental design - chronology of procedures performed on animals.

Table I - Primers used for real-time quantitative polymerase chain reaction (RT-qPCR)

Gene symbol	5'-forward primer-3'	5'-reverse primer-3'
AMDHD1	GCCTCTGCCACTTACTGTG	GGCAGGTGGTGACTGATGATG
CYP24A1	GGCGGAAGACCTGAGGAATATG	AGCGTATTCACCCAGAACCG
NADSYN	TCCTTGCCCTACCTGTTTGCTC	GGTTGATGTCCGCACTGGAG
SEC23A	GGATGGTGGTTGGAGATGAGC	AGCAGCTCGATTAGCCAGTG

RESULTS

The relative gene expression of AMDHD1, CYP24A1, NADSYN1 and SEC23A in the odontogenic region in estrogen-deficient animals (experimental group) and control animals (control group) are shown in Figure 2. SEC23A was overexpressed in estrogen deficiency condition ($p=0.021$). AMDHD1, CYP24A1 and NADSYN1 did not demonstrated statistical difference between groups ($p=0.47$, $p=0.21$, and $p=0.95$, respectively)

DISCUSSION

Estrogen is a crucial steroid hormone for both female and male bodies [1]. Scientific evidence demonstrates that imbalances in serum estrogen levels influence bone resorption, dyslipidemia, glucose tolerance [20-22] and even vitamin D absorption and metabolism [15]. Therefore, in the present study we used a murine model to explore the role of estrogen deficiency on the expression of the genes AMDHD1, CYP24A1, NADSYN1 and SEC23A in the odontogenic region.

Vitamin D represents a group of fat-soluble steroid hormones obtained through primary exposure of the skin to UVB irradiation by sunlight [9]. The 7-dehydrocholesterol present in the skin is converted into pre-vitamin D₃ [9,23], in the liver, it is converted into 25-hydroxyvitamin D₃ (25(OH)D₃), the best serum indicator of vitamin D status. In the kidney, 25(OH)D₃ undergoes hydroxylation and becomes 1,25-dihydroxy vitamin D (1,25(OH)₂D₃), the biologically active form that acts on VDR [23]. 80% to 90% of serum levels of vitamin D are synthesized endogenously under UVB irradiation, the remainder, 10% to

20%, come from the diet, the main dietary sources being cholecalciferol (D₃) and ergosterol (D₂). Estrogen deficiency and vitamin D deficiency share several adverse health outcomes, including bone resorption itself, mood disorders, increased risk of cardiovascular disease and cancers [24-28] affect growth and development [2-4,29-31].

The knowledge physiology and phenotypic changes directly influence health promotion, disease prevention, predisposition or protection to diseases and drug response [32]. It is important to clarify gaps that still exist in relation to odontogenesis and tooth eruption process, which are important to the harmonious development of the stomatognathic system. Odontogenesis begins approximately in the eighth week of gestation and lasts, on mean, until the child's full development, around 18 years of age. This reminds us that, although there is an individual chronology for each tooth, odontogenesis occurs synchronously with several important episodes in child growth and development [33,34]. Concomitant to specific periods of odontogenesis, tooth eruption is also established.

Estrogen deficiency as well as vitamin D deficiency have already been described as influencing odontogenesis and tooth eruption. Based on a previous study by Madalena et al. [3] the gene expression of the main estrogen receptors in cells of the odontogenic region of teeth in continuous growth was observed. Thus, in the present study we investigated the influence of estrogen deficiency on the expression of genes related to the activation and degradation of vitamin D in the odontogenic region of continuously growing teeth in a murine model in this same sample. Our results support that

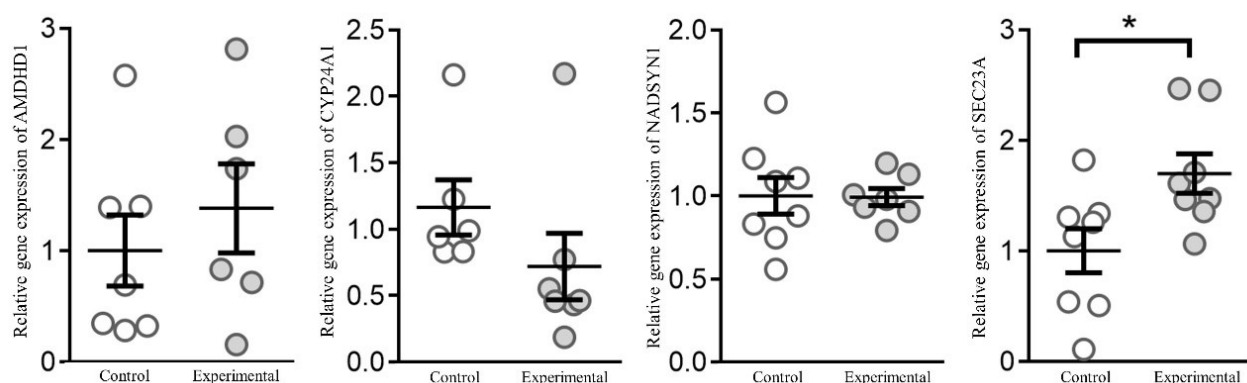


Figure 2 - Relative gene expression (mRNA) of AMDHD1, CYP24A1, NADSYN1 and SEC23A in the odontogenic region of animals submitted to estrogen deficiency compared with control animals. AMDHD1, CYP24A1 and NADSYN1 did not demonstrated statistical difference between groups ($p=0.47$, $p=0.21$, and $p=0.95$, respectively). SEC23A was overexpressed in estrogen deficiency condition ($p=0.021$). * Indicates a statistical significance difference ($p<0.05$).

in estrogen deficiency animals there was an overexpression of SEC23A in the odontogenic region of teeth in continuous growth. It is important to emphasize that in the original study from Madalena et al. [3] a delay in the rate of tooth eruption in estrogen-deficient animals.

It is therefore assumed that estrogen deficiency could also cause occasional overexpression of SEC23A since this gene is also related to collagen alterations. Mutations in SEC23A and AMDHD1 have been reported to cause craniolenticulo-sutural dysplasia, an anomaly characterized by craniofacial and skeletal malformation due to defective collagen secretion [35]. It is suggested that there is a gross dilation of the endoplasmic reticulum in fibroblasts from individuals with such dysplasia [36]. SEC23A is an essential component of vesicles that transport secretory proteins from the endoplasmic reticulum, could be overexpressed. In contrast, although there was an overexpression of AMDHD1 in estrogen deficiency, our results did not demonstrate a statistically significant difference between the groups. AMDHD1 gene overexpression is suggested to actively participate in orthodontic tooth movement, performed mainly by the action of the periodontal ligament and bone remodeling [37]. Thus, it is suggested that other studies be carried out to complement the evidence in a larger sample.

CYP24A1 catalyzes the conversion of 25-hydroxyvitamin D₃ (25(OH)D₃) and 1,25-dihydroxyvitamin D₃ (1,25(OH)₂D₃) into 24-hydroxylated products, which constitute the degradation of the vitamin D molecule [38]. Although our results do not show a statistically significant difference between the experimental and control groups, the experimental group showed a decreased expression of CYP24A1, suggesting a decrease in vitamin D synthesis, transport, and degradation in the odontogenic region of continuously growing teeth. Thus, based on evidence from clinical studies that demonstrate changes in development and tooth eruption in vitamin D deficiency and studies that demonstrate a decrease in vitamin D in estrogen deficiency, further studies are suggested to complement the evidence.

Finally, we also found no statistically significant difference in NADSYN1 gene expression.

The NADSYN1 gene encodes nicotinamide adenine dinucleotide synthetase 1, which is one of the glutamine-dependent enzymes involved in cholesterol synthesis and favors the production of nicotinamide adenine dinucleotide (NAD⁺), the main coenzyme required for energy production and lipid synthesis. Genetic polymorphisms in NADSYN1 have been described as contributing to dyslipidemia and overweight regardless of 25-hydroxyvitamin D levels [39]. In conclusion, our results contribute to evidence that seeks to clarify physiological aspects of the role of estrogen and vitamin D in the craniofacial complex.

CONCLUSION

Estrogen deficiency can influence the expression of the SEC23A gene involved in the activation and degradation of vitamin D in the odontogenic region of incisor teeth in continuous growth in a murine model.

Acknowledgements

We also thank to São Paulo Research Foundation - FAPESP and the Coordenação de Aperfeiçoamento de Pessoal de Nível Superior – CAPES/Brasil.

Author's Contributions

CCN, MAS, MCP, MFRT: Writing – Original Draft Preparation. AS, CK, CPL: Writing – Review & Editing. PNF: Conceptualization. FBF: Conceptualization, Methodology. ECK: Conceptualization, Methodology, Funding Acquisition. IRM: Methodology, Investigation, Funding Acquisition.

Conflict of Interest

The authors declare that they have no conflict of interest.

Funding

This research was funded by the São Paulo Research Foundation - FAPESP (process #2015/06866-5 and #2016/08149-1) and Coordenação de Aperfeiçoamento de Pessoal de Nível Superior (CAPES-Brasil) – PDPG-POSDOC/Bolsa - CAPES nº 88887.755620/2022-00.

Regulatory Statement

This study was conducted in accordance with all the provisions of the local human subjects oversight committee guidelines and policies of: The Ethical Committee in Animal Experimentation from the School of Dentistry of Ribeirão Preto, University of São Paulo, Brazil. The approval code for this study is: 2018.40.58.3.

REFERENCES

- Patel S, Homaei A, Raju AB, Meher BR. Estrogen: the necessary evil for human health, and ways to tame it. *Biomed Pharmacother*. 2018;102:403-11. <http://dx.doi.org/10.1016/j.biopha.2018.03.078>. PMID:29573619.
- Madalena IR, Judachesci CS, Küchler EC, Nelson-Filho P, Ramazzotto LA, Baratto-Filho F, et al. The impact of hypoestrogenism and occlusal function on MMP1, MMP8 and MMP13 expression in the odontogenic region in rats. *RSDJournal*. 2021;10(5):e47810515311. <http://dx.doi.org/10.33448/rsd-v10i5.15311>.
- Madalena IR, Marañón-Vásquez GA, Omori MA, Sousa ET, Silveira HA, León JE, et al. Evaluation of tooth eruption rate of incisor teeth in rats with estrogen deficiency. *Clin Oral Investig*. 2022;27(1):345-52. <http://dx.doi.org/10.1007/s00784-022-04738-w>. PMID:36260168.
- Anjos ID, Nogueira VO, Taranto MFR, Ramazzotto LA, Nelson-Filho P, Küchler EC, et al. Estrogen deficiency influences TNF- α and IL-1 β gene expression in the odontogenic region of dental hypofunctional condition. *Braz Dent Sci*. 2023;26(2):e3790. <http://dx.doi.org/10.4322/bds.2023.e3790>.
- Küchler EC, Meger MN, Ayumi Omori M, Gerber JT, Martins EC No, Machado NCS, et al. Association between oestrogen receptors and female temporomandibular disorders. *Acta Odontol Scand*. 2020;78(3):181-8. <http://dx.doi.org/10.1080/00016357.2019.1675904>. PMID:31646926.
- Omori MA, Marañón-Vásquez GA, Romualdo PC, Martins EC No, Stuani MBS, Matsumoto MN, et al. Effect of ovariectomy on maxilla and mandible dimensions of female rats. *Orthod Craniofac Res*. 2020;23(3):342-50. <http://dx.doi.org/10.1111/ocr.12376>. PMID:32246880.
- Küchler EC, Lara RM, Omori MA, Schröder A, Teodoro VB, Baratto-Filho F, et al. Estrogen deficiency affects tooth formation and gene expression in the odontogenic region of female rats. *Ann Anat*. 2021;236:151702. <http://dx.doi.org/10.1016/j.aanat.2021.151702>. PMID:33607226.
- Xavier TA, Madalena IR, Silva RAB, Silva LAB, Silva MJB, Rossi A, et al. Vitamin D deficiency is a risk factor for delayed tooth eruption associated with persistent primary tooth. *Acta Odontol Scand*. 2021;79(8):600-5. <http://dx.doi.org/10.1080/00016357.2021.1918762>. PMID:33944665.
- Bikle DD. Vitamin D metabolism, mechanism of action, and clinical applications. *Chem Biol*. 2014;21(3):319-29. <http://dx.doi.org/10.1016/j.chembiol.2013.12.016>. PMID:24529992.
- Freitas AT, Calhau C, Antunes G, Araújo B, Bandeira M, Barreira S, et al. Vitamin D-related polymorphisms and vitamin D levels as risk biomarkers of COVID-19 disease severity. *Sci Rep*. 2021;11(1):20837. <http://dx.doi.org/10.1038/s41598-021-99952-z>. PMID:34675344.
- Küchler EC, Reis CLB, Marañón-Vásquez G, Nelson-Filho P, Matsumoto MAN, Stuani MBS, et al. Parathyroid hormone gene and genes involved in the maintenance of vitamin D levels association with mandibular retrognathism. *J Pers Med*. 2021;11(5):369. <http://dx.doi.org/10.3390/jpm11050369>. PMID:34063310.
- Scardina GA, Messina P. Good oral health and diet. *J Biomed Biotechnol*. 2012;2012:720692. <http://dx.doi.org/10.1155/2012/720692>. PMID:22363174.
- Uwitonze AM, Murererehe J, Ineza MC, Harelimana EI, Nsabimana U, Uwambaye P, et al. Effects of vitamin D status on oral health. *J Steroid Biochem Mol Biol*. 2018;175:190-4. <http://dx.doi.org/10.1016/j.jsbmb.2017.01.020>. PMID:28161532.
- Kinuta K, Tanaka H, Moriwake T, Aya K, Kato S, Seino Y. Vitamin D is an important factor in estrogen biosynthesis of both female and male gonads. *Endocrinology*. 2000;141(4):1317-24. <http://dx.doi.org/10.1210/endo.141.4.7403>. PMID:10746634.
- Welsh J, Wietzke JA, Zinser GM, Byrne B, Smith K, Narvaez CJ. Vitamin D-3 receptor as a target for breast cancer prevention. *J Nutr*. 2003;133(7, Suppl):2425S-33S. <http://dx.doi.org/10.1093/jn/133.7.2425S>. PMID:12840219.
- Li C, Cui Y, Zhou C, Sun J, Zhou X. Epigenetics in odontogenesis and its influences. *Curr Stem Cell Res Ther*. 2018;13(2):110-7. <http://dx.doi.org/10.2174/1574888X12666170530100524>. PMID:28554314.
- Berdal A, Balmain N, Cuisinier-Gleizes P, Mathieu H. Histology and microradiography of early post-natal molar tooth development in vitamin-D deficient rats. *Arch Oral Biol*. 1987;32(7):493-8. [http://dx.doi.org/10.1016/S0003-9969\(87\)80010-9](http://dx.doi.org/10.1016/S0003-9969(87)80010-9). PMID:3479087.
- Kilkenny C, Browne WJ, Cuthill IC, Emerson M, Altman DG. Improving bioscience research reporting: the ARRIVE guidelines for reporting animal research. *PLoS Biol*. 2010;8(6):e1000412. <http://dx.doi.org/10.1371/journal.pbio.1000412>. PMID:20613859.
- Nazet U, Schröder A, Grässel S, Muschter D, Proff P, Kirschnack C. Housekeeping gene validation for RT-qPCR studies on synovial fibroblasts derived from healthy and osteoarthritic patients with focus on mechanical loading. *PLoS One*. 2019;14(12):e0225790. <http://dx.doi.org/10.1371/journal.pone.0225790>. PMID:31809510.
- Manolagas SC, O'Brien CA, Almeida M. The role of estrogen and androgen receptors in bone health and disease. *Nat Rev Endocrinol*. 2013;9(12):699-712. <http://dx.doi.org/10.1038/nrendo.2013.179>. PMID:24042328.
- Alemany M. Estrogens and the regulation of glucose metabolism. *World J Diabetes*. 2021;12(10):1622-54. <http://dx.doi.org/10.4239/wjdv12i10.1622>. PMID:34754368.
- Torosyan N, Visrodia P, Torbati T, Minissian MB, Shufelt CL. Dyslipidemia in midlife women: approach and considerations during the menopausal transition. *Maturitas*. 2022;166:14-20. <http://dx.doi.org/10.1016/j.maturitas.2022.08.001>. PMID:36027726.
- Braegger C, Campoy C, Colomb V, Decsi T, Domellof M, Fewtrell M, et al. Vitamin D in the healthy European paediatric population. *J Pediatr Gastroenterol Nutr*. 2013;56(6):692-701. <http://dx.doi.org/10.1097/MPG.0b013e31828f3c05>. PMID:23708639.
- Schmitt EB, Nahas-Neto J, Bueloni-Dias F, Poloni PF, Orsatti CL, Nahas EAP. Vitamin D deficiency is associated with metabolic syndrome in postmenopausal women. *Maturitas*. 2018;107:97-102. <http://dx.doi.org/10.1016/j.maturitas.2017.10.011>. PMID:29169589.
- Kwak JH, Hong YC, Choi YH. Serum 25-hydroxyvitamin D and hypertension in premenopausal and postmenopausal women: National Health and Nutrition Examination Surveys 2007-2010. *Public Health Nutr*. 2020;23(7):1236-46. <http://dx.doi.org/10.1017/S1368980019003665>. PMID:31948509.
- Nepal AK, van Essen HW, van der Veen AJ, van Wieringen WN, Stavenuiter AWD, Cayami FK, et al. Mechanical stress regulates bone regulatory gene expression independent of estrogen and vitamin D deficiency in rats. *J Orthop Res*. 2021;39(1):42-52. <http://dx.doi.org/10.1002/jor.24775>. PMID:32530517.

27. Amini S, Amani R, Jafarirad S, Cheraghian B, Sayyah M, Hemmati AA. The effect of vitamin D and calcium supplementation on inflammatory biomarkers, estradiol levels and severity of symptoms in women with postpartum depression: a randomized double-blind clinical trial. *Nutr Neurosci.* 2022;25(1):22-32. <http://dx.doi.org/10.1080/1028415X.2019.1707396>. PMID:31900080.
28. Sire A, Gallelli L, Marotta N, Lippi L, Fusco N, Calafiore D, et al. Vitamin D deficiency in women with breast cancer: a correlation with osteoporosis? A machine learning approach with multiple factor analysis. *Nutrients.* 2022;14(8):1586. <http://dx.doi.org/10.3390/nu14081586>. PMID:35458148.
29. Küchler EC, Lara RM, Omori MA, Marañón-Vásquez G, Baratto-Filho F, Nelson-Filho P, et al. Effects of estrogen deficiency during puberty on maxillary and mandibular growth and associated gene expression: an μ CT study on rats. *Head Face Med.* 2021;17(1):14. <http://dx.doi.org/10.1186/s13005-021-00265-3>. PMID:33888144.
30. Bergamo AZN, Madalena IR, Omori MA, Ramazzotto LA, Nelson-Filho P, Baratto-Filho F, et al. Estrogen deficiency during puberty affects the expression of microRNA30a and microRNA503 in the mandibular condyle. *Ann Anat.* 2022;240:151865. <http://dx.doi.org/10.1016/j.aanat.2021.151865>. PMID:34813926.
31. Küchler EC, Carelli J, Morais ND, Brancher JA, Lopes CMCF, Baratto-Filho F, et al. Assessing the association between vitamin D receptor and dental age variability. *Clin Oral Investig.* 2022;26(2):1677-82. <http://dx.doi.org/10.1007/s00784-021-04140-y>. PMID:34463798.
32. Jin Y, Wang J, Bachtiar M, Chong SS, Lee CG. Architecture of polymorphisms in the human genome reveals functionally important and positively selected variants in immune response and drug transporter genes. *Hum Genomics.* 2018;12(1):43. <http://dx.doi.org/10.1186/s40246-018-0175-1>. PMID:30219098.
33. Bittencourt MV, Cericato GO, Franco A, Girão RS, Lima APB, Paranhos LR. Accuracy of dental development for estimating the pubertal growth spurt in comparison to skeletal development: a systematic review and meta-analysis. *Dentomaxillofac Radiol.* 2017;47(4):20170362. <http://dx.doi.org/10.1259/dmfr.20170362>. PMID:29241366.
34. Miyazaki A, Sugimoto A, Yoshizaki K, Kawarabayashi K, Iwata K, Kurogoushi R, et al. Coordination of WNT signaling and ciliogenesis during odontogenesis by piezo type mechanosensitive ion channel component 1. *Sci Rep.* 2019;9(1):14762. <http://dx.doi.org/10.1038/s41598-019-51381-9>. PMID:31611621.
35. Jiang X, Kiel DP, Kraft P. The genetics of vitamin D. *Bone.* 2019;126:59-77. <http://dx.doi.org/10.1016/j.bone.2018.10.006>. PMID:30316967.
36. Boyadjiev SA, Fromme JC, Ben J, Chong SS, Nauta C, Hur DJ, et al. Cranio-lenticulo-sutural dysplasia is caused by a SEC23A mutation leading to abnormal endoplasmic-reticulum-to-Golgi trafficking. *Nat Genet.* 2006;38(10):1192-7. <http://dx.doi.org/10.1038/ng1876>. PMID:16980979.
37. Küchler EC, Schröder A, Teodoro VB, Nazet U, Scariot R, Spanier G, et al. The role of 25-hydroxyvitamin-D3 and vitamin D receptor gene in human periodontal ligament fibroblasts as response to orthodontic compressive strain: an in vitro study. *BMC Oral Health.* 2021;21(1):386. <http://dx.doi.org/10.1186/s12903-021-01740-8>. PMID:34362362.
38. Jones G, Prosser DE, Kaufmann M. 25-Hydroxyvitamin D-24-hydroxylase (CYP24A1): its important role in the degradation of vitamin D. *Arch Biochem Biophys.* 2012;523(1):9-18. <http://dx.doi.org/10.1016/j.abb.2011.11.003>. PMID:22100522.
39. Foucan L, Vélayoudom-Céphise FL, Larifla L, Armand C, Deloumeaux J, Fagour C, et al. Polymorphisms in GC and NADSYN1 Genes are associated with vitamin D status and metabolic profile in Non-diabetic adults. *BMC Endocr Disord.* 2013;13(1):36. <http://dx.doi.org/10.1186/1472-6823-13-36>. PMID:24073860.

Isabela Ribeiro Madalena

(Corresponding address)

Centro Universitário Presidente Tancredo de Almeida Neves, Faculdade de Odontologia,

São João del Rei, MG, Brazil.

Email: isabelarmadalena@hotmail.com

Date submitted: 2023 Mar 09

Accept submission: 2024 Jan 17