

Validation of CBCT panoramic reformatting compared to conventional panoramic radiography for age determination using the Demirjian method

Validação da reconstrução panorâmica da TCFC em comparação com a radiografia panorâmica convencional para a determinação da idade utilizando o método Demirjian

Rosana Mara Adami TUCUNDUVA¹ , Cássia Maria Fischer RUBIRA¹ , Heitor Marques HONÓRIO² ,
Camila Lopes CARDOSO¹ , Izabel Regina Fischer RUBIRA-BULLEN¹ 

1 - Departamento de Cirurgia, Estomatologia, Patologia e Radiologia, Faculdade de Odontologia de Bauru, Universidade de São Paulo, Bauru, São Paulo, Brasil.

2 - Departamento de Odontopediatria, Ortodontia e Saúde Coletiva, Faculdade de Odontologia de Bauru, Universidade de São Paulo, Bauru, São Paulo, Brasil.

How to cite: Tucunduva RMA, Rubira CMF, Honório HM, Cardoso CL, Rubira-Bullen IRF. Validation of CBCT panoramic reformatting compared to conventional panoramic radiography for age determination using the Demirjian method. *Braz Dent Sci.* 2025;28(1):e4668. <https://doi.org/10.4322/bds.2025.e4668>

ABSTRACT

Objective: Estimating age from dental development is a useful indicator that is considered highly reliable and can be of great help in determining an individual's age, although the accuracy of different methods has not been systematically investigated. The aim of this study was to evaluate images of conventional digital panoramic radiographs (CP) and panoramic reformats (PR) obtained from cone beam computed tomography (CBCT) in order to confirm the similarity of the methods. **Material and Methods:** A sample of 20 patients who had conventional panoramic radiographs (CP) and also CBCT exams was evaluated. These examinations were performed on the same date, so there was no variation in the mineralization stage in the different images. The images were analyzed by a dentist, a specialist in Radiology and Imaging, and, before the beginning of the analysis, an intra-examiner calibration was performed, resulting in a good Kappa index evaluation (> 0.5). **Results:** In this study, age estimation based on mineralization analysis of mandibular third molar teeth was not altered when using PR (CBCT) or CP. The difference in median values between the two groups is no statistically significant difference. **Conclusion:** The methods evaluated were found to be consistent with one another, thereby confirming the similarity of their efficacy.

KEYWORDS

Age determination by teeth; Cone beam computed tomography; Forensic Dentistry; Panoramic radiography; Radiography, Dental.

RESUMO

Objetivo: A estimativa da idade a partir do desenvolvimento dentário é um indicador útil, altamente confiável e que pode ser de grande ajuda na determinação da idade de um indivíduo, embora a precisão dos diferentes métodos não tenha sido sistematicamente investigada. O objetivo deste estudo foi avaliar imagens de radiografias panorâmicas digitais convencionais (PC) e reformatações panorâmicas (RP) obtidas por tomografia computadorizada de feixe cônico (TCFC), a fim de confirmar a similaridade dos métodos. **Material e Métodos:** Foi avaliada uma amostra de 20 pacientes que realizaram radiografias panorâmicas convencionais (CP) e também exames de TCFC. Esses exames foram realizados na mesma data, de modo que não houve variação no estágio de mineralização nas diferentes imagens. As imagens foram analisadas por um cirurgião-dentista, especialista em Radiologia e Imaginologia, e, antes do início da análise, foi realizada uma calibração intra-examinador, resultando em uma boa avaliação do índice Kappa ($> 0,5$). **Resultados:** Neste estudo, a estimativa de idade baseada na análise da

mineralização dos dentes terceiros molares inferiores não foi alterada quando se utilizou a RP (TCFC) ou a CP. A diferença nos valores medianos entre os dois grupos não apresentou diferença estatisticamente significativa. **Conclusão:** Os métodos avaliados mostraram-se consistentes entre si, confirmando assim a similaridade de sua eficácia.

PALAVRAS-CHAVE

Determinação da idade pelos dentes; Tomografia computadorizada de feixe cônico; Medicina dentária forense; Radiografia panorâmica; Radiografia dental.

INTRODUCTION

Estimating age from dental development is a useful indicator that is considered highly reliable and can be of great help in determining an individual's age, although the accuracy of different methods has not been systematically investigated [1,2]. There is a consensus that the dental development patterns of Demirjian [3] are among the most accurate systems classifications and one of the most widely accepted by forensic scientists. They are considered the easiest and clearest evaluation method [1,4-7].

The authors assert that dental age can be accurately assessed through direct and indirect examinations [8]. The direct examination is made by clinical examination, which definitively verifies the number and sequence of erupted teeth as well as the general state of the teeth. Indirect examination is performed by analyzing intraoral and extraoral radiographs, which allow for the definitive evaluation of items contained in the direct examination, especially those related to dental mineralization [8]. A variety of imaging tests are used in radiological imaging, including periapical, interproximal, and panoramic radiographs.

Cone beam computed tomography (CBCT) is a diagnostic tool and an essential part of a treatment plan [9,10]. It is crucial to emphasize that these examinations cannot be conducted solely to ascertain age in certain countries, as exposure to ionizing radiation without consent is unlawful in those jurisdictions [11,12]. It is crucial to validate the various imaging exams used to assess tooth mineralization and determine age. This will confirm that age determination from images produced by various techniques will not interfere with the age. This allows us to make this determination from an examination that is already available, without subjecting the person to additional ionizing radiation.

So, using lower third molar mineralization (teeth 38 and/or 48) from conventional panoramic radiographs (CP) and panoramic reformatting (PR) obtained from the CBCT, we conducted a study to ascertain the age of young people. Analysis was performed using the approach put forth by Demirjian et al. [3], as modified by Oliveira in 2012 [5]. The results were compared to see if there was any variation in the results.

MATERIAL AND METHODS

The study conducted used a reliable and established method for analyzing tooth mineralization, which increases the validity and accuracy of the results obtained. The sample was obtained from the digital archive of the FOB-USP Surgery, Stomatology, Pathology, and Radiology Department, Bauru, São Paulo, Brazil. Therefore, we confirm that no patient was exposed to ionizing radiation in the course of this research.

Ethical approval was obtained from Ethics committee at Bauru School of Dentistry, University of São Paulo (FOB-USP), ERC Number: 1,959,514 (CAAE: 65053717.4.0000.5417).

A sample of 20 patients who had conventional panoramic radiographs (CP) and also CBCT exams was evaluated. These examinations were performed on the same date, so there was no variation in the mineralization stage in the different images. The images were analyzed by a dentist, a specialist in Radiology and Imaging, and, before the beginning of the analysis, an intra-examiner calibration was performed, resulting in a good Kappa index evaluation (> 0.5). The CP was performed on the Kodak 8000C® Digital and Cephalometric System and the CBCT on the Accuitomo® device and analyzed in a room with specific equipment for this purpose.

The sample consisted of 9 men and 11 women, with a mean age of 22.9 years (13–38). The

Chronological Age was calculated by subtracting the year of birth from the year of the exam, as found in the medical records. Considering that the sharpness of the image in CP is related to the focal layer thickness, for the PR to present similar characteristics of the CP, they were generated with a thickness of 12mm, which is, according to Pinto et al., [10], the CP focal layer thickness of the panoramic devices.

This sample's exams met the following inclusion and exclusion rules: 1. CBCT exams had a field of view (FOV) encompassing the mandible alone or the maxilla and mandible. 2. In the examination, one or two lower third molars (teeth 38 and/or 48) should be present, and, to validate that the evaluated tooth was the third molar, the presence of the first and second molars was a condition "sine qua non". 3. Tests with good image quality and no interference in the area of interest that could compromise the correct evaluation.

The scores were carefully assigned, following the criteria described by each dental stage by Oliveira et al. [5], comparing the images of the teeth with diagrams provided by Demirjian and modified by Oliveira et al. [5] (Table I, Figure 1). If in doubt between two phases, the least developed stage was assigned to the tooth.

Table I - Stages evaluated description according to the method proposed by Demirjian et al. [3], modified by Oliveira et al. [5]

STAGES	DESCRIPTION
-1	Radiolucent image with radiopaque halo in the third molar region related to the dental germ
1 (A)	A start of calcification can be seen at the top of the crypt in the form of inverted cones. There is no union between these calcified points.
2 (B)	Calcified points form cusps union, which together form the occlusal surface outline.
3 (C)	Complete enamel formation on the occlusal surface and convergence to the cervical region. Beginning of dentinal deposit, with outline of the pulp chamber in curved shape at the occlusal edge.
4 (D)	Complete crown formation up to enamel cementum junction. Beginning of root formation in spike shape.
5 (E)	Initial formation of root bifurcation in the shape of a calcified point. The root length is still shorter than the crown height.
6 (F)	Greater development of the bifurcation calcified region in the semilunar form. Roots equal to or greater than crown height, and with more definite and more distinct funnel-shaped outline at its end.
7 (G)	Root canal walls are parallel, and their apical regions are still partially open.
8 (H)	Apical end of root canals are completely closed. The periodontal space has a uniform width around the root and apex.

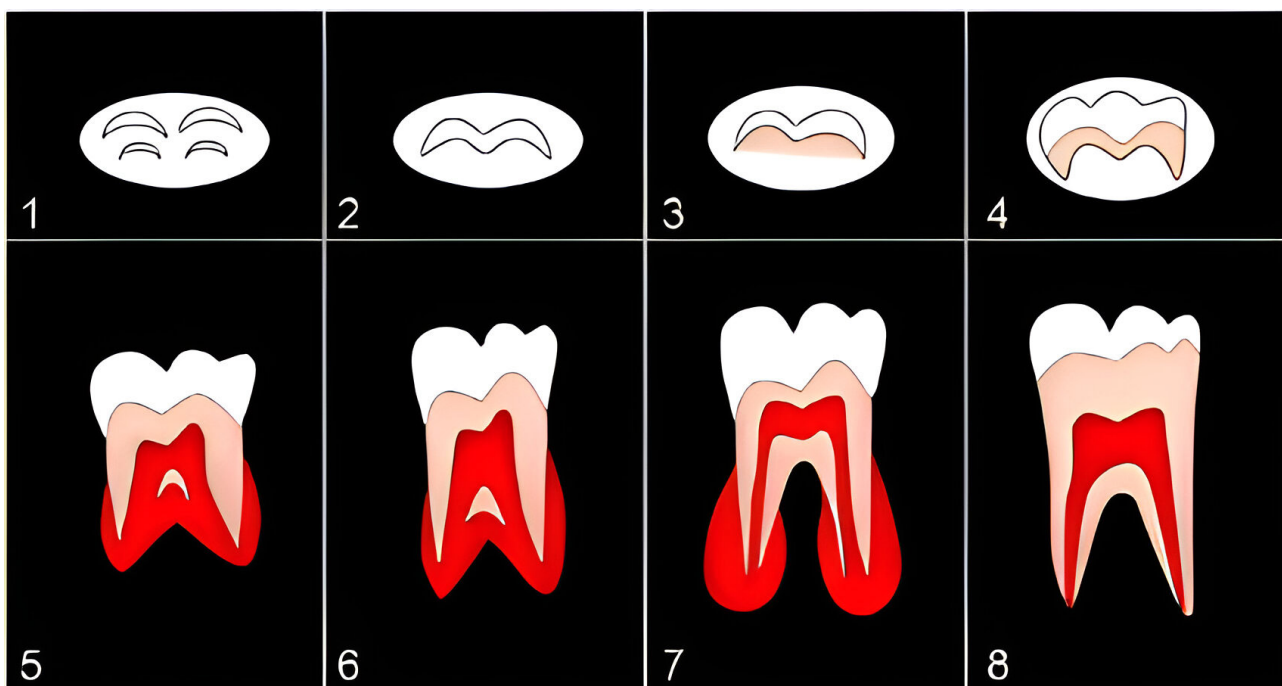


Figure 1 - Stages of dental mineralization.

RESULTS

The Chi Square Test was applied to check if there was a discrepancy between the stages attributed to teeth 38 and 48 in the PR and the results obtained in the evaluation of the PR generated in the CBCT. It was found to be $p = 0.605$ for tooth 38 and $p = 1.000$ for tooth 48. When applying the Mann-Whitney Test using age-dependent variables, we found $p = 0.943$ for teeth 48 and $p = 0.882$ for teeth 38. The difference in median values between the two groups is not large enough to exclude the possibility that the difference is due to random sampling variability. There is no statistically significant difference.

DISCUSSION

This analysis aimed to verify the similarity of results between the analyses performed in CP and the analysis performed in PR obtained from CBCT. In order to make the panoramic reformatting image as similar as possible to the panoramic radiography image, especially with regard to image overlap, a 12mm thickness was generated, which is, according to the literature used, the focal layer thickness of the panoramic device used for the examinations we evaluated.

In order to compare the results of the analyses, we evaluated the mineralization stages of teeth 38 and 48 in the examinations of 20 individuals who had the CP and CBCT exams performed on the same date. Although our sample size may seem small compared to similar studies [13,14], confirmed that a small sample size is not considered a limitation in forensic scientific research.

The Demirjian, Goldstein, and Tanne method [3], which is regarded as a method with easy reproducibility because it has clearly defined stages and few intermediate stages, served as the foundation for the entire study [6]. It is noteworthy that we included stage 1, which corresponds to the dental crypt, based on the work of Oliveira [5]. Demirjian et al. [3], who presented research from a French-Canadian population and described 8 distinct stages, called stages A–H, defined by morphological changes, introduced the method, which is now widely used. It is possible to determine the chronological age of Brazilians by using the Demirjian method [3] to assess the third molar stage of development,

according to Soares et al. [15], who evaluated at 2097 panoramic radiographic images of patients from northeastern Brazil aged 6 to 22 years.

The method of Demirjian et al. [3] has been widely used to estimate dental age in numerous studies across different ethnic groups, analyzing European, South American, and Asian individuals, among other populations [14]. It has been suggested that there may be different patterns of dental maturation between different populations, not only between population groups worldwide but also between individuals from different cities or regions within the same country [16]. This motivated us to conduct a new study within the same parameters of analysis in a portion of the Brazilian population in order to contribute to an increase in data and information about the age estimate in the Brazilian population.

To date, dental age has been primarily investigated based on dental radiographs, mainly panoramic radiographs [16,17]. Panoramic radiography is an important imaging technique used as a complementary exam for diagnosis in dental practice because it provides a general two-dimensional view, allowing the visualization of oral hard tissues and adjacent structures [18]. However, according to authors, RP is more advantageous than CP because it allows the determination of the desired image thickness and does not present the magnification or distortion inherent to CP [19].

We measured the degree of mineralization in teeth 38 and 48, which are third molars. They are regarded as the most unstable teeth when compared to other teeth because they exhibit the greatest variation in morphology, anatomical position, time of development, and eruption, and their accuracy in estimating age in chronological studies is debatable [20]. Age and the completion of dental maturation, however, cause the amount of information to diminish until it is only present in the third molars. According to Thevissen et al. [21], the development of these teeth is a lengthy process that may not be completed until the age of twenty-two. According to authors the third molar is the last tooth to develop before the human skeleton starts to grow [21].

CONCLUSION

Our findings show that using CBCT PR or CP does not interfere with determining age

from the analysis of lower third molar tooth mineralization. The methods evaluated were found to be consistent with one another, thereby confirming the similarity of their efficacy. However, we believe that more studies like ours should be conducted to increase the number of individuals evaluated, and the findings of this research should be used wisely, always in conjunction with other available methods of estimating age, to avoid incorrect imputations.

Author's Contributions

RMAT: Conceptualization, Methodology, Formal Analysis, Validation, Resources, Writing – Original Draft Preparation, Writing – Review & Editing. CMFR: Methodology, Writing – Review & Editing. HMH, CLC: Writing – Review & Editing. IRFRB: Conceptualization, Methodology, Writing – Review & Editing, Supervision.

Conflict of Interest

The authors declare to have no conflict of interest.

Funding

The authors received financial support for the research by CAPES 001.

Regulatory Statement

Ethical approval was obtained from Ethics committee at Bauru School of Dentistry, University of São Paulo (FOB-USP), ERC Number: 1,959,514 (CAAE: 65053717.4.0000.5417).

REFERENCES

- Maber M, Liversidge HM, Hector MP. Accuracy of age estimation of radiographic methods using developing teeth. *Forensic Sci Int.* 2006;159(1, Suppl 1):S68-73. <http://doi.org/10.1016/j.forsciint.2006.02.019>. PMID:16533584.
- Alqadi MA, Abuaffan AH. The reliability of Fishman and Nolla methods in prediction of chronological age of Yemeni children. *Braz Dent Sci.* 2020;23(3):1-9. <http://doi.org/10.14295/bds.2020.v23i3.1976>.
- Demirjian A, Goldstein H, Tanner JM. A new system of dental age assessment. *Hum Biol.* 1973;45(2):211-27. PMID:4714564.
- Hägg U, Matsson L. Dental maturity as an indicator of chronological age: the accuracy and precision of three methods. *Eur J Orthod.* 1985;7(1):25-34. <http://doi.org/10.1093/ejo/7.1.25>. PMID:3856522.
- Oliveira FT, Capelozza AL, Lauris JR, de Bullen IR. Mineralization of mandibular third molars can estimate chronological age-

- Brazilian indices. *Forensic Sci Int.* 2012;219(1-3):147-50. <http://doi.org/10.1016/j.forsciint.2011.12.013>.
- Flood SJ, Mitchell WJ, Oxnard CE, Turlach BA, McGeachie J. To evaluate the utility of smaller sample sizes when assessing dental maturity curves for forensic age estimation. *J Forensic Sci.* 2011;56(6):1604-9. <http://doi.org/10.1111/j.1556-4029.2011.01884.x>. PMID:21854379.
- Comar LP, Gobbo S, Cal Alonso MB, Koharu K, Teixeira D, Silva M, et al. The dental age estimation by Demirjian, Willems and AlQahtani methods in a Brazilian population: age estimation by dental methods. *BJHBS.* 2024;23(2):28-37. <https://doi.org/10.12957/bjhbs.2024.88695>.
- Peiris TS, Roberts GJ, Prabhu N. Dental Age Assessment: a comparison of 4- to 24-year-olds in the United Kingdom and an Australian population. *Int J Paediatr Dent.* 2009;19(5):367-76. <http://doi.org/10.1111/j.1365-263X.2009.00984.x>. PMID:19486370.
- Gruber J, Kameyama MM. The role of radiology in forensic dentistry. *Pesqui Odontol Bras.* 2001;15(3):263-8. <http://doi.org/10.1590/S1517-74912001000300014>. PMID:11705275.
- Pinto PHV, Ferraz MAAL, Souza SCS Jr, Mendes JP, Costa ALF, Lopes SLPC, et al. Assessment of the opening diameter of the incisive foramen as a parameter for gender and age estimation. *Braz Dent Sci.* 2017;20(4):106-14. <https://doi.org/10.14295/bds.2017.v20i4.1458>.
- Willmann C, Fernandez De Grado G, Kolb C, Raul JS, Musset AM, Gros CI, et al. Accuracy of age estimation using three dental age estimation methods in a young, large, and multiethnic patient sample. *Dent J.* 2023;11(12):288. <http://doi.org/10.3390/dj11120288>. PMID:38132426.
- Baumann P, Widek T, Merckens H, Boldt J, Petrovic A, Urschler M, et al. Dental age estimation of living persons: comparison of MRI with OPG. *Forensic Sci Int.* 2015;253:76-80. <http://doi.org/10.1016/j.forsciint.2015.06.001>. PMID:26093127.
- Cidade R, Santos M, Alves TC, Bueno JM, Soares M, Arakelyan M, et al. Radiographic dental age estimation applying and comparing Demirjian's seven (1973) and four (1976) teeth methods. *Forensic Sci Med Pathol.* 2023;19(2):175-83. <http://doi.org/10.1007/s12024-022-00563-5>. PMID:36806081.
- Dhanjal KS, Bhardwaj MK, Liversidge HM. Reproducibility of radiographic stage assessment of third molars. *Forensic Sci Int.* 2006;159(Suppl 1):S74-7. <http://doi.org/10.1016/j.forsciint.2006.02.020>. PMID:16530998.
- Soares CB, Figueiroa JN, Dantas RM, Kurita LM, Pontual AA, Ramos-Perez FM, et al. Evaluation of third molar development in the estimation of chronological age. *Forensic Sci Int.* 2015;254:13-7. <http://doi.org/10.1016/j.forsciint.2015.06.022>. PMID:26164359.
- Vieira MCA, Lima TBS, Costa RL, Nery IFNO, Corrêa GTB, Andrade RCDV. Análise radiográfica para estimativa de idade utilizando o método Demirjian em uma população do nordeste do Brasil. *RBOL.* 2016;3:32-40. <http://doi.org/10.21117/rbol.v3i1.56>.
- Panchbhai AS. Dental radiographic indicators, a key to age estimation. *Dentomaxillofac Radiol.* 2011;40(4):199-212. <http://doi.org/10.1259/dmfr/19478385>. PMID:21493876.
- Birchler FA, Kiliaridis S, Combescure C, Vazquez L. Dental age assessment on panoramic radiographs in a Swiss population: a validation study of two prediction models. *Dentomaxillofac Radiol.* 2016;45(1):20150137. <http://doi.org/10.1259/dmfr.20150137>. PMID:26250402.
- Suomalainen A, Pakbaznejad Esmaeili E, Robinson S. Dentomaxillofacial imaging with panoramic views and cone beam CT. *Insights Imaging.* 2015;6(1):1-16. <http://doi.org/10.1007/s13244-014-0379-4>. PMID:25575868.
- Zandi M, Shokri A, Malekzadeh H, Amini P, Shafiey P. Evaluation of third molar development and its relation to chronological age: a panoramic radiographic study. *Oral Maxillofac Surg.* 2015;19(2):183-9. <http://doi.org/10.1007/s10006-014-0475-0>. PMID:25409631.

21. Thevissen PW, Fieuws S, Willems G. Human third molars development: comparison of 9 country specific populations.

Forensic Sci Int. 2010;201(1-3):102-5. <http://doi.org/10.1016/j.forsciint.2010.04.054>. PMID:20570071.

**Camila Lopes Cardoso
(Corresponding address)**

Departamento de Cirurgia, Estomatologia, Patologia e Radiologia, Faculdade de Odontologia de Bauru, Universidade de São Paulo, Bauru, São Paulo, Brasil.
Email: cardosolopes@usp.br

Date submitted: 2025 Jan 29
Accept submission: 2025 Feb 12