

Evaluation of the mental foramen position in pediatric patients. *Avaliação da posição do forame mental em pacientes pediátricos*

Sidney Ricardo DOTTO

Pos-Graduated Student – School of Dentistry University of Pernambuco – UPE – Pernambuco – PE – Brasil

Rosana Maria Coelho TRAVASSOS

Professor – Endodontics – School of Dentistry University of Pernambuco – UPE – Pernambuco – PE – Brasil

Edmundo MÉDICI FILHO

Luiz Cesar de MORAES

Titular Professor – Oral Radiology – School of Dentistry – São José dos Campos– , UNESP – São José dos Campos – SP – Brasil

Mari Eli Leonelli de MORAES

Julio Cezar de Melo CASTILHO

Professor – Oral Radiology – School of Dentistry – São José dos Campos– , UNESP – São José dos Campos – SP – Brasil

Carolina de Oliveira Tocaline Walter PORTO

Patrícia Pasquali DOTTO

Pos-Graduated Student – School of Dentistry – São José dos Campos– , UNESP – São José dos Campos – SP – Brasil

ABSTRACT

The aim of the present study was to evaluate the location of the mental foramen, using panoramic x-rays from children with ages among ten to 12 years. In a first moment, the radiographs were digitalized and measures were accomplished in the Image Tool 1.27 software, being verified the distance between the mandible border and the mental foramen inferior portion, the total height of the alveolar ridge, and also the distance between the medium portion of the mental foramen and a traced line of the nasal spine previously to a point located in the most inferior portion of the mentus. In children with ages among ten and 11 years, the percentage occurrence of the mental foramen location was in the inferior third of the alveolar ridge and, in the 12 years age group, it was in the medium third. Authors concluded that the position of the mental foramen modifies with the increase of the age, being important the analysis of the precisely location of the mental foramen in Pediatric Dentistry.

KEY WORDS

Mandible, foramen, pediatric dentistry

INTRODUCTION

The knowledge of the mental foramen precisely location is important to achieve a block anesthesia with efficiency and to dentomaxillofacial surgical procedures. However, there's few agreement about the location of the mental foramen and its anatomic variations. A radiographic evaluation is important to a safer procedure, since the foramen location position modifies with the increase of the age.

Panoramic radiographs are useful to skeleton and dental diseases evaluations, making possible

a bidimensional analysis and showing the relative angulations from teeth to other structures. The advantages of this technique are: lower radiation dose, simple procedure, faster images achievement and full visualization of the jaws in just one radiographic procedure. The disadvantages are: lower definition degree and detail, presence of distortions and the overlap of anatomic structures.

According to Pasler & Visser¹⁰ (2001), within the indications are: location of residual roots, cysts, foreign objects and neoplasias; evaluation of osteoporotic processes and jaw's resorption; analysis of

some anatomic structures location in oral cavity and face previously to the implant treatment. Amir et al.¹ (1998) assessed macerated mandibles from 16 males and 9 females among 27 and 78 years old. These authors had concluded that measurements from different parameters, as those used to evaluate resorptions and to locate anatomic structures as the mental foramen, regardless of the horizontal and vertical dimensions, can be done on panoramic radiographs when just one side of the jaws is used for it and when it is not overtaking the medium sagittal plane. Stramotas et al.¹³ (2002) stated that is possible to achieve precisely measurements from panoramic radiographs since the patient head position is taken correctly at a panoramic appliance.

The knowledge of the mental foramen precisely location is essential in Dentistry to achieve a mandible block anesthesia with efficiency and also to dentomaxillofacial surgical procedures. Although the location has clinical importance, there's few agreement about the mental foramen precisely location due to the variations from normal anatomy (KAFE et al.⁵, 1994). Mental foramen is located under the second premolar, however, in one between four individuals, its location is in the middle distance from both premolars. In dentulous individuals, its location is in the middle distance from mandible border to the alveolar ridge free border at the same vertical direction from supra and infra orbitales foramens. In children, the foramen location is lower, between the first and the second deciduous molars (MADEIRA⁹, 1997).

Jasser & Nwokut⁴ (1998) studied 397 panoramic radiographs and found the mental foramen's position at any region between canine long axis and the mesial side from the first molar, being more frequently found closer from the second premolar root. These authors stated that in those mandibles in development, mental foramen can occupy a different position from that this occupies later. A way to verify anatomic regions in radiographs is using the technique of images digitalization (BUENO et al.³, 1999). A digital image can be obtained by directly and indirectly ways. When done by directly way, a conversion is done from conventional radiography to digital image through a scanner or camera. A scanner can be used with transparency

reader for the radiographs digitalization (CHEN & HOLLENDER², 1995).

Trough this way, the aim of this study was to evaluate the mental foramen location, using linear directly measurements in panoramic radiographs from individuals among ten and 12 years old, and also to compare the measurements among the age groups.

MATERIAL AND METHOD

Panoramic radiographs from Dentistry Radiological Discipline's file were analysed. A consent document had been done and signed by the Discipline's responsible professor giving permission for the use of the radiographs. Panoramic radiographs from male and female individuals were included, in the age group among ten to 12 years old, that presented a good definition of the mental foramen at least in one of the mandibles arches, and a good radiography quality to assess the evaluated structure. Panoramic radiographs were selected from the file and digitalized on the scanner HPScanjet 6100 (Hewlett-Packard Co., Colorado, USA) with transparency reader HPC6261 6100C (Hewlett-Packard Co., Colorado, USA) and its respective software (DeskScan II) to the image capture. Images were captured keeping the brightness and contrast standard among the values of 120 and 140, and 300 dpi of resolution. The image was achieved on TIFF format.

Initially, the digitalized image was calibrated according to the film size of panoramic radiography (KODAK, 30 X 12.5cm), using Image Tool 1.27 Program. Linear measurements were done on digitalized images using some devices from Image Tool 1.27 Program (University of Texas Health Sciences Center, USA), and points of reference were estimated for each measured region, with the purpose to eliminate errors from technique variations. The measurements were done by only one Radiologist specialist, previously trained and the measurement unity was taken in millimeters.

The measurements were done from a point located in the lower portion of the mental foramen to the mandible border at the left side of the panoramic radiographs previously selected and digitalized for each group of individuals evaluated among ten to 12 years old (Figure 1).

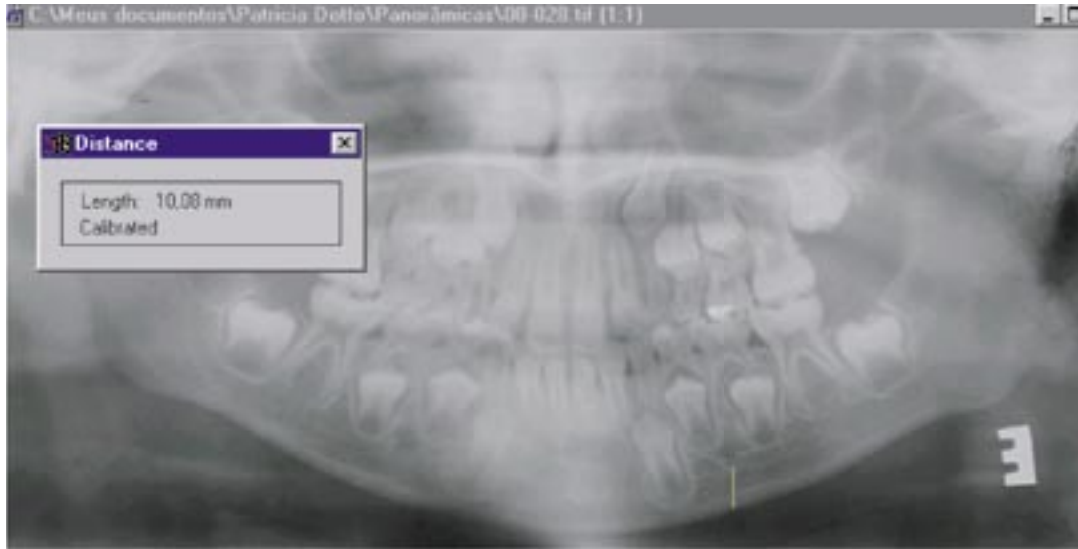

FIGURE 1 – Accomplishment, in the Image Tool software, of the linear measure of the distance from the most inferior portion of the mental foramen to the mandible border

After that, the measurement of the alveolar ridge length was done to the mental foramen region at the left side using the Image Tool 1.27 Program. The distance had been measured from the most superior portion of the alveolar bone located between premolars to the most inferior portion of the mandible border.

The distance from the mental foramen to a fixed point also was measured in the present study. For this purpose, Adobe Photoshop 5.0 Program had been used in which, on the digitalized radiographs, a line

was traced from the anterior nasal spine to the most inferior portion of the mentus. Also, a tangent line was traced to the most inferior border of the mentus using for this devices from Adobe Photoshop 5.0 Program. Then, after the attainment of the referential point on panoramic radiography, images were saved and opened in Image Tool 1.27 Program, where the measurement of the distance between the most mesial portion of the mental foramen and the reference point had been done (Figure 2).

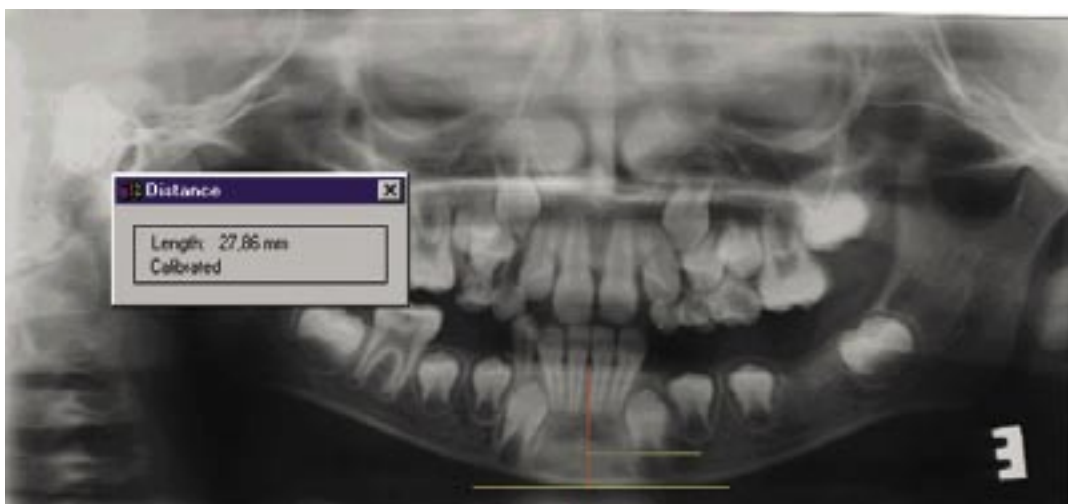


FIGURE 2 – Landmark of a line between the anterior nasal spine and the most inferior portion of the mentus, where a tangent line passes to the mentus, using for this the software Adobe Photoshop 5.0. The figure also presents the measurement of the distance from the middle portion of the mental foramen to that line

RESULTS

A descriptive statistical method of medium and standard shunting had been employed to measure the following distances: the alveolar ridge length in the mandible left side, the distance from the mental foramen to the reference point and the distance from the mental foramen to the mandible border, among the three age groups. The occurrence percentage of

the mental foramen location was also done to the evaluated age groups. The ANOVA test (One-Way) was used to compare the previously mentioned measurements among the age groups in the analyzed individuals.

In this study, a descriptive statistics analysis of medium and shunting standard had been taken to the alveolar ridge measurements on the left side of all analyzed individuals in the three age groups (Figure 3).

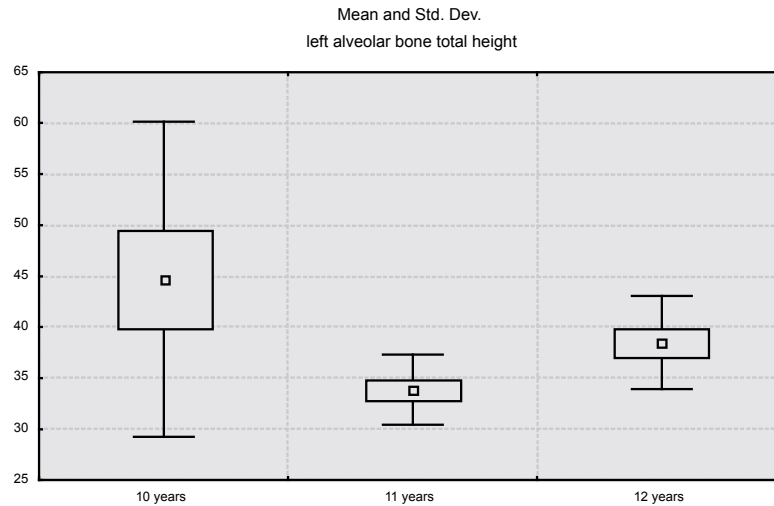


FIGURE 3 – Medium and shunting standard of the inferior alveolar ridge height in the left side of the individuals in the evaluated age groups.

The descriptive statistics analysis of medium and shunting standard was applied to the distance measure-

ments from the mental foramen to the mandible border among the three studied age groups (Figure 4).

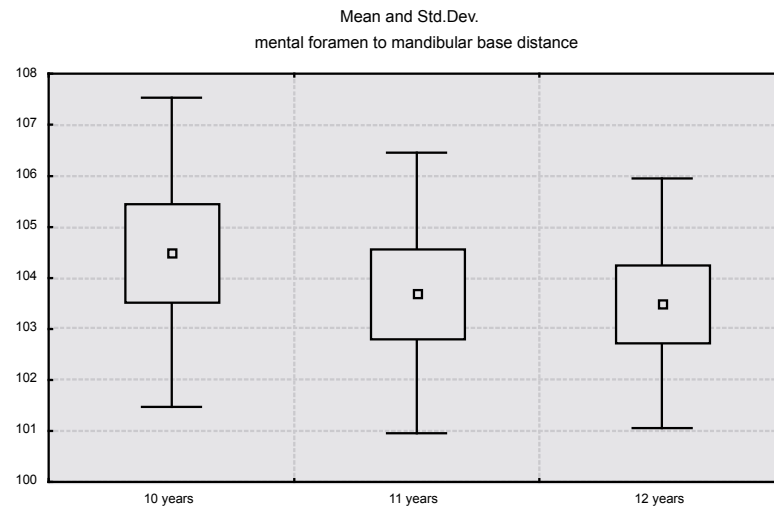


FIGURE 4 – Medium and shunting standard of the distances from the mental foramen to the mandible border in the left side of the individuals in the evaluated age groups

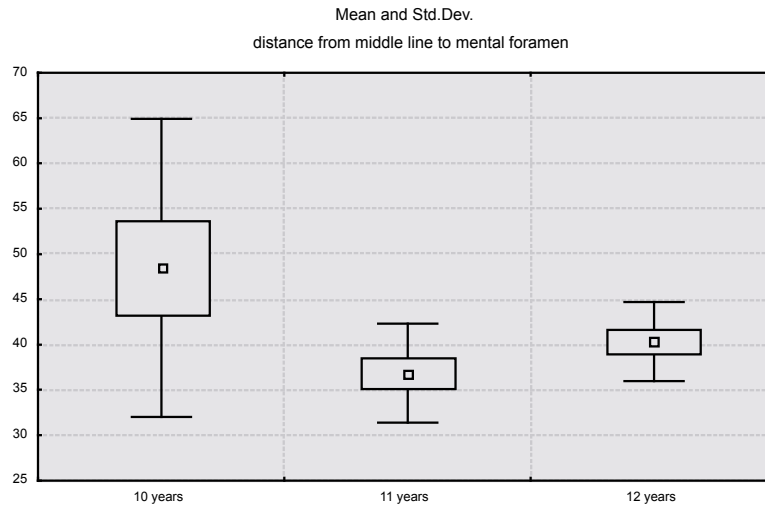


FIGURE 5 – Medium and shunting standard of the distance from the mental foramen to a line traced between the anterior nasal spine and another line that is tangent to the most inferior portion of the mentus.

Figure 5 shows the medium and shunting standard of the measurement from the medium portion of the mental foramen to a line that cross the anterior nasal spine and another line that is tangent to the most inferior portion of the mentus.

The ANOVA test (One-Way) was applied to compare the measurements of the alveolar ridge height in the left side of the age groups (10, 11 and 12 years old). No statistic significant difference had been showed to p value ($p=0.188$). The reliable interval applied was 95%. This test had been taken with 95% reliable interval when the analysis was done for the distance from the most inferior portion of the mental foramen to the mandible border in the left side, among the three studied age groups. A significant statistic difference was noticed when measurements were compared among the studied age groups ($p=0.00$). The ANOVA test (One-Way) with 95% reliable interval was also applied to the analysis of the distance from the mental foramen

to a traced line between the anterior nasal spine and another line that is tangent to the most inferior portion of the mental foramen. When compared these measurements among the studied age groups, no statistic significant difference was found ($p=0.254$).

After, for the most necessary analysis of the mental foramen, a proportion calculation was carried in the following way: the total height of the alveolar ridge was gotten through a linear measure, then this total height was divided into three similar parts: superior, medium and inferior thirds. Based on these results, the measurement of the distance gotten previously from the mental foramen to the mandible border was verified. Thus, it was possible to locate in which third of the mandible the mental foramen was located.

On Table 1 are described the percentage of the mental foramen location in the three mandible thirds among the three studied age groups.

Table 1 – Percentage of the mental foramen location in the mandible thirds among the studied age groups

Age	Superior portion	Middle portion	Inferior portion
10 years	-	44,00%	56,00%
11 years	-	46,40%	53,40%
12 years	-	75,00%	25,00%

DISCUSSION

The knowledge of the mental foramen precisely location is essential to many Dentistry procedures, as much for a surgical safety access as to an efficient block anesthesia. Due to the variation of the anatomic mental foramen position, is of basic importance its analysis on radiographs. Therefore, periapical radiographs or panoramic radiographs are important auxiliaries on diagnosis. In children, mental foramen location is variable and it modifies with the increase of the age. A precisely radiographic analysis facilitates the patient conditioning, as also, the procedure to be carried, since a correctly block anesthesia makes the procedure faster and more comfortable to the patient.

Panoramic radiograph has being used for the analysis of the anatomic and mental foramen position, therefore it provides to the clinician the possibility of a whole diagnosis of the maxillofacial complex and its structures, with a lower radiation dose (LANGLAIS et al.⁶, 1995). In our study, the measurements were done just in one side of the mandible, being the left side the random choice, this because the panoramic radiograph presents an image magnification that differs in different regions. Reiskin¹² (1998) cited that panoramic radiographs are amplified in approximately 10 to 20%, but this magnification isn't uniform in the horizontal and vertical directions. According to Tronje¹⁵ (1983) the images distortions in panoramic radiographs are dependents of the object form: the more rounded, lower is the distortion. In 1985, Tronje et al.¹⁴ related that the vertical and the horizontal factors are modified with position and depth of the object.

Amir et al.¹ (1998) related that, in panoramic radiographs, measurements can be done, however, these can be made only in one side of the jaws and can't exceed the median sagittal plane. Kaffe et al.⁵ (1994) did a study with 100 macerated mandibles from adults to verify if there's correlation in the mental foramen location in panoramic radiographs with its location in macerated mandibles. The authors observed that the obtained radiographs allow the precisely location of the mental foramen previously to surgical procedure. The results in our study showed that no significant statistical difference was found between the total height of the alveolar ridge in the left side among the studied ages and also no significant statistical

difference was found between the distance from the median line traced to the mandible inferior border ($p \geq 0.05$). In relation to the measure of the distance from the mental foramen to the mandible border when compared among ages, significant statistical difference was found ($p \leq 0.05$).

Philips, Weller & Kulid¹¹ (1992) carried a study using 75 macerated mandibles from adults. A vertical line (A-B) was traced from the top of the second premolar vestibular cusp (A), following the clinician long axis of its crown, going in the direction of the mandible inferior border (B). Mental foramen position had been identified related to this line. Other line (C-D) had been bounded from the mental foramen center until it cross line A-B in point D. The vertical distance average, extending from the top of the second premolar crown to the mental foramen center and from this point to the mandible border had presented relatively constant in 60% of the cases. In this study, devices from Image Tool 1.27 were used for the linear measurements accomplishment and also devices from Adobe Photoshop 5.0 were used to achieve the radiographs tracings.

When carried the mental foramen location analysis in one of the three mandibles thirds, it was observed that in the age groups of 10 and 11 years old, the greater occurrence percentage was found in the inferior third (Table 1) and for those with 12 years old this percentage was greater in the medium third. Jasser and Nwoku⁴ (1998) carried a study and had found that in the development of the mandible, the mental foramen can occupy a different position from the one gotten later. Lotric⁸ (1955) commented that importance must be given to the fact that the mental foramen location modifies with the increase of the age, because to the birth it is found nearest from canine germ and with the increase of the age this dislocates backwards.

CONCLUSION

The authors concluded that with the increase of the age some modifies occurs in the mental foramen position. The greater occurrence was found in the inferior third among the ages of 10 and 11 years old and the greater percentage was found in the medium third for individuals with 12 years old.

RESUMO

O objetivo do presente estudo foi avaliar a localização do forame mental, em radiografias panorâmicas de crianças com idades entre dez e 12 anos. Para tanto, as radiografias foram digitalizadas e mensuradas no programa Image Tool 1.27, sendo verificadas a distância da porção mais inferior do forame mental à base da mandíbula, a altura total do rebordo alveolar e a distância da porção média do forame à uma linha traçada da espinha nasal anterior à um ponto na porção mais inferior do mento. Nas crianças com idades dez e 11 anos, o maior percentual de ocorrência se deu no terço inferior e na faixa etária de 12 anos, houve um percentual maior no terço médio. Os autores concluíram que a posição do forame mental muda com o aumento da idade, sendo importante a verificação precisa do forame em procedimentos odontológicos.

UNITERMOS

Mandíbula; forame; odontologia pediátrica

REFERENCES

1. Amir C, Asja C, Melita VP, Adnan C, Vjekoslav J, Muretic I. Evaluation of the precision of dimensional measurements of the mandible on panoramic radiographs. *Oral Surg Oral Med Oral Pathol Oral Radiol Endod.* 1998 Aug.; 86(2):242-48.
2. Chen SK, Hollender I. Modulation transfer function of digital dental X-ray system. *Oral Surg.* 1994; 77:308-13.
3. Bueno NLO, Dotto SR, Ferreira R, Dotto GN, Casagrande L, Silveira BL, et al. Radiologia Odontológica e a imagem digital. *J Assess Odontol.* 1999; 3(15):28-33.
4. Jasser NMAI, Nwoku AL. Radiographic study of the mental foramen in a selected Saudi population. *Dentomaxillofac Radiol.* 1998; 27(6):341-43.
5. Kaffe I, Ardekian L, Gelerenter I, Taicher S. Location of the mandibular foramen in panoramic radiographs. *Oral Surg Oral Med Oral Pathol.* 1994 Nov; 78(5):662-9.
6. Langlais RP, Broadus R, Glass BJ. Bifid mandibular canals in panoramic radiographs. *J Am Dent Assoc.* 1995; 110:923-26.
7. Langland OE. Textbook of dental radiology. Springfield : Thomas; 1984
8. Lotric N. Foramen mentale. Morphological and topographical investigation. *Srpski Archiv.* 1955; 83(2):188-96.
9. Madeira MC. Anatomia da face: Bases anátomo-funcionais para a prática odontológica. São Paulo : Sarvier; 2003.
10. Pasler FA, Visser H. Radiologia odontológica: procedimentos ilustrados. Porto Alegre : ARTMED; 2001.
11. Philips JL, Weller N, Kulid JC. The mental foramen: Part I. Radiographic position in relation to the mandibular second premolar. *J Endod.* 1992; 18(6):271-4.
12. Reiskin AB. Implant Imaging: Status, Controversies, and New Developments. *Dent Clin North Am.* 1998; 42(1):47-57.
13. Stramotas S. Accuracy of linear and angular measurements on panoramic radiographs taken at various positions in vitro. *Eur J Orthod.* 2002; 24(1):43-52.
14. Tronje G, et al. Horizontal and Vertical magnification. *Dentomaxillofac Radiol; Supply* 8, 1985.
15. Tronje G. Image distortion in rotational panoramic radiography. *Tandlakartidningen.* 1983 Feb; 75(3):88-9, 91.

Recebido em: 20/09/05
Aprovado em: 15/05/2006

Luiz Cesar de Moraes
moraes@fosjc.unesp.br
Disciplina de Radiologia
Faculdade de Odontologia de São José dos Campos
FOSJC – UNESP – Tel(12)3947-9055 – Fax(12)3947-9010
Av. Eng. Francisco José Longo – 777 – S. Dimas
São José dos Campos – SP – Brasil
12245-000