

Evaluation of optical density of rats tibiae bone repair treated with rofecoxib. Pilot study

Avaliação da densidade óptica do reparo ósseo de tíbias de ratos tratados com rofecoxib. Estudo Piloto

Gabriela Alessandra da CRUZ

Post-Graduated Student of the Department of Surgery, Periodontology and Radiology - School of Dentistry of São José dos Campos – UNESP – São Paulo State University – São José dos Campos – SP – Brazil

Mari Eli Leonelli de MORAES

Luiz César de MORAES

Professors of the Department of Surgery, Periodontology and Radiology - School of Dentistry of São José dos Campos – UNESP – São Paulo State University – São José dos Campos – SP – Brazil

Rosilene Fernandes da ROCHA

Professor of the Department of Biosciences and Oral Diagnosis - School of Dentistry of São José dos Campos – UNESP – São Paulo State University – São José dos Campos – SP – Brazil

Ivan BALDUCCI

Professor of the Department of Bioestatistic - School of Dentistry of São José dos Campos – UNESP – São Paulo State University – São José dos Campos – SP – Brazil

ABSTRACT

The aim of this study was to evaluate the influence of rofecoxib on bone repair process in tibiae of rats by means of analysis of gray levels acquired by digital optical density. Ten *Wistar* rats were assigned to two groups: an untreated control group and a group treated with rofecoxib. The experimental procedures comprised the following stages: general anesthesia, preparation of unicortical bone defect on the left tibiae of each rat, medication with rofecoxib and radiographic examination. Digital radiographic images were taken using Visualix GX-S-HDI™ digital sensor, an X-ray equipment. Radiographics were taken at baseline, 7, 14, 21 and 30 days postoperatively and the gray levels were evaluated using the Vix win™ 1.4 system of the region of interest (ROI). The mean values of ROI readings were analyzed statistically by repeated measures ANOVA with significance level of 5%. There were no statistically significant differences among gray levels between rofecoxib and control groups ($p=0.2429$), but there were statistically significant differences between times baseline, 7, 14, 21 and 30 in both groups ($p=0001$). The findings of this study suggest that no influence was found when rofecoxib was used in bone tibiae repair after 30 days post-treatment.

UNITERMS

Radiography; rats; wound healing.

INTRODUCTION

The nonsteroidal anti-inflammatory drugs (NSAIDs) continue to be a mainstay of therapy for patients with chronic pain and inflammation. The NSAIDs are competitive inhibitor of cicloxygenase

enzyme (COX) that had two forms, called COX-1 and COX-2. COX-1 are responsible to mediate the synthesis of prostaglandins responsible for protection of the stomach lining, while COX-2 mediate the synthesis of prostaglandins responsible for pain and inflammation. Some medications are created to be “selective”

NSAIDs that inhibit only COX-2, but not COX-1, scientists hypothesized they could offer the same pain relief as traditional NSAIDs, but with greatly reduced risk of fatal or debilitating peptic ulcers^{9, 12, 14}.

The nonsteroidal anti-inflammatory drugs have been investigated to influence the process of bone repair. Martins *et al.*¹⁰ suggested that Ketophofen influenced bone repair process by observing delayed new bone formation after 21 days and de Lima *et al.*⁵ associated the intake of NAIDs with bone repair process and have demonstrated that bone is one of the few tissues with remodeling capacity, being able to recover its structure and function after a trauma.

Digital radiographs allow evaluating radiographic bone repair analyzing the regions of interest (ROI) by using the scale of gray levels that correspond to the optical density of regions. The direct digital radiographs can be acquired utilizing CCD system (Charge Couple Device) that uses a silicio chip to capture the images that can be manipulated using a software that assist in image visualization which can improve the diagnostic accuracy^{15, 8, 4}.

Based on these considerations, the purpose of this study was to evaluate the influence of rofecoxib, a selective COX-2 inhibitor (cyclooxygenase-2 inhibitors), on the bone repair of unicortical defects created in tibiae of rats by analysis of the digital optical density (OD) at different periods of time.

MATERIAL AND METHODS

Ten adult male rats from the same line (*Rattus norvegicus albinus*, Wistar) aged 120 days and weighing from 350 to 400g were obtained from the animal laboratory of the Faculty of Dentistry of São José dos

Campos (UNESP). The animals were housed in proper cages and environment and were maintained on laboratory chow (Labina) and water *ad libitum*. The study protocol was approved (protocol number, 031/2003) by the Ethical Committee of Research of the School of Dentistry of São José dos Campos- UNESP.

The animals were anesthetized with 2% aqueous solution of 2-(2,6-xylidine)-5,6-dihydro-4H-1,3-thiazine hydrochloride (Rompum; Bayer do Brasil SA, São Paulo, SP, Brazil) and Ketamine (Francotar; Virbac do Brasil Ind. Com Ltda, São Paulo, SP, Brazil) at 1:0.5 ml ratio dose of 0.1ml/100mg. The rats were previously weighed to confirm the correct dose to be administered. Hypodermic insulin syringes with intradermal needles were used.

The skin over the left tibiae was shaved and antiseptis was performed with iodized alcohol made on the proximal area of the tibiae with an interchangeable #5 blade mounted on a Bard-Parker handle and a #7 spatula was used to retract the soft tissues and periosteum. A perforation was made on the bone with a 3mm diameter trephine bur coupled to an electric engine (Kavo do Brasil SA, Joinville, SC, Brazil) at 1,100 rpm speed and under constant irrigation with saline (Fig 1A and B). Skin was sutured with silk suture number 4 (Ethicon-Johnson & Johnson, Somerville, NJ, USA) and antiseptis was done with iodized alcohol.

Five animals were medicated with rofecoxib (Viox 12,5 mg - Merck & Co., Inc., Whitehouse Station, NJ, USA) at a dose of 12,5 mg/day for 30 days and 5 animals were not medicated (control).

For the radiographic examinations, the rats in the control and rofecoxib groups were initially submitted to general anesthesia by application of the same anesthetics, syringes and needles used for surgery,

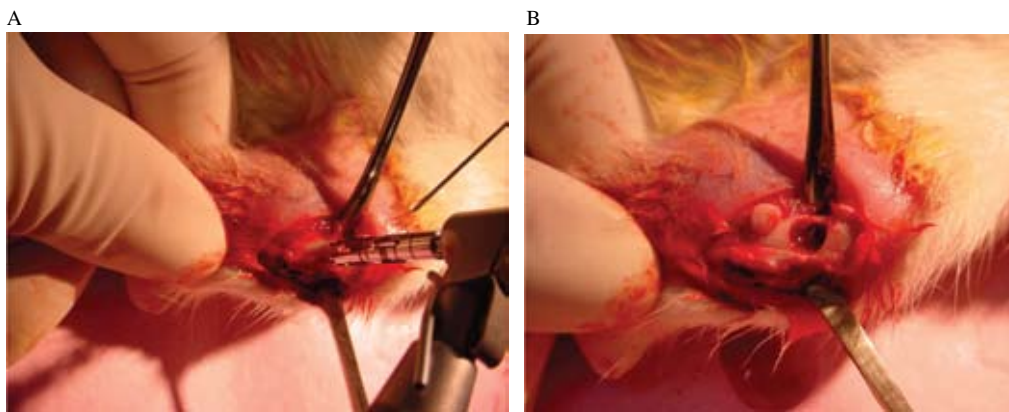


Figure 1 – A. Perforation being made on rat left tibiae; B. Unicortical bone defect.

although the anesthetic dose in this stage range from 0.08 to 0.1ml. Thereafter, each rat was positioned in dorsal recumbency on a supporting table. Before the baseline direct digital radiographs were obtained, an impression was taken from the left tibiae with low fusion impression compound (Godibar; Lysanda Produtos Odontológicos, SP, Brazil), in a way that the initial position could be reproduced in the further stages. Impression was taken on the lower portion of an individual metallic clamping device shaped as a rectangular box, with 3 free ends and a groove for fixation on the supporting table (Fig.2). Visualix GX-S-HDI™ digital sensor (Gendex Dental System, Dentisply International, Chicago, IL, USA) was placed on the lower portion (free impression material) of each device. Because it is a CCD (Charge-Couple Device) sensor, the image could be immediately transmitted to a computer screen. Thereafter, the tibiae was introduced in the clamping device, positioned on upper portion of the sensor and fixed to the device and impression mould with #9 utility wax (Epoxiglass Ind. Com. De Produtos Quimicos Ltda, Diadema, SP, Brazil). In this way, the bone defect was also turned upwards and the initial position could be reproduced in all evaluation periods (Fig.2.). Afterwards, the left tibiae of each rat was radiographed with an X-ray equipment (Spectro-70X™; Dabi Atlante, São Paulo, SP, Brazil) at 10mA and 65kVp; with 0.10 s exposure time and 25cm focus-object distance (Fig.2). Radiographs were taken from rats in both groups at baseline and 7, 14, 21 and 30days after unicortical bone defects were created on the left tibiae of the animals.

Optical density was evaluated using Vix win™ 1.4 system (Gendex Dental System) and are expressed by

gray levels. The gray levels were analyzed statistically by repeated measures – Analysis of Variance – ANOVA and Tukey test (Statitix for windows (version 8.0, 2003, Analytical Software Inc. Tallahassee, Florida, USA) at 5% significance level. Statistical assumptions were evaluated before statistical analysis. The results indicated that the residuals were normally distribute and, by plotting against predicted values, the uniformity was checked, then none of the ANOVA assumptions were violated.

RESULTS

Repeated measures ANOVA showed no significant differences between control and rofecoxib groups ($p=0.2429$), and interactions between treatment and periods (0.5678), while there were statistically significance differences ($p=0.001$) among the elevation periods to optical density expressed by the gray levels (Table 1). The Tukey test revealed that the rofecoxib and control groups presented the height levels of gray in 7 days, after which, the values decreased until the 30th day (Table.2).

DISCUSSION

This study evaluated the tibiae bone repair of rats treated with rofecoxib, a selective COX-2 inhibitor, and control groups using direct digital radiographic techniques evaluations of tibiae bone repair. The findings of the present study show that NSAIDs did not interfere with bone remodeling process in NSAIDs groups after 30 days.

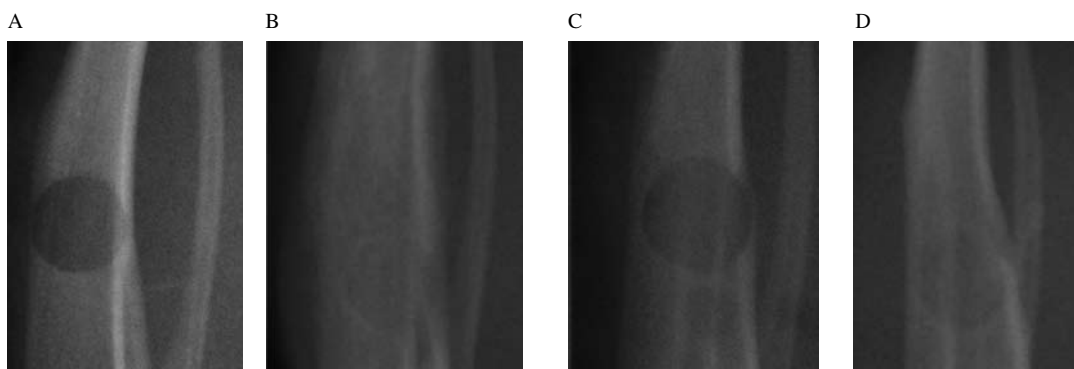


Figure 2 – Radiograph examinations of groups. A. Baseline rofecoxib; B. 30 days rofecoxib; C. Baseline control; D. 30 days control.

Table 1 – Description of repeated measured ANOVA for Gray of level (%).

Source	df	SS	MS	F	p-value
Treatment	1	309.1	309.06	1.59	0.2429
Residue I	8	1555.6	194.46		
Period	4	36516.3	9129.08	63.27	0.0001*
Interaction	4	430.6	107.65	0.75	0.5678
Residue II	32	4617.1	144.28		
Total	49	4328.7			

* Statistically significant differences were noticed between periods $p < 0.05$.

Table 2 – Means and standard deviations of gray levels (%).

Periods (days)	Means (%)	SD
Baseline	104.62 b	12.71
7	160.08 a	14.57
14	98.88 b	8.69
21	81.31 c	16.64
30	96.50b c	6.48

* Different superscript letter mean statistical difference founded by Tukey test ($\alpha = 0.05$)

The NSAIDs were selected to this study because they were prescribed for the treatment of various conditions that require analgesia and anti-inflammatory activity. People also have access to NSAIDs for relief mild aches, pain, and headaches. The NSAIDs are specific inhibitors for COX-2 and inhibited while sparing the activity of COX-1. NSAIDs were available (celecoxib, rofecoxib, valdecoxib (in order of US market release), however rofecoxib was withdrawn from the market in September 2004 due to clinical responses. White¹⁴ and Kondro *et al.*⁷ report that rofecoxib doubled the risk of heart attack or stroke if it was taken for longer than 18 months. The risk was thought to be due to blood clots. Even though, others COX-2 inhibitors have still been commercially available on the market^{13, 14}.

Clinical studies have been conducted not only to analyze vascular injuries but also the effect of NSAIDs on bone repair. de Lima *et al.*⁵ suggested that these drugs have a potential to stimulate bone healing. Although Allen *et al.*² Yazdi *et al.*¹⁶, Altman *et al.*¹ and Ho *et al.*⁶ have reported that NSAIDs may inhibit bone repair depending on type of drug, period of intake and dosage administered. An human study conducted by Brägger *et al.*³ showed that no influence on bone repair was observed in human with periodontal disease treated with NSAIDs. The findings of the present study did not show differences between bone remodeling process among the two groups analyzed after 30 days.

Other aspect of these evaluations was the use of digital radiographs to evaluated bone repair. Digital radiographic images were acquired using Visualix GX- HDI™ digital sensor. This CCD (Charge couple device) is composed by a silicio sensor smaller than the conventional periapical film that has bidimensional

transistor arrangements. Each arrangement corresponds to a pixel, which represents the smallest image formation unit responsible for radiographic contrast (each pixel can vary in a scale from 250 shades of gray), and the set of lines and columns corresponds to the digital matrix of the photon receptor. The great advantage in utilizing this system was that it allows image manipulation, great detail richness in addition to the possibility of optical density evaluation and measurement^{4, 11, 15}.

Martins *et al.*¹⁰ used the digital radiographic method to evaluate the bone density gain of rats' tibiae – like our study – that had Ketoprofen administrated for 30 days compared to control group. Although the authors' results found difference in optical density repair after 21 days, our study could not find the same results when rofecoxib was administrated. However, both studies agree that the evaluation method of optical density was efficient in detecting changes during the studied evaluation periods.

The results of the present study must be analyzed with caution, since they regard a pilot study with a medication already withdrawn from the market, however different NSAIDs that inhibit COX-2 are still available in the market. Therefore, we suggest that other studies are conducted with different medication that present the same action mechanism which can influence bone tissue repair response in order to observe weather the results are maintained with a lager number of subjects and longer evaluation time.

CONCLUSION

Within the limits of this study these findings indicate no influence of rofecoxib on bone repair process when it was administered until the 30th day.

RESUMO

O objetivo deste estudo foi avaliar a influência do rofecoxib sobre o processo de cicatrização de tíbias de ratos, por meio de análise da densidade óptica expressa em tons de cinza. Dez ratos da linhagem Wister foram divididos em dois grupos: um grupo controle (sem tratamento) e um grupo teste tratado com rofecoxib. Os procedimentos experimentais consistiram de: anestesia, cirurgia, administração do rofecoxib e exame radiográfico. As imagens radiográficas foram obtidas empregando o sensor Visualix GX-S-HDI™ e um aparelho de raios X. As radiografias foram realizadas nos períodos inicial, 7, 14, 21 e 30 dias pós operatório, sendo a densidade óptica avaliada de acordo com os tons de cinza por meio do sistema Vix win™ 1.4. Os valores médios da leitura de tons de cinza obtidos foram analisados estatisticamente por meio de ANOVA de medidas repetidas com nível de significância de 5%. Não houve diferença estatística significativa entre os grupos teste para os tons de cinza avaliados ($p=0.2429$), mas houve diferença estatística significativa entre os períodos avaliados *baseline*, 7, 14, 21 e 30 dias em ambos os grupos ($p=0001$). Os achados deste estudo sugerem que não houve influência do rofecoxib no reparo ósseo de tíbias de ratos após 30 dias tratamento.

UNITERMOS

Radiografia; ratos; cicatrização de feridas.

REFERÊNCIAS

- Altman RD, Latta LL, Keer R, Renfree K, Hornicek FJ, Banovac K. Effect of nonsteroidal anti-inflammatory drugs on fracture healing: a laboratory study in rats. *J Orthop Trauma* 1995;9(5):392-400.
- Allen HL, Wase A, Bear WT. Indomethain and aspirin effect of non-steroidal anti-inflammatory agents on the rate of fracture repair in the rat. *Acta Orthop Scand* 1980; 51:595-600.
- Brägger U, Muhle T, Fourmoussis I, Lang NP, Mombelli A. Effect of the NSAID flurbiprofen on remodeling after periodontal surgery. *J Periodontol Res* 1997;32:575-82.
- Cruz GA, Medici-Filho E, Castilho JCM, Moraes LC. Utilização de radiografia digital em odontologia. *ABO Nacional* 2004;367-9.
- de Lima V, Bezerra MM, de Menezes Alencar VB, Vidal FD, da Rocha FA, de Castro Brito GA, et al Effects of chlorpromazine on alveolar bone loss in experimental periodontal disease in rats. *Eur J Oral Sci* 2000;108:123-9.
- Ho MK, Chang JK, Chuang LY, Hsu HK, Wang GJ. Effects of non-steroidal anti-inflammatory drugs and prostaglandins on osteoblastic functions. *Biochem Pharmacol* 1999;58:983-90.
- Kondro W. Lawsuits mount in wake of rofecoxib (Vioxx) withdrawal. *CMAJ* 2004;171:1335.
- Kullenforff B, Nilsson M, Rohlin M. Diagnostic accuracy of direct digital dental radiography for the detection of periapical bone lesions. *Oral Surg Oral Med Oral Pathol Oral Radiol Endod* 1996 Sep;82(3):344-50.
- Langman MJ, Jensen DM, Watson DJ, Harper SE, Zhao P, Quan H, et al. Adverse upper gastrointestinal effects of rofecoxib compared with NSAIDs. *JAMA* 1999 Nov;282(20):1929-33.
- Martins MV, Silva MAS, Medici-Filho E, Moraes LC, Castilho JCM, Rocha RF. Evaluation of digital optical density of bone repair in rats medicated with Ketoprofen. *Braz Dent Journal* 2005 ;16(3):207-12.
- Molteni R. Direct digital dental x-ray imaging with Visualix/ VIXA. *Oral Surg Oral Med Oral Pathol* 1993 Aug;76(2):235-43.
- Peretz A. Cox-2 inhibitor non-steroidal anti-inflammatory drugs, myth or reality? *Rev Med Brux* 2001;22:377-80.
- Tiseo BC, Namur GN, de Paula E JL, Matar Junior R, Oliveira CRGCM. Experimental study of the action of COX-2 selective nonsteroidal anti-inflammatory drugs and traditional anti-inflammatory drug in bone regeneration. *Clinics* 2006;61(3):223-30.
- White PF. Changing role of cox-2 inhibitors in the preoperative period: Is Parecoxib really answers? *Anesth Analg* 2005;100:1306-8.
- Wenzel A, Hintze H. Perception of image quality in direct digital radiography after application of various image treatments filters for detectability of dental disease. *Dentomaxillofac Radiol* 1993;22:131-4.
- Yazdi M, Cheung DT, Cobbe S, Nimmi ME, Sconfeld SE. Effect of non-steroidal anti-inflammatory drugs on demineralized bone-induced bone formation. *J Periodontal Research* 1992;27:28-33.

Recebido em 20/12/07

Aprovado em 06/05/08

Correspondence:

Gabriela Alessandra da Cruz,

Avenida Francisco José Longo, 777, Caixa Postal 314,

CEP 12455-000

São José dos Campos –SP - Brasil.

e-mail: gaby.3003@hotmail.com