



CASE REPORT

Unilateral Gingival Fibromatosis: a case report

Fibromatose Gengival Unilateral: um relato de caso

Cleverson PATUSSI, Caroline Beatrice RAMOS¹, Laurindo Moacir SASSI¹, Paola Andréia G. PEDRUZZI², Gyl Henrique Albrecht RAMOS²

1 – Department of Oral and Maxillofacial Surgery – Erasto Gaertner Hospital – Curitiba/PR – Brazil.

2 – Department Head and Neck Surgery – ErastoGaertner Hospital – Curitiba/PR – Brazil.

ABSTRACT

The gingival fibromatosis is a slow and progressive benign proliferation, which affects the gingival tissues. It may present a genetic inheritance and association with some syndromes. There are conservative and radical treatments, ranging from hygiene care to bloc resection of the affected bone. This case scenario is a 07 year-old child, who presented a nodular unilateral hyperplastic lesion in the right mandible, with sessile base and approximately 5 cm in its largest diameter. The patient presented difficulty of lip closure and slight swelling in the right area of the face. The tomographic image showed infiltration in buccal and lingual cortical of right mandible and tooth displacement. After lesion removal, the histopathologic diagnosis of fibromatosis was confirmed, with no relapse after 20 months of follow-up.

KEYWORDS

Gingival hyperplasia; Aggressive fibromatosis; Gingival fibromatosis.

RESUMO

A Fibromatose Gengival é uma proliferação benigna, lenta e progressiva, que afeta os tecidos gengivais. Pode apresentar herança genética e associação à uma série de síndromes. Existem tratamentos conservadores e radicais, desde cuidados com higiene à ressecção em bloco do tecido ósseo afetado. Este é o caso clínico de uma criança, que apresentou lesão hiperplásica unilateral em mandíbula, com deslocamento dentário. Após remoção, o diagnóstico de hiperplasia gengival foi confirmado e não há recidiva da lesão até o momento.

PALAVRAS-CHAVE

Hiperplasia gengival; Fibromatose agressiva; Fibromatose gengival.

INTRODUCTION

Hereditary gingival fibromatosis is a rare disorder characterized by fibrous growth proliferation of the gingival tissue, which may occur as a primary disease or as part of a syndrome or chromosomal abnormalities [1]. This disease is a slow progressive benign proliferation that affects the marginal gingiva, attached gingiva and interdental papillae. It may cover the surfaces of an erupted teeth, causing aesthetic and functional problems, which, in extreme cases, may cause some mandible and maxilla deformities [2].

The gingival hyperplasia usually presents normal mucosa coloration and firm consistency.

The gingival growth usually coincides with the eruption of a permanent tooth, although it may occur during the eruption of primary teeth or, rarely, at birth [2,3].

Some clinical abnormalities may be commonly associated with gingival fibromatosis such as Hirsutism, Epilepsy, Oligophrenia, Mental Retardation, Nystagmus, Strabismus, Cataract, soft tissue tumors, and increased facial bones [4]. It may present as a dominant or recessive autosomal inherence or may be associated with a series of syndromes such as: Zimmerman-Laband (ZLS), Jones, Rutherford Ramon Syndrome, Juvenile Hyaline

Fibromatosis, Infantile Systemic Hyalinosis and Mannosidosis [5]. Dominant autosomal forms of Hereditary Gingival Fibromatosis, usually non-syndromic, were related to 2p21-P222 and 5q13-q22 chromosomes [6].

The treatment for this kind of injury is directly linked to its presentation and also to patient general condition. Literature describes since conservative treatments, as oral hygiene instruction and prophylaxis, until gengivectomy and block resection of the affected area. It is up to the attending surgeon to decide the appropriate approach, based on those data [7].

CASE REPORT

A female patient, 6 years of age, was seen at the Hospital Erasto Gaertner Head and Neck service; with main complain of progressive swelling on the right side of mandible.

An extraoral inspection detected swelling in the lower third of the right side of the face and difficulty in lips closure. A nodular, sessile based, mixed erythematous and normal mucous color lesion, with approximately 5 cm in its largest diameter, was found in the intraoral inspection. The lesion extended from anterior to retromolar right mandible, surpassing the occlusal plane, which justified the difficulty of lip closure and the imprint of upper teeth on surface of the lesion.

Radiographs and a computed tomography (CT) were requested. The radiographs showed displacement of teeth 84, 85 and 46 (the first two in infraocclusion and the third one distalized), with no bone involvement or alteration. In the CT analysis, however, some buccal and lingual cortical infiltrations were visible, with maintenance the mandibular inferior cortical intact.

The tumor excision was performed under general anesthesia, with an 1 cm margin on the buccal and lingual alveolar mucosae. Intralesional deciduous teeth extraction and marginal osteotomy were made. Despite the

small risk of local recurrence, the involved permanent tooth was preserved.

The lesion was sent for pathological analysis that confirmed the initial diagnosis of fibromatosis with the following description: spindle cell lesion composed of multidirectional elongated cells uniforms bundles, minimal pleomorphism and low mitotic index. Dense fibro-connective tissue, slightly vascularized, with sparse chronic inflammatory infiltrate and elongated fibroblasts still can be identified.

The patient is on follow up for approximately 20 months after surgery, with no signs of recurrence until this date.

DISCUSSION

Hereditary gingival fibromatosis presents a slow and progressive growth, caused by the increased of collagen production in the lamina propria of gingiva. Many researchers believe that the presence of teeth is a pre-condition for its occurrence. This gingival hypertrophy can cover erupting teeth and prevent the its visualization, even after its complete eruption, interfering with teeth function and lip sealing. Some displaced and/or intralesional teeth are often seen [8], as in the described in the present scenario.

The characteristic gingival growth of this disease may be associated with one or more teeth, involving one or more quadrants, or it may be generalized, depending on the lesion genetic expression and, also, its association with other diseases or syndromes. One interesting and unusual aspect in this case was the unilateral development of the lesion, in one quadrant only, that seems to be a less common presentation, according to literature [7,8].

Histopathologically, the fibromatosis shows a bulbous increase of connective tissue, which is relatively avascular and has collagen fiber bundles densely arranged, numerous fibroblasts and some chronic inflammatory cells. The epithelium is thick and acanthotic, with elongated straight grooves [6]. The injury

presented by the patient is in accordance with the histological description above, presenting dense connective fibrous tissue, slightly vascularized, sparse chronic inflammatory infiltrate and elongated fibroblasts.

Various treatments can be performed according to the degree of severity of injury and combination or not with other diseases or syndromes. When the growth is minimal, good instructions and hygiene may be sufficient to maintain oral health. Great gingival growth, however, requires surgical correction, considering the impact on function and aesthetics. Some techniques can be used for removing the gums growth, including: internal or external bevel gingivectomy, gingivoplasty, apical graft repositioning, electrocautery and carbon dioxide laser [7,9]. The periodontal grafting can be used in large areas affected by gingival hypertrophy when there are insertion loss and/or bone defects. The etiological factors removal, as plaque or calculus, near lesions, is necessary [10].

The extraction of teeth within the lesion occurs frequently. The lesion growth and displacement of tooth to an ectopic region cause destruction and periodontal components loss. Whenever possible, treatment should be performed after complete eruption of permanent teeth, since the eruptive system is fragile, seeking, thereby, to cause the least surgical sequel possible to periodontal tissues of young patients [11].

Patient rehabilitation is necessary when they suffered teeth and/or bone loss, either by surgical techniques or by the lesion growth cause. This is justified because this disease does not present, in general, long-term recurrence or malignant transformation. The 20 months after treatment follow up is sufficient for recurrence evaluation [11]. In this case, despite the removal of deciduous elements within the lesion, there was no need for prosthetic rehabilitation of any kind. There was no damage to remaining teeth

or permanent tooth germs, which continued to develop without interference.

This patient remains with no signs of recurrence and has been monitored for more than 20 months.

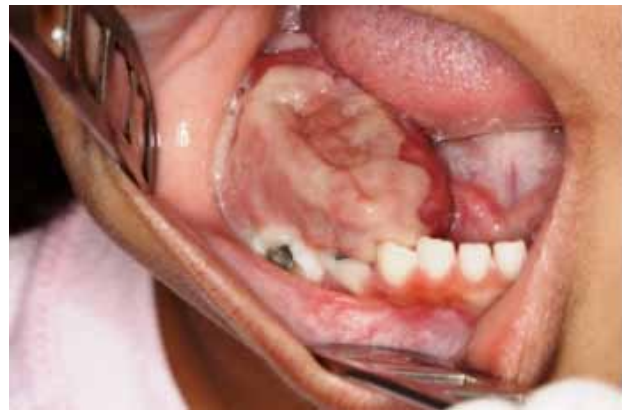

Figure 1- Nodular sessile base lesion, approximately 5 cm in its largest diameter, imprinting of upper teeth on the lesion surface.

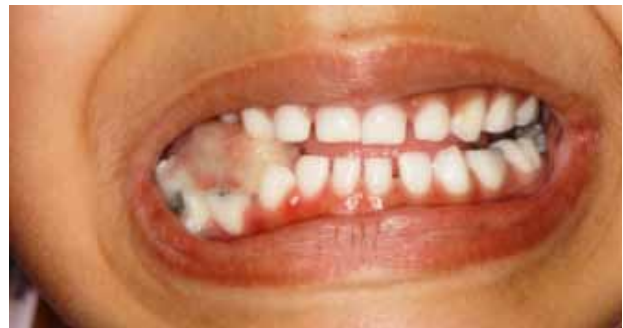

Figure 2 - Note the displacement of teeth 84, 85 and 46, and the patient difficulty of occluding properly because of tumor volume.

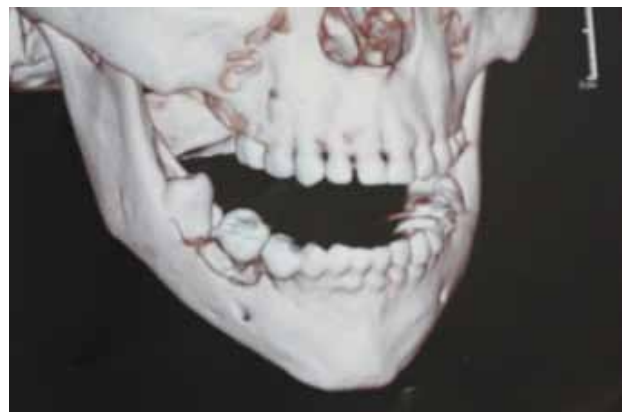

Figure 3- CT revealed infiltration on right buccal and lingual mandibular cortical. The inferior cortical remains intact.

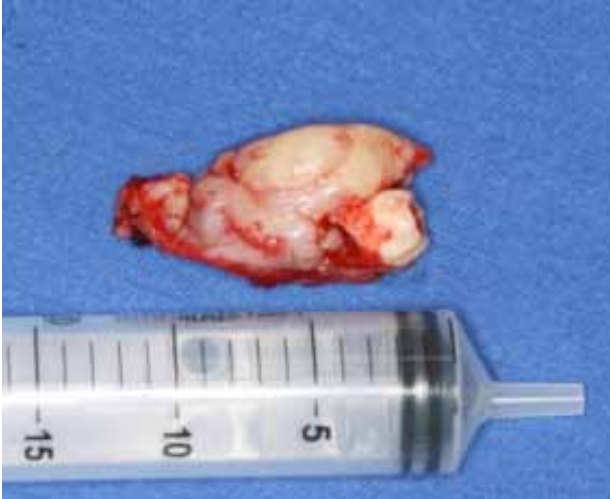

Figure 4 - Lesion and intralésional deciduous teeth, after removal.

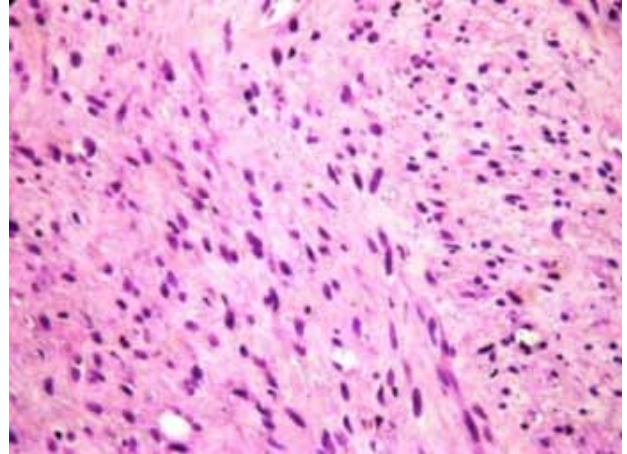


Figure 5 - This lesion image confirms the initial diagnosis of fibromatosis: dense fibro-connective tissue, slightly vascularized, sparse chronic inflammatory infiltrate and elongated fibroblasts.

REFERENCES

1. Yaprak E, Subaşı Mg, Avunduk M, Aykent F. Amelogenesis Imperfecta and Generalized Gingival Overgrowth Resembling Hereditary Gingival Fibromatosis in Siblings: a case report. *Case Reports in Dentistry*. 2012; 2012:1-6.
2. Chaturvedi R. Idiopathic Gingival Fibromatosis Associated with Generalized Aggressive Periodontitis: a Case Report. *J Can Dent Assoc*. 2009;75(4):291-5.
3. Ramakrishnan T, Kaur M. Multispecialty approach in the management of patient with hereditary gingival fibromatosis: 1-Year Follow up: a Case Report. *Int J Dent*;2010;2010:1-5.
4. Sharma S, Goyal D, Shah G, Ray A. Familial gingival fibromatosis: a rare case report. *Contemp Clin Dent*. 2012; 3(1):S63-6.
5. Martelli Jr H, Lemos DP, Silva CO, Graner E, Coletta RD. Hereditary gingival fibromatosis: report of a five generation family using cellular proliferation analysis. *J Periodontol*. 2005;76(12):2299-305.
6. Jaju PP, Desai A, Desai RS, Jaju SP. Idiopathic Gingival Fibromatosis: Case Report and Its Management. *Int J Dent*. 2009;2009:1-6.
7. Bansal A, Narang S, Sowmya K, Sehgal N. Treatment and two-year follow-up of a patient with hereditary gingival fibromatosis. *J Indian Soc Periodontol*. 2011; 15(4):406–9.
8. Sandhu PS, Kakar V, Gogia G, Narula SC. Unilateral gingival fibromatosis with localized aggressive periodontitis (involving first molars): An unusual case report. *J Indian Soc Periodontol*. 2009;13(2):109-113.
9. Reddy MS, Manyam R, Babu MN, Sarawathi TR. Gingival fibromatosis with hemi-osseous hyperplasia of jaws, focal maxillary viral papillomatosis. *Indian J Dent Res*. 2011;22(3):489-92.
10. Newman MG, Takei HH, Klokkevold PR, Carranza FA. 10th ed. *Clinical Periodontology*. St. Louis, Missouri: Saunders; 2006. p. 379–380.
11. Baptista IP. Hereditary gingival fibromatosis: a case report. *J Clin Periodontol*. 2002;29:871–4.

Dr. Laurindo Moacir Sassi (Corresponding address)

Hospital Erasto Gaertner - Serviço de Cirurgia
e Traumatologia Bucocomaxilofacial
R. Dr. Ovande do Amaral, 201 - Jardim das Américas
ZIP 81.520-060 - Curitiba/PR
Telefone: (41) 3361-5000

Date submitted: 2013 Jul 30

Accept submission: 2013 Oct 21